



HAL
open science

Surgical ciliated cysts of the mandible: A systematic review of case reports

Mathieu Brisset, Clément Cambronne, Mélanie Ferrer, Sarah Cousty, Antoine Dubuc

► **To cite this version:**

Mathieu Brisset, Clément Cambronne, Mélanie Ferrer, Sarah Cousty, Antoine Dubuc. Surgical ciliated cysts of the mandible: A systematic review of case reports. *Oral Diseases*, 2024, 30 (5), pp.2858-2864. 10.1111/odi.14795 . hal-04832913

HAL Id: hal-04832913

<https://ut3-toulouseinp.hal.science/hal-04832913v1>

Submitted on 12 Dec 2024



HAL is a multi-disciplinary open access archive for the deposit and dissemination of scientific research documents, whether they are published or not. The documents may come from teaching and research institutions in France or abroad, or from public or private research centers.

L'archive ouverte pluridisciplinaire **HAL**, est destinée au dépôt et à la diffusion de documents scientifiques de niveau recherche, publiés ou non, émanant des établissements d'enseignement et de recherche français ou étrangers, des laboratoires publics ou privés.



Distributed under a Creative Commons Attribution - NonCommercial 4.0 International License

Surgical ciliated cysts of the mandible: A systematic review of case reports

Mathieu Brisset^{1,2}  | Clément Cambronne^{1,2} | Mélanie Ferrer^{1,2} | Sarah Cousty^{1,2,3} | Antoine Dubuc^{1,2,4} 

¹School of Dental Medicine and CHU de Toulouse, Toulouse Institute of Oral Medicine and Oral Surgery, Toulouse, France

²Université Toulouse III – Paul Sabatier, Toulouse, France

³LAPLACE, UMR 5213 CNRS, Paul Sabatier University, Toulouse, France

⁴Centre for Epidemiology and Research in Population Health (CERPOP), UMR 1295, Paul Sabatier University, Toulouse, France

Correspondence

Mathieu Brisset and Antoine Dubuc, School of Dental Medicine and CHU de Toulouse-Toulouse Institute of Oral Medicine and Oral Surgery, Toulouse 31062, France.

Email: brisset.m@chu-toulouse.fr and dubuc.a@chu-toulouse.fr

Abstract

Background: Surgical ciliated cysts occur mainly in the maxillae after radical maxillary sinus surgery; they rarely develop in the mandible. This study aims to gather information on all the characteristics of patients suffering from mandibular surgical ciliated cysts. This article also reports two new cases.

Methods: PubMed, Google Scholar and the International Clinical Trials Registry Platform were explored until 13 December 2022 for articles regarding mandibular surgical ciliated cysts. Maxillary ciliated cysts were excluded.

Results: Fourteen original articles were included in a total of 16 cases. Maxillofacial surgeries are the first aetiology (94.4%). Surgical ciliated cysts of the mandibular region show a 1.25:1 male-to-female ratio with a protracted time to diagnosis (range: 2–56 years). Most patients are symptomatic (77.8%). Typically, radiology shows a radiolucency lesion (88.9%) and histology describes pseudostratified ciliated columnar epithelium. Enucleation has always been described as the treatment.

Discussion: All results were case reports, thus a low level of evidence studies. Mandibular surgical ciliated cysts should be considered in patients presenting a mandibular swelling or radiolucency lesion with a maxillofacial surgery history. Meticulous surgical techniques can aid in the prevention of this lesion.

KEYWORDS

genioplasty, mandibular, orthognathic surgery, postoperative maxillary cyst, surgical ciliated cyst

1 | INTRODUCTION

Postoperative maxillary cyst (Kaneshiro et al., 1981) was originally described by Kubo (“Kubo: A buccal cyst occurred after a radical operation... – Google Scholar,” 1927) in 1927, which is also known as surgical ciliated cyst (Miller et al., 1988), ectopic ciliated cyst, respiratory cyst or implantation cyst. The traditionally accepted

pathogenesis of surgical ciliated cysts involves entrapment of the nasal or maxillary sinus mucosa, a subsequent inciting inflammatory process, and progressively increased osmotic pressure. Together, these steps lead to cyst creation, expansion and enlargement. Classically associated with maxillary sinus surgeries (Gates et al., 2022), they have also been reported in association with orthognathic surgery (Hayhurst et al., 1993), bone graft (Nastri &

This is an open access article under the terms of the [Creative Commons Attribution-NonCommercial](https://creativecommons.org/licenses/by-nc/4.0/) License, which permits use, distribution and reproduction in any medium, provided the original work is properly cited and is not used for commercial purposes.

© 2023 The Authors. *Oral Diseases* published by Wiley Periodicals LLC.



Hookey, 1994), traumatic dental extraction ("Surgical ciliated cyst of the left maxilla – A case report of unusual pathogenesis – PMC," n.d.) and maxillofacial trauma (Soares et al., 2021). Publications detailed this event occurring most often as a sequelae of open maxillary sinus surgery (Gates et al., 2022). A surgical ciliated cyst is defined as a cystic lumen lined by pseudostratified ciliated columnar epithelium ("Gregory: Surgical ciliated cysts of the Maxilla:... – Google Scholar," 1958). Predominant clinical presenting features are buccal and facial swelling following maxillary sinus surgery (open maxillary sinus surgery and Caldwell-Luc type procedures). Nevertheless, it can be asymptomatic (Gates et al., 2022).

In 1994, Nastri and Hookey (1994) described for the first time a mandibular localization. Since then, 14 publications about mandibular surgical ciliated cysts have been published for a total of 16 cases (Anastassov & Lee, 1999; Bourgeois & Nelson, 2005; Cai et al., 2015; Drmeddent & Schwartz, 2001; Kelly et al., 2000; Koutlas et al., 2002; Lafuente-Ibáñez de Mendoza et al., 2021; Lazar et al., 2006; Li et al., 2014; Ragsdale et al., 2009; Seifi et al., 2016; Syed et al., 2018; Youn et al., 2022). This article reports the 17th and 18th cases of mandibular surgical ciliated cysts in twin sisters who underwent genioplasty with concomitant rhinoplasty 30 years earlier.

We are keen to provide an overview of articles about this rare localization. This systematic review aims to gather information on all the characteristics of patients suffering from mandibular surgical ciliated cysts.

2 | MATERIALS AND METHODS

A systematic review has been performed in December 2022 in accordance with the PRISMA 2020 guidelines (Table S2: PRISMA 2020 check list; Page et al., 2021). Case reports have been conducted in accordance with CARE guidelines (Riley et al., 2017).

In order to improve the quality of this systematic review, the quality of each case report was analysed according to the check list for case reports recommended by JBI Global (Aromataris & Munn, 2020; Murad et al., 2018). The results are available in the Table S3. The systematic review has not been registered.

2.1 | Eligibility criteria

All publications, written in English, Spanish and French, concerning patients with mandibular surgical ciliated cysts, were eligible for inclusion.

2.2 | Information sources

Internet requests were launched on 13 December 2022, in two different databases following recommendations (Gasparyan et al., 2011): PubMed and Google Scholar. Clinical trials were also

identified through the International Clinical Trials Registry Platform search portal (available at <http://apps.who.int/trialsearch/>). Citation searching has been performed as well.

2.3 | Research strategy

The databases advanced search systems and keywords were used to identify relevant articles (e.g., 'surgical ciliated cyst' or 'genioplasty'). Each website proposes a different research engine, requests have been adapted depending on the database on which they were initiated. All search strategies are available in Table S1.

2.4 | Study selection and data extraction

All results were screened based on titles and abstracts. Full texts of the potentially selected records were obtained for definitive inclusion (Figure S1). Data extraction was performed twice by two authors (MB and AD).

Articles were excluded according to the following reasons: if the article reported on an extra mandibular localization (maxillary or nasal); if there was redundant reporting of clinical cases; if abstract articles were not available; and if there was a conference proceeding.

2.5 | Inclusion criteria

All original publications dealing with mandibular surgical ciliated cysts were included whether they were systematic reviews, literature reviews, clinical trials, original research or case reports/series.

2.6 | Outcomes

The following outcomes were considered: countries of authors' affiliations, age and sex, type of surgery (rhinoplasty, genioplasty and osteotomy, etc.), type of graft, time between surgery and diagnosis, symptoms, localization, radiographic appearance, type of epithelium and treatment.

3 | RESULTS

A total of 3139 results were identified, corresponding to 3127 unique citations. Based on the inclusion criteria described above, 3102 were excluded. A final total of 14 articles were included, describing 16 cases. The main exclusion criteria were maxillary localization (35.9%). A flow diagram is available (Figure S1). This article adds two new cases to this systematic review. Details for each study are presented in Table 1.



TABLE 1 Cases of mandibular surgical ciliated cyst.

Author (year)	Country	Surgery	Age (years) /sex	Anatomopathology	Latency period (years)	Symptoms	Radiographic appearance	Treatment	Type of graft	Localization
Anastassov and Lee (1999)	USA	Rhinoplasty and septoplasty with chin augmentation	53/male	Ciliated pseudostratified	39	Swelling	Oval lesion with hypersclerotic borders	Enucleation and peripheral osteotomy	Nasal osteocartilaginous	Anterior mandible
Bourgeois and Nelson (2005)	USA	LefFort I osteotomy and sliding genioplasty	27/female	Ciliated pseudostratified	4	None	Radiolucency	Enucleation	None (same saw blade)	Anterior mandible
Cai et al. (2015)	China	LefFort I osteotomy and genioplasty	23/male	Ciliated pseudostratified	2	Swelling/Tenderness	Radiolucency	Enucleation and plate removed	Residual bone removed from a maxillary osteotomy	Anterior mandible
Drmeddent and Schwartz (2001)	USA	Rhinoplasty and chin augmentation	59/male	Ciliated pseudostratified	40	Swelling/Pus	Radiolucency	Enucleation	Nasal osteocartilaginous	Anterior mandible
Lafuente-Ibáñez de Mendoza et al. (2021)	Spain	Platelet-rich plasma and collagen membrane	50/male	Ciliated pseudostratified	2	None	Radiolucency	Enucleation	None	Posterior mandible
Lazar et al. (2006)	Germany	Rhinoplasty and chin augmentation	24/male	Cartilaginous wall, ciliated pseudostratified	6	Swelling/Pain	Radiolucency	Enucleation and osteo-plasty	Nasal osteocartilaginous	Anterior mandible
Li et al. (2014)	USA	Rhinoplasty and chin augmentation	72/male	Ciliated pseudostratified	56	Swelling	Radiolucency	Enucleation and bone graft with recombinant bone	Nasal osteocartilaginous	Anterior mandible
Ragsdale et al. (2009)	USA	LefFort I osteotomy, bilateral mandibular sagittal split osteotomy with interpositional bone grafts and genioplasty	42/male	Ciliated pseudostratified	18	Paraesthesia	Radiolucency	Enucleation	Bone	Right mandibula ramus
Seifi et al. (2016)	Iran	LefFort I osteotomy and genioplasty	30/male	Ciliated pseudostratified	16	Swelling/Pain/Pus	Radiolucency	Enucleation and bone graft with recombinant bone	Residual bone removed from a maxillary osteotomy	Anterior mandible
Youn et al. (2022)	Korea	Bimaxillary orthognathic surgery and sliding genioplasty	37/female	Ciliated pseudostratified	2	Mild inflammation	Unilocular radiolucency	Enucleation	Unknown	Anterior mandible
Kelly et al. (2000)	USA	Rhinoplasty and chin augmentation	42/male	Ciliated pseudostratified	24	No symptoms	Radiolucency	Enucleation, plates and screws removed	Residual tissue removed from a maxillary osteotomy	Anterior mandible
			56/female	Ciliated pseudostratified, dystrophic calcifications	40	Swelling/Pain	Homogeneous density of enlarged soft tissues	Enucleation	Nasal osteocartilaginous	Anterior mandible



TABLE 1 (Continued)

Author (year)	Country	Surgery	Age (years) /sex	Anatomopathology	Latency period (years)	Symptoms	Radiographic appearance	Treatment	Type of graft	Localization
Nastri and Hookey (1994)	Australia	Rhinoplasty and chin augmentation	33/female	Ciliated pseuodstratified	15	Swelling/Pain/ Ulceration	Radiolucency	Enucleation	Nasal osteocartilaginous	Anterior mandible
Koutlas et al. (2002)	USA	Bimaxillary orthognathic surgery	34/female	Ciliated pseuodstratified, collagenized connective tissue	13	Swelling/Fistula	Unknown	Enucleation	Residual tissue removed from a maxillary osteotomy	Anterior mandible
Syyed et al. (2018)	UK	LeFort I osteotomy and genioplasty LeFort I osteotomy and genioplasty	38/male 25/female	Ciliated Ciliated pseuodstratified	18 10	Pain Pain/Swelling	Radiolucency Radiolucency	Enucleation Enucleation	Unknown Unknown	Anterior mandible Anterior mandible
Current cases	France	Rhinoplasty and chin augmentation, bimaxillary orthognathic surgery (20years ago). Rhinoplasty and chin augmentation	48/female 48/female	Ciliated pseuodstratified, cartilaginous tissue Ciliated pseuodstratified, cartilaginous tissue	30 30	None Pain/Swelling	Radiolucency Radiolucency	Enucleation Enucleation	Nasal osteocartilaginous Nasal osteocartilaginous	Anterior mandible Anterior mandible

Since 1994, most published cases have come from the United States (50%). Maxillofacial surgeries are the first cause of mandibular surgical ciliated cysts (94.4%), with two major types of surgery. On one hand, concomitant genioplasty with rhinoplasty (nasal cartilaginous autograft) represents 44.4% of all aetiology. On the other hand, osteotomy with sliding genioplasty also represents 44.4% of all aetiology. One article reports a bimaxillary osteotomy surgery without genioplasty (Koutlas et al., 2002). Only one case was presented as unrelated to a major maxillofacial surgery (Lafuente-Ibáñez de Mendoza et al., 2021). Surgical ciliated cysts of the mandibular region show a 1.25:1 male-to-female ratio. The median total time to diagnosis is 17 years (range: 2–56 years). The latency period in our analysis was calculated as the interval from inciting traumatic events or surgery to diagnosis. The anterior mandibula is the first localization (88.9%). Most patients are symptomatic (77.8%), mainly swelling (61.1%) and pain (38.9%). Typically, radiology shows a radiolucency (88.9%) and histology predominantly shows a pseudostratified ciliated columnar epithelium (100%). The most common type of graft is a nasal osseocartilaginous graft (44.4%), but 3 (16.7%) articles did not specify the graft type. Enucleation has always been described as the treatment (100%).

4 | CASES PRESENTATION

In 2022, a Caucasian 48-year-old woman (patient A) was referred to the Department of Oral Surgery at the Toulouse University Dental Hospital for a mandibular cyst. After the realization of an orthopantomogram for orthodontic treatment, a cyst in the anterior mandible was found. CBCT revealed a radiolucent lesion with a diameter of $3 \times 1.5 \times 2.6$ cm in the lower anterior region (Figure 1). Nearly 30 years ago, patient A underwent concomitant genioplasty with a nasal cartilage autograft and rhinoplasty. And then a bimaxillary osteotomy 20 years ago. The patient had no other medical history and did not complain of other symptoms such as pain or swelling. However, patient A suffered from labio-mental dysesthesia, but only since she underwent a bimaxillary osteotomy. We chose to associate this symptom with bimaxillary osteotomy rather than genioplasty.

The patient's monozygotic twin sister (patient B) also underwent concomitant genioplasty with nasal cartilage autograft and rhinoplasty 30 years ago but did not undergo bimaxillary osteotomy surgery. They have been operated on by the same surgeon. Unlike her sister, patient B had repeated chin infections treated with antibiotics and analgesics. Symptoms were oedema and pain. The same radiolucent lesion was noticed. Despite her symptoms, a diagnosis has not been identified before patient A's.

While patient A was under local anaesthesia to enucleate the cyst. A full-thickness alveolar mucosal flap was conducted via an incision in the buccal side of the mandibular symphysis. The cyst, which was attached to the nasal bone graft by its anterior part, was dissected and enucleated. After resection, the specimen was sent to the Department of Anatomical Pathology. Sutures with absorbable

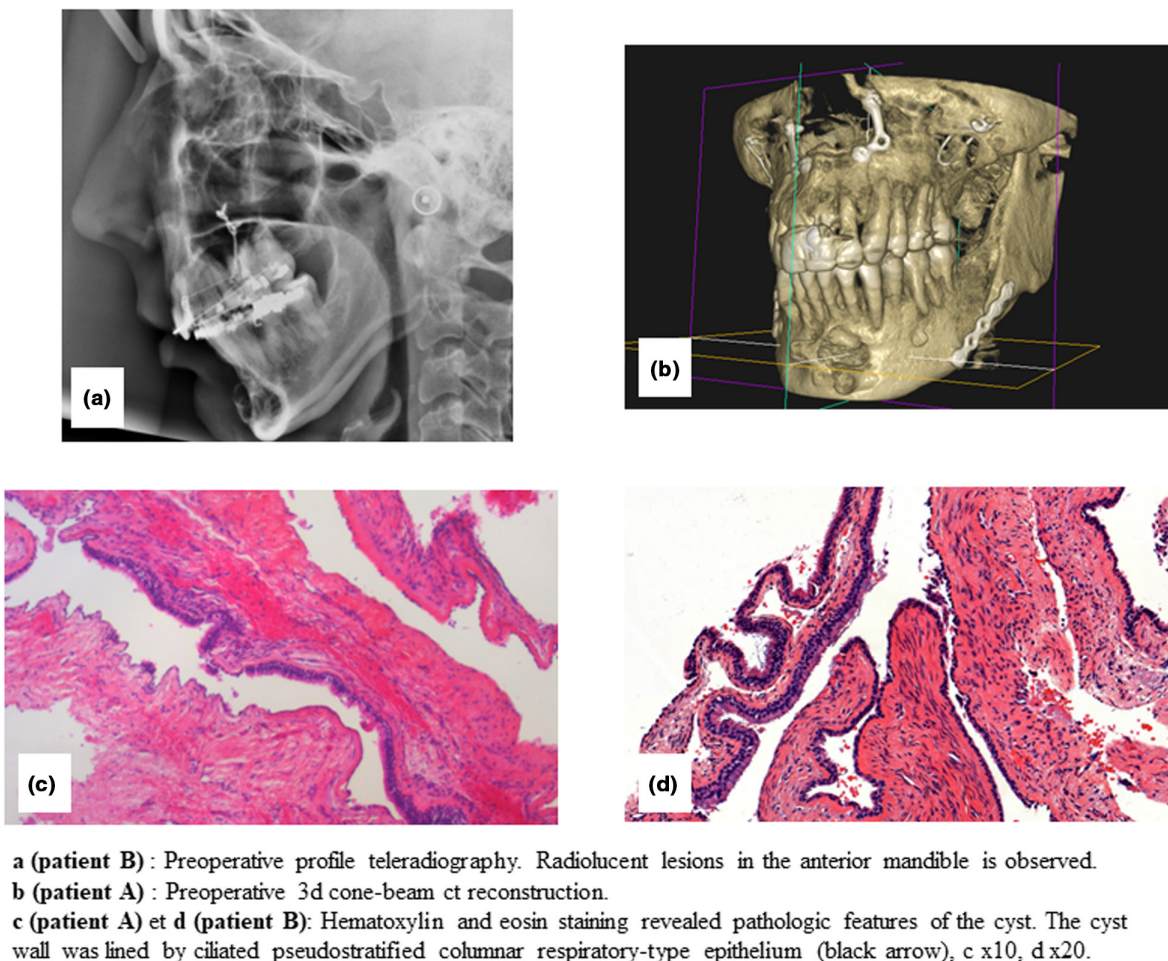


FIGURE 1 Preoperative CBCT and histopathological results.

thread were realized. Histopathological examination revealed that the cyst was lined inside with ciliated respiratory epithelia, and a surgical ciliated cyst was diagnosed (Figure 1). Cartilage was also found. The same surgical procedure was performed on patient B. The same histopathological result was obtained.

5 | DISCUSSION

This systematic review of the literature provides information about mandibular surgical ciliated cysts and summarizes the various clinical signs, location, treatment, age, sex, latency, type of graft, aetiology and radiographic appearance of this rare lesion. The United States is the country with the highest number of publications about mandibular surgical ciliated cysts. This could be explained by the fact that the United States is the first country ranked by a total number of aesthetic procedures (Global Survey 2021, 2021). According to the data collected, mandibular surgical ciliated cysts

are located mainly in the anterior part of the mandible, providing a cystic-looking radiographic image. This anterior location is due to the type of surgery itself. Since the population affected by this lesion has mostly a history of genioplasty, with two main procedures: genioplasty concomitant with rhinoplasty, based on the use of a nasal cartilaginous autograft, and genioplasty concomitant with maxillary osteotomy (Anastassov & Lee, 1999; Bourgeois & Nelson, 2005; Cai et al., 2015; Drmeddent & Schwartz, 2001; Kelly et al., 2000; Koutlas et al., 2002; Lazar et al., 2006; Li et al., 2014; Natri & Hookey, 1994; Ragsdale et al., 2009; Seifi et al., 2016; Syed et al., 2018; Youn et al., 2022). One article reports a ramus localization after a mandibular sagittal split osteotomy with concomitant maxillary osteotomy (Li et al., 2014). One case of surgical ciliated cysts has been described after teeth extraction and the use of a collagen membrane and platelet-rich plasma (Lafuente-Ibáñez de Mendoza et al., 2021). The advanced pathophysiology is based on possible metaplasia, a reasoning that requires further research. Most patients are symptomatic in the previous area of



surgery, with swelling being the most frequently described symptom. However, it should be kept in mind that some patients remain completely asymptomatic. The median latency period is 17 years, with extremes ranging from 2 to 56 years. The treatment performed was always enucleation. Few data are available concerning follow-up sessions. Two articles did follow-up within 30 months (Lazar et al., 2006) and 14 months (Li et al., 2014). No recurrences have been described in the literature.

The strengths of this article lie in the fact that it is the first systematic review of the literature concerning mandibular surgical ciliated cysts. It highlights the signs of this rare and poorly understood lesion in order to facilitate its diagnosis and treatment.

Weaknesses of this article are the level of evidence, selection bias, such as publication bias and biases present in the analysed articles (Drucker et al., 2016). All results were case reports, thus a low level of evidence studies. Articles dealing with patients with mandibular surgical ciliated cysts are infrequent and often suffer from methodological flaws due to their study design. Also, it would have been interesting to collect more data about follow-up and recurrences. As a result, it is difficult to draw robust conclusions from the current literature.

This systematic review raises the importance of maxillofacial surgeries in the pathophysiology of mandibular surgical ciliated cysts, with two main aetiologies: genioplasty with nasal cartilage autograft and genioplasty concomitant to maxillary osteotomies. In both cases, the pathophysiological hypothesis is an accidental implantation of the sinus membrane epithelium during genioplasty. For genioplasty with a nasal cartilage autograft, improper preparation of the graft would seem to be the cause (Drmeddent & Schwartz, 2001). In the case of maxillary osteotomies concomitant with genioplasties, the use of the same instruments in the maxillary and mandibular regions would be the cause of this epithelial graft (Koutlas et al., 2002).

Our case reports enrich the link between genioplasty using a nasal cartilage graft and surgical ciliated cysts. The twin sisters had the same surgery and complications. The data are similar to other case reports. It seems that the use of this genioplasty technique requires meticulous preparation of the graft.

Today, sliding genioplasty is the gold standard technique to modify the natural chin anatomy based on an inferior border osteotomy of the mandible, enabling 3D repositioning of the chin (Maglittio et al., 2022). Many different genioplasty techniques are described (Eppley, 2019). It seems that the technique based on nasal cartilage autograft is not widely used nowadays.

6 | CONCLUSION

In summary, cysts in the mandible can be surgical ciliated cysts. Surgical ciliated cysts are rare but mostly occur after genioplasty with a nasal cartilage autograft or simultaneous surgery on the maxilla and mandible, even decades later. When patients have a history of surgery, we should keep in mind that a surgical

ciliated cyst is a differential diagnosis of a radiolucency lesion, such as periapical cysts or odontogenic keratocysts, even in asymptomatic patients. To prevent surgical ciliated cysts in the mandible, we recommend using sliding genioplasty instead of nasal cartilaginous grafts and being careful with surgical instruments used during concomitant maxillary and mandibular surgeries.

AUTHOR CONTRIBUTIONS

Mathieu Brisset: Conceptualization; investigation; writing – original draft; methodology. **Clément Cambronne:** Writing – review and editing; visualization. **Mélanie Ferrer:** Writing – review and editing. **Sarah Cousty:** Validation; supervision; writing – review and editing. **Antoine Dubuc:** Conceptualization; methodology; supervision; validation; visualization; investigation.

ACKNOWLEDGEMENTS

Study concept and design: AD, MB. Acquisition of data: AD, MB, SC. Analysis and interpretation of data: AD, MB, MF. Drafting of the manuscript: AD, MB, MF SC. Administrative, technical and material support: AD, CC, SC. Study supervision: CC, SC. All of the named authors were involved in the paper and have read it before being submitted for publication.

CONFLICT OF INTEREST STATEMENT

The authors declare that there is no conflict of interest.

DATA AVAILABILITY STATEMENT

The authors confirm that the data supporting the findings of this study are available within the article and its (Figure S1, Tables S1-S3).

PATIENT CONSENT STATEMENT

Written informed consent was obtained from the patients for the publication of this study.

ORCID

Mathieu Brisset  <https://orcid.org/0009-0008-3743-4933>

Antoine Dubuc  <https://orcid.org/0000-0002-3927-6165>

REFERENCES

- Anastassov, G. E., & Lee, H. (1999). Respiratory mucocele formation after augmentation genioplasty with nasal osteocartilaginous graft. *Journal of Oral and Maxillofacial Surgery*, 57(10), 1263–1265. [https://doi.org/10.1016/S0278-2391\(99\)90501-3](https://doi.org/10.1016/S0278-2391(99)90501-3)
- Aromataris, E., & Munn, Z. (2020). *JBI manual for evidence synthesis*. JBI. <https://doi.org/10.46658/JBIMES-20-01>
- Bourgeois, S. L., & Nelson, B. L. (2005). Surgical ciliated cyst of the mandible secondary to simultaneous Le Fort I osteotomy and genioplasty: Report of case and review of the literature. *Oral Surgery, Oral Medicine, Oral Pathology, Oral Radiology, and Endodontology*, 100(1), 36–39. <https://doi.org/10.1016/j.tripleo.2004.12.013>
- Cai, M., Shen, G., Lu, X., & Wang, X. (2015). Two mandibular surgical ciliated cysts after Le fort I osteotomy and genioplasty. *British Journal of Oral and Maxillofacial Surgery*, 53(10), 1040–1042. <https://doi.org/10.1016/j.bjoms.2015.07.003>

- Drmeddent, M. I., & Schwartz, H. C. (2001). Respiratory implantation cyst of the mandible after Chin augmentation: Report of case. *Otolaryngology-Head and Neck Surgery*, 124(5), 586–587. <https://doi.org/10.1067/mhn.2001.115087>
- Drucker, A. M., Fleming, P., & Chan, A.-W. (2016). Research techniques made simple: Assessing risk of bias in systematic reviews. *Journal of Investigative Dermatology*, 136(11), e109–e114. <https://doi.org/10.1016/j.jid.2016.08.021>
- Eppley, B. L. (2019). Chin reshaping in Profileplasty: Augmentative and reductive strategies. *Facial Plastic Surgery*, 35(5), 499–515. <https://doi.org/10.1055/s-0039-1695750>
- Gasparyan, A. Y., Ayvazyan, L., Blackmore, H., & Kitas, G. D. (2011). Writing a narrative biomedical review: Considerations for authors, peer reviewers, and editors. *Rheumatology International*, 31(11), 1409–1417. <https://doi.org/10.1007/s00296-011-1999-3>
- Gates, J. C., Taub, D. I., Cherkas, E., Tuluc, M., & Gold, L. (2022). Surgical ciliated cyst of the maxillofacial region: A systematic review. *Bulletin of the National Research Centre*, 46(1), 235. <https://doi.org/10.1186/s42269-022-00925-7>
- Global Survey 2021. (2021). *Full report and press releases*. <https://www.isaps.org/discover/about-isaps/global-statistics/reports-and-press-releases/global-survey-2021-full-report-and-press-releases/>
- Gregory: Surgical ciliated cysts of the Maxilla:... – Google Scholar. (1958). https://scholar.google.com/scholar_lookup?title=Surgical%20ciliated%20cysts%20of%20the%20maxilla%3A%20report%20of%20cases&publication_year=1958&author=G.T.%20Gregory&author=W.G.%20Shafer
- Kubo: A buccal cyst occurred after a radical operation... – Google Scholar. (1927). https://scholar.google.com/scholar_lookup?title=A%20buccal%20cyst%20occurred%20after%20a%20radical%20operation%20of%20the%20maxillary%20sinus&journal=Z%20F%20Otol%20Tokyo&volume=3&pages=896-897&publication_year=1927&author=Kubo%20C
- Hayhurst, D. L., Moening, J. E., Summerlin, D.-J., & Bussard, D. A. (1993). Surgical ciliated cyst: A delayed complication in a case of maxillary orthognathic surgery. *Journal of Oral and Maxillofacial Surgery*, 51(6), 705–708. [https://doi.org/10.1016/S0278-2391\(10\)80277-0](https://doi.org/10.1016/S0278-2391(10)80277-0)
- Kaneshiro, S., Nakajima, T., Yoshikawa, Y., Iwasaki, H., & Tokiwa, N. (1981). The postoperative maxillary cyst: Report of 71 cases. *Journal of Oral Surgery*, 39(3), 191–198.
- Kelly, J. P. W., Malik, S., & Stucki-McCormick, S. U. (2000). Tender swelling of the Chin 40 years after Genioplasty. *Journal of Oral and Maxillofacial Surgery*, 58(2), 203–206. [https://doi.org/10.1016/S0278-2391\(00\)90340-9](https://doi.org/10.1016/S0278-2391(00)90340-9)
- Koutlas, I. G., Gillum, R. B., Harris, M. W., & Brown, B. A. (2002). Surgical (implantation) cyst of the mandible with ciliated respiratory epithelial lining: A case report. *Journal of Oral and Maxillofacial Surgery*, 60(3), 324–325. <https://doi.org/10.1053/joms.2002.30598>
- Lafuente-Ibáñez de Mendoza, I., Fernández-Reyes, M., Fernández-Arenas, A., & Aguirre-Urizar, J. M. (2021). Surgical ciliated cyst after a mandibular surgery: A particular case report and review of the literature. *BMC Oral Health*, 21(1), 633. <https://doi.org/10.1186/s12903-021-01991-5>
- Lazar, F., Hausen, A., zur Hausen, A., Mischkowski, R., & Zöller, J. E. (2006). Atypical cyst formation following chin augmentation using a nasal osteocartilaginous graft. *Journal of Cranio-Maxillofacial Surgery*, 34(2), 107–112. <https://doi.org/10.1016/j.jcms.2005.08.009>
- Li, C.-C., Feinerman, D. M., MacCarthy, K. D., & Woo, S.-B. (2014). Rare mandibular surgical ciliated cysts: Report of two new cases. *Journal of Oral and Maxillofacial Surgery*, 72(9), 1736–1743. <https://doi.org/10.1016/j.joms.2014.04.010>
- Maglittero, F., Sani, L., Piloni, S., Del Prete, G. D., Arena, A., Committeri, U., Salzano, G., Califano, L., & Friscia, M. (2022). Step-technique genioplasty: A case report. *International Journal of Surgery Case Reports*, 95, 107232. <https://doi.org/10.1016/j.ijscr.2022.107232>
- Miller, R., Longo, J., & Houston, G. (1988). Surgical ciliated cyst of the maxilla. *Journal of Oral and Maxillofacial Surgery*, 46(4), 310–312. [https://doi.org/10.1016/0278-2391\(88\)90015-8](https://doi.org/10.1016/0278-2391(88)90015-8)
- Murad, M. H., Sultan, S., Haffar, S., & Bazerbachi, F. (2018). Methodological quality and synthesis of case series and case reports. *BMJ Evidence-Based Medicine*, 23(2), 60–63. <https://doi.org/10.1136/bmjebm-2017-110853>
- Nastri, A. L., & Hookey, S. R. (1994). Respiratory epithelium in a mandibular cyst after grafting of autogenous bone. *International Journal of Oral and Maxillofacial Surgery*, 23(6), 372–373. [https://doi.org/10.1016/S0901-5027\(05\)80059-1](https://doi.org/10.1016/S0901-5027(05)80059-1)
- Page, M. J., McKenzie, J. E., Bossuyt, P. M., Boutron, I., Hoffmann, T. C., Mulrow, C. D., Shamseer, L., Tetzlaff, J. M., Akl, E. A., Brennan, S. E., Chou, R., Glanville, J., Grimshaw, J. M., Hróbjartsson, A., Lalu, M. M., Li, T., Loder, E. W., Mayo-Wilson, E., McDonald, S., ... Moher, D. (2021). The PRISMA 2020 statement: An updated guideline for reporting systematic reviews. *BMJ (Clinical Research Ed.)*, 372, n71. <https://doi.org/10.1136/bmj.n71>
- Ragsdale, B., St Laurent, J., Janette, A., & Epker, B. (2009). Respiratory implantation cyst of the mandible following orthognathic surgery. *Journal of Oral and Maxillofacial Pathology*, 13(1), 30–34. <https://doi.org/10.4103/0973-029X.48754>
- Riley, D. S., Barber, M. S., Kienle, G. S., Aronson, J. K., von Schoen-Angerer, T., Tugwell, P., Kiene, H., Helfand, M., Altman, D. G., Sox, H., Werthmann, P. G., Moher, D., Rison, R. A., Shamseer, L., Koch, C. A., Sun, G. H., Hanaway, P., Sudak, N. L., Kaszkin-Bettag, M., ... Gagnier, J. J. (2017). CARE guidelines for case reports: Explanation and elaboration document. *Journal of Clinical Epidemiology*, 89, 218–235. <https://doi.org/10.1016/j.jclinepi.2017.04.026>
- Seifi, S., Sohanian, S., Khakbaz, O., Abesi, F., Aliakbarpour, F., & Rayani, A. (2016). Ectopic ciliated cyst in the mandible secondary to genioplasty and lefort after two years: A case report and literature review. *Iranian Journal of Otorhinolaryngology*, 88, 353–356.
- Soares, J. C., Villalba, N. C., Sanromán, J. F., Ferro, M. F., Fernández, P. L., Betancourt, A. L., & López, A. C. (2021). Surgical ciliated cysts in Orthognathic surgery. *Journal of Craniofacial Surgery*, 32(1), e2–e5. <https://doi.org/10.1097/SCS.00000000000006805>
- Surgical ciliated cyst of the left maxilla—A case report of unusual pathogenesis—PMC. (n.d.). <https://www.ncbi.nlm.nih.gov/pmc/articles/PMC7944008/>
- Syyed, N., Mason, R., Thomson, E., & Downie, J. (2018). Mandibular respiratory cysts following orthognathic surgery: 2 rare case reports. *International Journal of Surgery*, 55, S68. <https://doi.org/10.1016/j.ijso.2018.05.316>
- Youn, S., Oh, H. J., Yoon, H.-J., & Seo, B.-M. (2022). Surgical ciliated cyst of the mandible after orthognathic surgery: A case report with review of the literature. *Maxillofacial Plastic and Reconstructive Surgery*, 44(1), 26. doi:10.1186/s40902-022-00356-4

SUPPORTING INFORMATION

Additional supporting information can be found online in the Supporting Information section at the end of this article.

How to cite this article: Brisset, M., Cambronnie, C., Ferrer, M., Cousty, S., & Dubuc, A. (2024). Surgical ciliated cysts of the mandible: A systematic review of case reports. *Oral Diseases*, 30, 2858–2864. <https://doi.org/10.1111/odi.14795>