



HAL
open science

Evaluation of the All-Inside Technique for the Repair of Lateral Meniscus Root Tears at 1 Year After ACL Reconstruction

Marianne Cuvillier, Vincent Marot, Frane Bukvić, Thibaut Lucena, Vincent Martinel, Emilie Bérard, Etienne Cavaignac

► **To cite this version:**

Marianne Cuvillier, Vincent Marot, Frane Bukvić, Thibaut Lucena, Vincent Martinel, et al.. Evaluation of the All-Inside Technique for the Repair of Lateral Meniscus Root Tears at 1 Year After ACL Reconstruction. *Orthopaedic Journal of Sports Medicine*, 2023, 11 (6), pp.23259671221149716. 10.1177/23259671221149716 . hal-04814566

HAL Id: hal-04814566

<https://ut3-toulouseinp.hal.science/hal-04814566v1>

Submitted on 2 Dec 2024

HAL is a multi-disciplinary open access archive for the deposit and dissemination of scientific research documents, whether they are published or not. The documents may come from teaching and research institutions in France or abroad, or from public or private research centers.

L'archive ouverte pluridisciplinaire **HAL**, est destinée au dépôt et à la diffusion de documents scientifiques de niveau recherche, publiés ou non, émanant des établissements d'enseignement et de recherche français ou étrangers, des laboratoires publics ou privés.



Distributed under a Creative Commons Attribution - NonCommercial - NoDerivatives 4.0 International License

Evaluation of the All-Inside Technique for the Repair of Lateral Meniscus Root Tears at 1 Year After ACL Reconstruction



Marianne Cuvillier,* MD, Vincent Marot,[†] MD, Frane Bukvić,[‡] MD, PhD, Thibaut Lucena,[‡] MD, Vincent Martinel,[§] MD, Emilie Bérard,^{||} MD, and Etienne Cavaignac,^{‡¶} MD, PhD

Investigation performed at CHU de Toulouse, Toulouse, France

Background: The presence of a lateral meniscus root tear (LMRT) in patients with an anterior cruciate ligament (ACL) tear makes the knee more unstable and increases the risk of osteoarthritis and osteonecrosis. An all-inside suture repair technique without bone tunnels has been proposed to treat LMRT.

Purpose: To compare the 1-year postoperative findings between patients who underwent ACL reconstruction combined with LMRT repair (LMRT group) and patients who underwent isolated ACL reconstruction (control group).

Study Design: Cohort study; Level of evidence, 3.

Methods: The LMRT group consisted of 19 patients, and the control group consisted of 56 patients. In this study, the authors compared the postoperative magnetic resonance imaging (MRI) findings (meniscal extrusion, ghost sign, and hyperintensity in the tibial plateau beneath the LMRT), functional outcomes (International Knee Documentation Committee [IKDC], Lysholm, and Tegner scores), and reoperation rate between groups. The primary endpoint was analyzed by comparing, in the LMRT group, the 1-sided 97.5% confidence interval (CI) of the mean lateral meniscal extrusion at 1 year to the limit of noninferiority (fixed at 0.51). To take into account imbalanced baseline characteristics between groups, adjusted mean meniscal extrusion (with 1-sided 97.5% CI) was assessed using a linear regression model.

Results: The mean follow-up was 12.2 months (range, 7.7-14.7 months) in the control group and 11.5 months (range, 7.1-13.0 months) in the LMRT group ($P = .06$). For meniscal extrusion, the LMRT group was noninferior to the control group. The mean meniscal extrusion was 2.19 mm (97.5% CI, $-\infty$ to 2.68 mm) in the LMRT group and 2.03 mm (97.5% CI, $-\infty$ to 2.27 mm) in the control group, indicating that the upper boundary of the 1-sided 97.5% CI in the LMRT group was less than the noninferiority threshold of 2.78 (ie, $2.27 \text{ mm} + 0.51 \text{ mm} = 2.78 \text{ mm}$). There was a statistically significant difference in the IKDC score between the LMRT and control groups (77.2 ± 8.1 vs 80.3 ± 7.3 , respectively; $P = .04$). There was no between-group difference in the other MRI parameters, the Lysholm and Tegner scores, or the reoperation rate.

Conclusion: There was no significant difference in extrusion on MRI or clinical outcomes at 1-year follow-up in patients who underwent ACL reconstruction with all-inside LMRT repair compared with patients who did not have an LMRT.

Keywords: lateral meniscus root repair; all-inside technique; ACL tear

Lateral meniscus root tears (LMRTs) are present in 7% to 14% of patients who suffer a knee injury that tears the anterior cruciate ligament (ACL).^{5,13,15,27} In our practice, the prevalence of LMRT is 13% based on an analysis of more than 600 primary ACL reconstruction cases.⁹ These injuries are defined as a radial or longitudinal tear within 1 cm of the attachment site of the posterior root or damage to the meniscotibial ligaments.²⁴

This type of tear, which alters meniscal continuity, leads to poor distribution of tibiofemoral stresses during weight-bearing, with a significant increase in contact pressure.^{3,34}

Also, LMRT makes the knee even more unstable when the ACL is torn.³⁰ The lateral meniscus is one of the knee's secondary stabilizers.^{14,29} The presence of an LMRT may accelerate the progression of osteoarthritis and may contribute to the development of osteonecrosis or high-grade osteochondral lesions.^{11,13}

Thus, it appears to be vital to restore the integrity of the meniscus by repairing these LMRTs.^{7,17} Various techniques can be used, including pull-out and all-inside techniques.^{11,20} The pull-out technique consists of whipstitching the lateral root and then securing it to the tibia through 1 or 2 transosseous tunnels. Clinical and imaging evaluations show that this technique produces good results with reduced meniscal extrusion at 1 year postoperatively.^{3,11} The all-inside technique consists of

The Orthopaedic Journal of Sports Medicine, 11(6), 23259671221149716

DOI: 10.1177/23259671221149716

© The Author(s) 2023

This open-access article is published and distributed under the Creative Commons Attribution - NonCommercial - No Derivatives License (<https://creativecommons.org/licenses/by-nc-nd/4.0/>), which permits the noncommercial use, distribution, and reproduction of the article in any medium, provided the original author and source are credited. You may not alter, transform, or build upon this article without the permission of the Author(s). For article reuse guidelines, please visit SAGE's website at <http://www.sagepub.com/journals-permissions>.

suturing the meniscus root to the remainder of the meniscus, using intrameniscal repair devices. This technique can be used to treat LaPrade types 1 to 4 lesions.¹⁶ To our knowledge, there are few reports of the clinical and functional outcomes of this technique.^{23,32,33}

We believed that it was appropriate to compare the outcomes at 1 year postoperatively of patients who underwent LMRT repair using the all-inside technique concurrently with ACL reconstruction with the outcomes of patients who underwent isolated ACL reconstruction. We hypothesized that all-inside repair of LMRT would not increase the meniscal extrusion of LMRT repair compared with isolated ACL reconstruction. The primary objective of the current study was to compare meniscal extrusion on magnetic resonance imaging (MRI) at 1 year postoperatively after ACL reconstruction in patients who did or did not have a repaired LMRT. The secondary objective was to compare 1-year postoperative MRI findings (eg, ghost sign or hyperintensity in the lateral tibial plateau beneath the root), functional scores, and reoperation rates in these patients. The lack of MRI signs would be favorable for healing. The ghost sign's disappearance would indicate healing of the root, and less intensity in the lateral tibial plateau would indicate healing of the subchondral lesions.

METHODS

Patients

This was a retrospective study of data routinely collected prospectively in patients operated on between January 1, 2020, and January 1, 2021. The study protocol received ethics committee approval, and informed consent was obtained from every study participant.

Patients were included if they met the following criteria: (1) acute anterior instability of the knee due to a torn ACL, (2) closed growth plates and age <50 years, and (3) minimum 1 year of follow-up since surgery. The following exclusion criteria were used: (1) LMRT graded as LaPrade type 5 and/or Petersen type 3^{16,26}; (2) injury in the contralateral knee; (3) prior injury in the knee that was operated on for this study; (4) patellofemoral pain syndrome; (5) systemic disease; (6) medial collateral ligament (MCL), lateral collateral ligament, or posterior cruciate ligament tear; (7) cartilage lesion or osteoarthritis or fracture; and (8) presence of other meniscal tears.

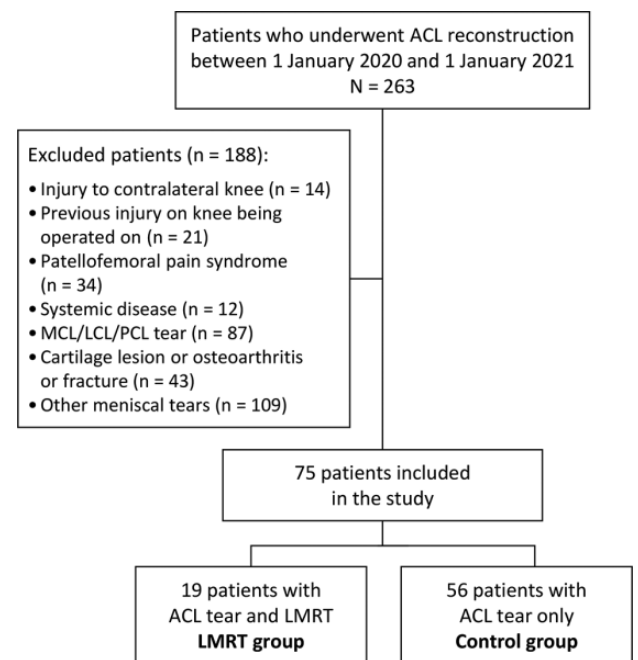


Figure 1. Flowchart of patient enrollment. ACL, anterior cruciate ligament; LCL, lateral collateral ligament; LMRT, lateral meniscus root tear; MCL, medial collateral ligament; PCL, posterior cruciate ligament.

Between January 1, 2020, and January 1, 2021, a total of 263 patients underwent ACL reconstruction at our facility and 188 patients were excluded. Thus, 75 were included in this study. Among them, 56 patients had an isolated ACL tear (control group) and 19 had an ACL tear combined with an LMRT but no other injuries (LMRT group). No patients were lost to follow-up (Figure 1).

Patients in the LMRT group had LaPrade types 1 to 4 lesions along with Petersen types 1 or 2 lesions, that is, no damage to the meniscofemoral ligament.^{16,26} LaPrade type 5 and Petersen type 3 LMRTs were excluded from the study because we did not believe these could be sutured using the all-inside technique. There were 6 patients with LaPrade type 1; 9 patients with type 2; 2 patients with type 3; and 2 patients with type 4 lesions.

The patients' preoperative characteristics are summarized in Table 1. Among these, the sex ratio, meniscal extrusion, ghost sign, and hyperintensity on the articular surface

*Address correspondence to Etienne Cavaignac, MD, PhD, Hôpital Pierre Paul Riquet, Rue Jean Dausset, 31000 Toulouse, France (email: cavaignac.etienne@gmail.com).

†Jean Monnet University, Mines Saint-Étienne, INSERM, U1059, SAINBIOSE, University Hospital of Saint-Etienne, Orthopedics, Trauma and Bone & Joint Infection Center, Saint Etienne, France.

‡Hospital Nostra Senyora de Meritxell, Orthopedics Units, Escaldes, Andorra.

§Department of Orthopedic Surgery and Trauma, Pierre-Paul Riquet Hospital, Toulouse, France.

¶Orthopedic Group Ormeau Pyrénées, Polyclinique de l'Ormeau ELSAN, Tarbes, France.

||Department of Epidemiology, Health Economics and Public Health, UMR 1295 CERPOP, University of Toulouse, INSERM, UPS, Toulouse University Hospital (CHU de Toulouse), Toulouse, France.

Final revision submitted October 1, 2022; accepted October 21, 2022.

One or more of the authors has declared the following potential conflict of interest or source of funding: E.C. has received consulting fees from Arthrex. AOSSM checks author disclosures against the Open Payments Database (OPD). AOSSM has not conducted an independent investigation on the OPD and disclaims any liability or responsibility relating thereto.

Ethical approval for this study was obtained from CHU de Toulouse (reference No. RnlPH 2021-64).

TABLE 1
Preoperative Characteristics of the Patients^a

	Total (N = 75)	LMRT Group (n = 19; 25.3%)	Control Group (n = 56; 74.7%)	P
Age, y	25.6 ± 8.4	23.1 ± 6.6	26.5 ± 8.8	.16
Sex				.01
Female	38 (50.7)	5 (26.3)	33 (58.9)	
Male	37 (49.3)	14 (73.7)	23 (41.1)	
BMI (kg/m ²)	23.3 ± 2.6	23.3 ± 2.1	23.3 ± 2.8	.76
Smoker				>.9999
Yes	5 (6.7)	1 (5.3)	4 (7.1)	
No	70 (93.3)	18 (94.7)	52 (92.9)	
Side affected				.46
Left	41 (54.7)	9 (47.4)	32 (57.1)	
Right	34 (45.3)	10 (52.6)	24 (42.9)	
Ghost sign				<.0001
No	52 (69.3)	3 (15.8)	49 (87.5)	
Yes	23 (30.7)	16 (84.2)	7 (12.5)	
Meniscal extrusion, mm	2.4 ± 1.2	3.5 ± 0.9	2.1 ± 1.0	<.0001
Hyperintensity on articular surface across LMRT				<.0001
No	54 (72.0)	7 (36.8)	47 (83.9)	
Yes	21 (28.0)	12 (63.2)	9 (16.1)	
Preoperative IKDC	55.8 ± 13.6	53.2 ± 12.4	56.8 ± 14.0	.32
Preoperative Lysholm	69.0 ± 11.4	70.1 ± 10.3	68.7 ± 11.8	.63
Preoperative Tegner	5.3 ± 1.5	5.4 ± 1.4	5.3 ± 1.5	.67

^aData are reported as mean ± SD or n (%). Boldface P values indicate a statistically significant difference between the lateral meniscus root tear (LMRT) and control groups ($P < .05$). BMI, body mass index; IKDC, International Knee Documentation Committee.

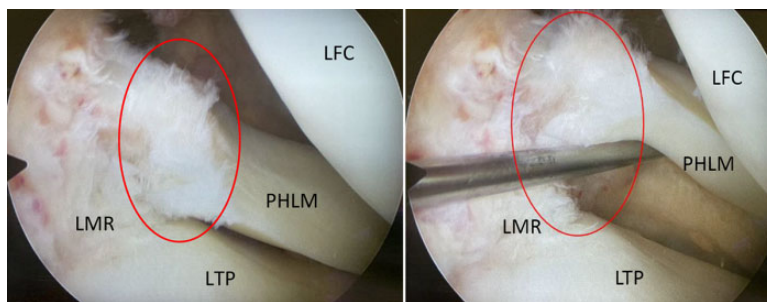


Figure 2. Arthroscopic images of a (A) LaPrade type 1 lateral meniscus root tear (circled in red) (B) searched and highlighted with a probe. LFC, lateral femoral condyle; LMR, lateral meniscus root; LTP, lateral tibial plateau; PHLM, posterior horn of the lateral meniscus.

across from the LMRT were significantly different between the 2 groups. There were significantly more women in the control group than in the LMRT group (59% vs 26%; $P = .0140$). This is consistent with the literature since women are more likely to suffer an isolated ACL injury and there are more LMRT in men.^{27,30} Thus, the comparison for the primary endpoint was adjusted for these variables using a linear regression model.

Surgical Technique

All patients were operated on by the same surgeon (E.C.). Standard medial and lateral arthroscopy portals were used. The LMRT was debrided and then sutured before the ACL reconstruction using an accessory portal through the

patellar tendon.^{8,23} At least 2 horizontal throws in a single row were placed using a FAST-FIX device (Smith & Nephew) about 5 mm on either side of the meniscal tear (Figures 2 and 3 and Supplemental Video). At least 2 sutures were made. The ACL reconstruction was performed as follows: a semitendinosus graft was used to reconstruct the ACL, with its tibial insertion intact to improve fixation and vascularity. The semitendinosus was folded into 3 strands to form a graft with a diameter of 8 to 10 mm and a length of 10 to 12 mm from its tibial insertion. A 15-mm blind tunnel was made through the femur using an inside-out technique. The tibial tunnel was drilled completely through the incision of the semitendon harvest. The outside-in guide was positioned at the level of the native ACL remnant.^{14,15,17,18,21}

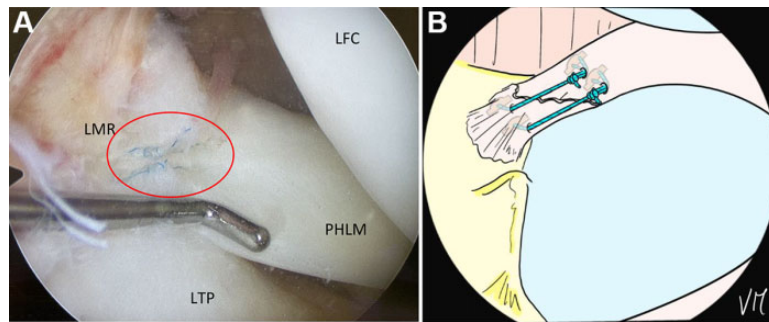


Figure 3. (A) Arthroscopic image showing all-inside repair of a lateral meniscus root tear using 2 horizontal sutures with a FAST-FIX device. (B) Diagram showing the all-inside repair of a lateral meniscus root tear. LFC, lateral femoral condyle; LMR, lateral meniscus root; LTP, lateral tibial plateau; PHLM, posterior horn of the lateral meniscus.

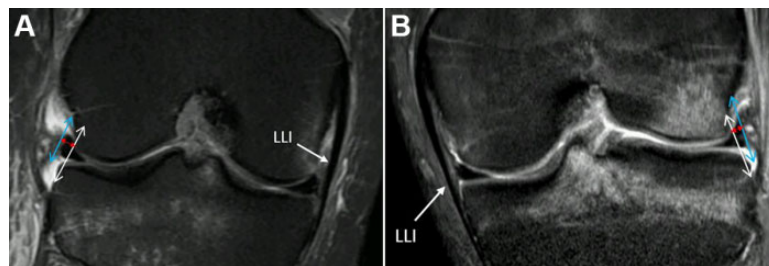


Figure 4. Measurement of meniscal extrusion (red arrow) between the lateral edge of the lateral meniscus (blue arrow) and the lateral edge of the lateral tibial plateau and lateral femoral condyle (white arrow) on coronal magnetic resonance imaging slices through the medial collateral ligament. (A) Right knee. (B) Left knee.

The patients in both groups underwent the same postoperative rehabilitation protocol, including full weightbearing allowed immediately and full range of motion. Physical therapy began on postoperative day 1.

Study Endpoints

The primary endpoint was the amount of meniscal extrusion at 1 year postoperatively. The mean follow-up was 12.2 months (range, 7.7-14.7 months) in the control group and 11.5 months (range, 7.1-13.0 months) in the LMRT group ($P = .06$). The secondary endpoints were the presence of a ghost sign and/or the presence of hyperintensity in the articular surface across the LMRT on MRI, the functional outcome scores, and the reoperation rate at 1 year postoperatively.

Data collection was performed in the same manner for each patient, independent of the group. The clinical data were collected by an attending surgeon (T.L.) with specific experience in musculoskeletal imaging.

All patients underwent a preoperative MRI and another MRI at 1 year postoperatively. All the MRI examinations were carried out in the same machine, using the same protocol (knee extended) for all patients (3-T MRI, coronal and sagittal fast spin echo, T2-weighted, fat-saturated imaging was used). For every MRI scan, extrusion of the lateral meniscus was evaluated by a single examiner (M.C.) specialized in musculoskeletal imaging. Meniscal extrusion was measured as the distance between a line joining the tibial and femoral lateral

edges and the lateral edge of the lateral meniscus on a coronal MRI slice through the MCL (Figure 4).^{4,6,10,25}

The MRI scans were also evaluated for indirect signs of LMRT. The ghost sign corresponded to a lack of identifiable meniscus in the sagittal plane or the presence of high signal intensity replacing the low signal typical of the meniscus. Another indirect sign was a hyperintensity under the articular surface across the LMRT (Figure 5).^{7,29,32}

The diagnosis of LMRT was confirmed intraoperatively during knee arthroscopy, which is the gold standard (Figure 3). The International Knee Documentation Committee (IKDC), Lysholm, and Tegner functional scores were recorded preoperatively and at the 1-year follow-up visit. The need for reoperation for any reason was also documented.

Statistical Analysis

To calculate the sample size, based on a prior study we hypothesized that patients in the LMRT group had a mean lateral meniscal extrusion at 1 year of 0.48 mm with a standard deviation of 0.57 mm and that patients in the control group had the same mean lateral meniscal extrusion at 1 year.³³ We wanted to show that, at worst, mean lateral meniscal extrusion in the LMRT group was <1 mm (ie, with a margin of noninferiority of 0.51). With a sample allocation ratio of 1:3, a 1-sided alpha of 2.5% (ie, a 1-sided 97.5% CI), and a 1-sided beta of 10%, we needed to include 15 patients in the LMRT group and 45 patients in the control group.¹⁹

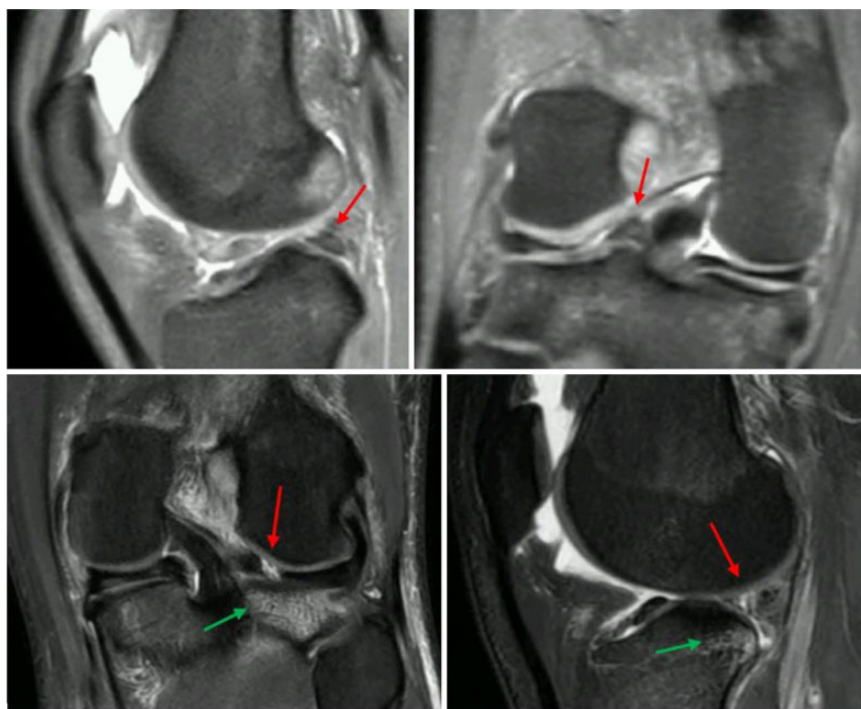

Figure 5. Ghost signs (red arrows) and hyperintensity under the articular surface across the meniscus root (green arrows) on right and left knees MRI scans.

Before analyses, verification for missing, aberrant, or inconsistent data was conducted. After corrections, the database was locked, and analysis was performed on the locked database. We first described the baseline characteristics of the patients in each group using the appropriate descriptive statistics according to the type of variables. Descriptive statistics included mean with standard deviation for continuous variables and count with frequency (percent) for categorical variables. Categorical endpoints were compared between groups using the chi-square test (or Fisher exact test when necessary). The Student *t* test was used to compare the distribution of continuous secondary endpoints, or the Mann-Whitney test was used when the distribution deviated from normality or when homoscedasticity was rejected. All reported *P* values were 2-sided, and the significance threshold was $<.05$.

The primary endpoint was analyzed by comparing in the LMRT group the 1-sided 97.5% confidence interval (CI) of the mean lateral meniscal extrusion at 1 year to the limit of noninferiority, which was fixed to 0.51 in the sample size. To take into account imbalanced baseline characteristics between groups, adjusted mean lateral meniscal extrusion with 1-sided 97.5% CI was assessed using a linear regression model. Statistical analyses were performed using Stata 17.0 (Stata Corp).

RESULTS

Primary Endpoint

After adjusting for baseline differences between groups in sex ratio, preoperative meniscal extrusion, preoperative ghost sign, and hyperintensity, the mean postoperative meniscal

extrusion was 2.19 mm (97.5% CI,— infinity to 2.68 mm) in the LMRT group and 2.03 mm (97.5% CI,— infinity to 2.27 mm) in the control group. To demonstrate noninferiority of the LMRT relative to the control group, the upper boundary of the 1-sided 97.5% CI of the mean postoperative meniscal extrusion in the LMRT group needed to be <2.78 mm (ie, $2.27 + 0.51 = 2.78$). Thus, after adjusting for the baseline disparities between groups, the mean postoperative meniscal extrusion of the LMRT group was not inferior to that of the control group. This showed that repairing the LMRT using the all-inside technique significantly reduced meniscal extrusion, resulting in noninferior meniscal extrusion relative to the control group. The mean change in meniscal extrusion between the preoperative and 1-year postoperative measurements was significantly higher for the LMRT group than for the control group (-0.7 ± 1.1 mm vs -0.2 ± 0.8 mm, respectively; $P = .04$).

Secondary Endpoints

Detailed information about the secondary endpoints is provided in Table 2. The ghost sign was absent on MRI at 1 year postoperatively in all patients except one with an LMRT ($P = .25$). None of the patients in either group had a hyperintensity across the meniscus root.

The IKDC score was significantly better in the control group ($P = .04$) but the magnitude (3.1 points) was less than the minimal clinically important difference of 11.5 points for the IKDC.¹² There was no significant difference between groups in the number of surgical revisions ($P = .1$). There were 3 revisions in the LMRT group: 1 anterior arthrolysis

TABLE 2
Secondary Endpoints^a

	Total (N ¼ 75)	LMRT Group (n ¼ 19; 25.3%)	Control Group (n ¼ 56; 74.7%)	<i>P</i>
Ghost sign				.25
No	74 (98.7)	18 (94.7)	56 (100.0)	
Yes	1 (1.3)	1 (5.3)	0 (0.0)	
Hyperintensity on articular surface below LMRT				—
No	75 (100.0)	19 (100.0)	56 (100.0)	
Yes	0 (0.0)	0 (0.0)	0 (0.0)	
IKDC	79.5 ± 7.5	77.2 ± 8.1	80.3 ± 7.3	.04
Lysholm	92.3 ± 6.8	91.1 ± 8.0	92.8 ± 6.3	.47
Tegner	6.2 ± 1.3	5.9 ± 1.5	6.3 ± 1.2	.34
Surgical revision				.1
No	70 (93.3)	16 (84.2)	54 (96.4)	
Yes	5 (6.7)	3 (15.8)	2 (3.6)	

^aData are reported as mean ± SD or n (%). Boldface *P* value indicates a statistically significant difference between the lateral meniscus root tear (LMRT) and control groups (*P* < .05). IKDC, International Knee Documentation Committee.

and 2 for treatment of ACL retears after another injury event. There were 2 revisions in the control group; both were for ACL retears after another injury event. All LMRT repairs had healed at the time of revision surgery.

DISCUSSION

Our hypothesis was confirmed. In patients who underwent ACL reconstruction and LMRT repair, meniscal extrusion was not significantly different than in patients with isolated ACL reconstruction. There was no significant difference between the 2 groups in the secondary endpoints based on MRI analysis. In terms of functional outcomes, only the IKDC score was significantly different between groups. However, the mean IKDC score was 77.2 ± 8.1 in the LMRT group and 80.3 ± 7.3 in the control group, which were both less than the minimal clinically important difference.¹² Lastly, there was no significant difference between the 2 groups in the number of surgical revisions. Although the number was greater in the LMRT group, the difference was not statistically significant after adjustment for the various factors; the younger age of the LMRT group probably explains part of this result.

The pull-out technique consists of whipstitching the meniscus root, mainly using antegrade forceps or poly(P-dioxanone) suture-like suture material, and then securing it to the tibia via 1 or 2 transosseous tunnels. Clinical and imaging evaluations show that this technique produces good results with reduced meniscal extrusion at 1 year postoperatively.^{23,31} This reduction in meniscal extrusion depends on proper positioning of the tibial tunnels.¹⁰

The all-inside technique to repair LMRT described by Ouanazar et al²³ has several advantages. This technique can be carried out reliably with standard arthroscopy. Since no transosseous tunnels are needed, the potential for tunnel convergence is reduced during multiligament reconstruction.¹⁸ Passing the suture as a single row directly from one side to the other of the tear produces optimal tension on the suture.

There is no need for any specific instrumentation, and the anchors can be the same ones used for suturing the meniscal wall or posterior horn tears, contrary to the pull-out technique.⁶ The all-inside technique has possible disadvantages, such as the risks of inducing meniscal lesions or tears when applying excessive tension through the knot or leaving a bulky intra-articular knot that could be deleterious in the knee.¹⁸

To our knowledge, this is the first study comparing the results of isolated ACL reconstruction with intact meniscus to those of ACL reconstruction plus all-inside repair of an LMRT. Only 2 similar clinical studies were identified in the published literature (Table 3). Ahn et al² compared 2 groups of patients with torn ACL who had LMRT that was either sutured or left unrepaired. In the unrepaired group, the clinical outcomes were significantly worse, and signs of osteoarthritis appeared earlier. However, contrary to our study, it was impossible to say that the lateral meniscus was restored to its original condition because the meniscus' structure was not analyzed on MRI. The study by Zhuo et al³³ compared patients who had an isolated LMRT with patients who had a combination of LMRT and ACL tear. They found a significant difference in the clinical scores between groups, but no MRI findings were provided. Thus, it is difficult to compare these 2 groups, since an ACL tear can have an outsized impact on the clinical outcomes.

The study by Tsujii et al³¹ compared the all-inside and inside-out techniques but found no significant difference between them. There was no information to support a claim that the lateral meniscus is restored to its original condition. Also, Shumborski et al²⁸ showed that stable external meniscus root injuries do not require intervention because the long-term results are the same as those of an intact meniscus.

Limitations

The current study has several limitations. The follow-up period was relatively short to be able to detect degenerative changes that the meniscus root repair is trying to prevent.

TABLE 3
Key Published Studies on LMRT Repair Outcomes^a

Study	Technique and Group	Meniscal Extrusion, mm	Lysholm	Tegner	IKDC
Aga et al ¹	Pull-out Preoperative	2.3 ± 1.5	—	—	—
	Postoperative	1.4 ± 1.09	79.2 ± 16.0	4.3 ± 2.0	—
	<i>P</i>	.08	>.05	<.05	—
Ahn et al ²	All-inside (PDS and Maxon) Preoperative	0.73 ± 1.10	62.3 ± 17.43	—	67.0 ± 15.64
	Postoperative	0.34 ± 1.15	92.9 ± 3.37	—	90.2 ± 7.32
	<i>P</i>	.096	—	—	—
Okazaki et al ²²	—	0.5 ± 0.7	—	—	73.0 ± 17.7
	Pull-out	—	—	—	—
	Other repairs (4 inside-out, 4 all-inside)	1.0 ± 0.9	—	—	0.7 ± 16.8
	<i>P</i>	0.01	—	—	>.05
Tsujii et al ³¹	—	20.29 ± 0.87	—	—	—
	Inside-out	—	—	—	—
	All-inside	0.18 ± 0.81	—	—	—
	<i>P</i>	.23	—	—	—
Zhuo et al ³³	All-inside Preoperative	—	56.3 ± 4.59	2.41 ± 0.56	53.4 ± 5.32
	Postoperative	—	94.9 ± 2.59	5.27 ± 0.75	84.0 ± 3.09
	<i>P</i>	—	.01	.01	.01
Zhuo et al ³⁴	Pull-out Preoperative	3.29 ± 0.85	32.65 ± 22.76	1.46 ± 1.10	35.05 ± 22.81
	Postoperative	0.48 ± 0.57	99.42 ± 1.63	5.92 ± 0.89	99.42 ± 1.10
	<i>P</i>	.001	.01	.01	.01
Current study	All-inside	0.7 ± 1.1	91.1 ± 8.0	5.9 ± 1.5	77.2 ± 8.1
	LMRT	—	—	—	—
	Control	0.2 ± 0.8	92.8 ± 6.3	6.3 ± 1.2	80.3 ± 7.3
	<i>P</i>	.04	.47	.34	.04

^aData are reported as mean ± SD. Boldface *P* values indicate a statistically significant difference between the groups compared ($P < .05$). Dashes indicate areas not applicable. IKDC, International Knee Documentation Committee; LMRT, lateral meniscus root tear; PDS, poly(P-dioxanone) suture.

New studies could be done on this topic with longer follow-up. Nevertheless, we used the same evaluation methods and time points as other studies on LMRT repair, allowing us to make a direct comparison with previously published studies. It may also be interesting to look for a correlation between meniscal extrusion and the early signs of osteoarthritis. The number of patients included is also relatively small given the low prevalence of LMRT; the 7% prevalence in our practice during the study is consistent with published data.^{5,13} The gold standard to determine whether an LMRT is healed would be second-look arthroscopy. However, MRI is the benchmark in the literature to assess LMRT healing for obvious ethical reasons.^{4,27} It is well accepted in the literature that measuring meniscal extrusion is a good proxy for meniscal function.^{4,13,14} Measuring meniscal extrusion on MRI is a reproducible assessment, justifying having only 1 radiologist to read the images.⁴ It would have been interesting to compare the clinical outcomes of the all-inside technique with those of the pull-out technique, however. This will require a separate study using randomized design.

CONCLUSION

In patients undergoing ACL reconstruction, there was no significant difference in extrusion on MRI or clinical outcomes at 1-year follow-up in patients who underwent an all-inside LMRT repair versus those who did not have an

LMRT. Thus, the all-inside technique is a reliable option for repairing LMRT.

A video supplement for this article is available at <https://journals.sagepub.com/doi/full/10.1177/23259671221149716#supplementary-materials>.

ACKNOWLEDGMENT

The authors are grateful to Joanne Archambault, PhD, for the English-language assistance.

REFERENCES

1. Aga C, Aasen IB, Brocker C, Kise NJ, Heir S. Lateral meniscal posterior root tears experience acceptable healing status after transtibial repair technique. *J Exp Orthop*. 2021;8:114.
2. Ahn JH, Lee YS, Yoo JC, Chang MJ, Park SJ, Pae YR. Results of arthroscopic all-inside repair for lateral meniscus root tear in patients undergoing concomitant anterior cruciate ligament reconstruction. *Arthroscopy*. 2010;26(1):67-75.
3. Berthold DP, Muench LN, Herbst E, et al. High prevalence of a deep lateral femoral notch sign in patients with anterior cruciate ligament (ACL) and concomitant posterior root tears of the lateral meniscus. *Knee Surg Sports Traumatol Arthrosc*. 2021;29(4):1018-1024.
4. Choi SH, Bae S, Ji SK, Chang MJ. The MRI findings of meniscal root tear of the medial meniscus: emphasis on coronal, sagittal and axial

- images. *Knee Surg Sports Traumatol Arthrosc.* 2012;20(10):2098-2103.
5. DePhillipo NN, Dekker TJ, Aman ZS, Bernholt D, Grantham WJ, LaPrade RF. Incidence and healing rates of meniscal tears in patients undergoing repair during the first stage of 2-stage revision anterior cruciate ligament reconstruction. *Am J Sports Med.* 2019;47(14):3389-3395.
 6. Feucht MJ, Izadpanah K, Lacheta L, Südkamp NP, Imhoff AB, Forkel P. Arthroscopic transtibial pullout repair for posterior meniscus root tears. *Oper Orthop Traumatol.* 2019;31(3):248-260.
 7. Forkel P, von Deimling C, Lacheta L, et al. Repair of the lateral posterior meniscal root improves stability in an ACL-deficient knee. *Knee Surg Sports Traumatol Arthrosc.* 2018;26(8):2302-2309.
 8. Gillquist J, Hagberg G. A new modification of the technique of arthroscopy of the knee joint. *Acta Chir Scand.* 1976;142(2):123-130.
 9. Gracia G, Cavaignac M, Marot V, Mouarbes D, Laumonerie P, Cavaignac E. Epidemiology of combined injuries of the secondary stabilizers in ACL-deficient knees: medial meniscal ramp lesion, lateral meniscus root tear, and ALL tear: a prospective case series of 602 patients with ACL tears from the SANTI Study Group. *Am J Sports Med.* 2022;50(7):1843-1849.
 10. Guermazi A, Hayashi D, Jarraya M, et al. Medial posterior meniscal root tears are associated with development or worsening of medial tibiofemoral cartilage damage: the multicenter osteoarthritis study. *Radiology.* 2013;268(3):814-821.
 11. Helito CP, Melo L da P, Guimarães TM, et al. Alternative techniques for lateral and medial posterior root meniscus repair without special instruments. *Arthroscopy Techniques.* 2020;9(7):e1017-e1025.
 12. Irrgang JJ, Anderson AF, Boland AL, et al. Responsiveness of the International Knee Documentation Committee Subjective Knee Form. *Am J Sports Med.* 2006;34(10):1567-1573.
 13. Kamatsuki Y, Furumatsu T, Fujii M, et al. Complete tear of the lateral meniscus posterior root is associated with meniscal extrusion in anterior cruciate ligament deficient knees. *J Orthop Res.* 2018;36(7):1894-1900.
 14. Krych AJ, Hevesi M, Leland DP, Stuart MJ. Meniscal root injuries. *J Am Acad Orthop Surg.* 2020;28(12):491-499.
 15. Krych AJ, LaPrade MD, Cook CS, et al. Lateral meniscal oblique radial tears are common with ACL injury: a classification system based on arthroscopic tear patterns in 600 consecutive patients. *Orthop J Sports Med.* 2020;8(5):232596712092173.
 16. LaPrade CM, James EW, Cram TR, Feagin JA, Engebretsen L, LaPrade RF. Meniscal root tears: a classification system based on tear morphology. *Am J Sports Med.* 2015;43(2):363-369.
 17. LaPrade RF, Moulton SG, Cram TR, Geeslin AG, LaPrade CM, Engebretsen L. Meniscal root repairs. *JBJS Essent Surg Tech.* 2015;5(4):e19.
 18. Leyes M, Flores-Lozano C, de Rus I, Salvador MG, Buenadicha EM, Villarreal-Villarreal G. Repair of the posterior lateral meniscal root tear: suture anchor fixation through the outside-in anterior cruciate ligament reconstruction femoral tunnel. *Arthrosc Tech.* 2021;10(1):e151-e158.
 19. Machin D, Campbell MJ, Tan SB, Tan SH. *Sample Size Tables for Clinical Studies.* 1st ed. Wiley; 2008.
 20. Mao DW, Lee YHD. All-inside techniques for meniscal radial root tear repair. *Arthrosc Tech.* 2020;9(10):e1541-e1545.
 21. Mesnier T, Cavaignac M, Marot V, Reina N, Cavaignac E. Knee anterolateral ligament reconstruction with knotless soft anchor: shallow fixation prevents tunnel convergence. *Arthrosc Tech.* 2022;11(4):e511-e516.
 22. Okazaki Y, Furumatsu T, Kamatsuki Y, et al. Transtibial pullout repair of the lateral meniscus posterior root tear combined with anterior cruciate ligament reconstruction reduces lateral meniscus extrusion: a retrospective study. *Orthop Traumatol Surg Res.* 2020;106(3):469-473.
 23. Ouanezar H, Thauinat M, Saithna A, Fernandes LR, Sonnery-Cottet B. Suture repair of full radial posterior lateral meniscus tears using a central midline portal. *Arthrosc Tech.* 2017;6(5):e1801-e1806.
 24. Pache S, Aman ZS, Kennedy M, et al. Meniscal root tears: current concepts review. *Arch Bone Jt Surg.* 2018;6(4):250-259.
 25. Pan F, Hua S, Ma Z. Surgical treatment of combined posterior root tears of the lateral meniscus and ACL tears. *Med Sci Monit.* 2015;21:1345-1349.
 26. Petersen W, Forkel P, Feucht MJ, Zantop T, Imhoff AB, Brucker PU. Posterior root tear of the medial and lateral meniscus. *Arch Orthop Trauma Surg.* 2014;134(2):237-255.
 27. Praz C, Vieira TD, Saithna A, et al. Risk factors for lateral meniscus posterior root tears in the anterior cruciate ligament-injured knee: an epidemiological analysis of 3956 patients from the SANTI Study Group. *Am J Sports Med.* 2019;47(3):598-605.
 28. Shumborski SJ, Salmon LJ, Monk CI, Pinczewski LA. Stable lateral meniscal posterior root tears left in situ at time of anterior cruciate ligament reconstruction are of minimal long-term clinical detriment. *Arthroscopy.* 2021;37(12):3500-3506.
 29. Shybut TB, Vega CE, Haddad J, et al. Effect of lateral meniscal root tear on the stability of the anterior cruciate ligament-deficient knee. *Am J Sports Med.* 2015;43(4):905-911.
 30. Tang X, Marshall B, Wang JH, et al. Lateral meniscal posterior root repair with anterior cruciate ligament reconstruction better restores knee stability. *Am J Sports Med.* 2019;47(1):59-65.
 31. Tsujii A, Yonetani Y, Kinugasa K, et al. Outcomes more than 2 years after meniscal repair for radial/flap tears of the posterior lateral meniscus combined with anterior cruciate ligament reconstruction. *Am J Sports Med.* 2019;47(12):2888-2894.
 32. Zheng T, Song G, Li Y, et al. Clinical, radiographic, and arthroscopic outcomes of surgical repair for radial and avulsed lesions on the lateral meniscus posterior root during ACL reconstruction: a systematic review. *Orthop J Sports Med.* 2021;9(3):2325967121989678.
 33. Zhuo H, Chen Q, Zhu F, Li J. Arthroscopic side-to-side repair for complete radial posterior lateral meniscus root tears. *BMC Musculoskelet Disord.* 2020;21(1):130.
 34. Zhuo H, Pan L, Xu Y, Li J. Functional, magnetic resonance imaging, and second-look arthroscopic outcomes after pullout repair for avulsion tears of the posterior lateral meniscus root. *Am J Sports Med.* 2021;49(2):450-458.