



**HAL**  
open science

## Fatal mucormycosis and aspergillosis coinfection associated with haemophagocytic lymphohistiocytosis: A case report and literature review

Dorian Loubet, Benjamine Sarton, Lucie Lelièvre, Gaspard Grouteau, Xavier Iriart, Pamela Chauvin, Judith Fillaux, Alexis Valentin, Antoine Berry, Stein Silva, et al.

### ► To cite this version:

Dorian Loubet, Benjamine Sarton, Lucie Lelièvre, Gaspard Grouteau, Xavier Iriart, et al.. Fatal mucormycosis and aspergillosis coinfection associated with haemophagocytic lymphohistiocytosis: A case report and literature review. *Journal of Medical Mycology = Journal de Mycologie Médicale*, 2022, 33 (1), pp.101325. 10.1016/j.mycmed.2022.101325 . hal-04726175

**HAL Id: hal-04726175**

**<https://ut3-toulouseinp.hal.science/hal-04726175v1>**


Submitted on 8 Oct 2024

**HAL** is a multi-disciplinary open access archive for the deposit and dissemination of scientific research documents, whether they are published or not. The documents may come from teaching and research institutions in France or abroad, or from public or private research centers.

L'archive ouverte pluridisciplinaire **HAL**, est destinée au dépôt et à la diffusion de documents scientifiques de niveau recherche, publiés ou non, émanant des établissements d'enseignement et de recherche français ou étrangers, des laboratoires publics ou privés.



Distributed under a Creative Commons Attribution - NonCommercial - NoDerivatives 4.0 International License



## Case report

# Fatal mucormycosis and aspergillosis coinfection associated with haemophagocytic lymphohistiocytosis: A case report and literature review

Dorian Loubet<sup>a</sup>, Benjamine Sarton<sup>b,c</sup>, Lucie Lelièvre<sup>d</sup>, Gaspard Grouteau<sup>d</sup>, Xavier Iriart<sup>a,f</sup>, Pamela Chauvin<sup>a</sup>, Judith Fillaux<sup>a</sup>, Alexis Valentin<sup>a,e</sup>, Antoine Berry<sup>a,f</sup>, Stein Silva<sup>b,c</sup>, Fabrice Bonneville<sup>g</sup>, Sophie Cassaing<sup>a,h</sup>, Emilie Guemas<sup>a,f,\*</sup>

<sup>a</sup> Department of Parasitology and Mycology, CHU Toulouse, Toulouse, France

<sup>b</sup> Critical Care Unit, University Hospital of Purpan, Toulouse, France

<sup>c</sup> Toulouse Neuroimaging Center, Unité Mixte de Recherche 1214, Institut National de la Santé et de la Recherche Médicale, Université Paul Sabatier, Toulouse, France

<sup>d</sup> Department of Infectious and Tropical Diseases, CHU Toulouse, Toulouse, France

<sup>e</sup> PHARMA-Dev, UMR 152 IRD-UPS, Université Toulouse, France

<sup>f</sup> Institut Toulousain des Maladies Infectieuses et Inflammatoires (Infinity), Université Toulouse, CNRS UMR5051, INSERM UMR1291, UPS, Toulouse, France

<sup>g</sup> Neuroradiology Department, Pierre-Paul-Riquet/Purpan University Hospital, Toulouse, France

<sup>h</sup> RESTORE Institute, UMR 1301-Inserm 5070-CNRS EFS Univ. P. Sabatier, Toulouse, France

## ARTICLE INFO

## Article History:

Received 24 January 2022

Revised 8 July 2022

Accepted 5 August 2022

Available online 8 August 2022

## Keywords:

Mucormycosis

Aspergillosis

Invasive fungal infection

Haemophagocytic lymphohistiocytosis

Varicella zoster virus

## ABSTRACT

Invasive mould infections are life-threatening and mainly occur in immunocompromised patients. Whereas aspergillosis is described during haemophagocytic lymphohistiocytosis (HLH), only a few cases of concomitant mucormycosis with HLH have been reported. Here, we present an uncommon coinfection of mucormycosis and aspergillosis associated with HLH probably due to a varicella zoster virus (VZV) viraemia which was unresponsive to triple antifungal therapy (liposomal amphotericin B combined with isavuconazole and caspofungin). A review of the cases of mucormycosis with HLH showed that this uncommon association was always lethal and underscored the relevance of screening for mould infections in patients with HLH.

© 2022 The Authors. Published by Elsevier Masson SAS on behalf of SFMM. This is an open access article under the CC BY-NC-ND license (<http://creativecommons.org/licenses/by-nc-nd/4.0/>)

## Introduction

Invasive mould infections (IMIs) are life-threatening and affect mainly immunocompromised patients. *Aspergillus* and Mucorales are the two most common agents responsible for mould infections. Mucormycosis, which is less common than aspergillosis, is a severe infection caused by ubiquitous filamentous fungi that belong to the order Mucorales. The most frequently encountered genera in human infections are *Rhizopus*, *Mucor*, *Lichtheimia* and *Rhizomucor*. Mucormycosis is a rapidly evolving lethal invasive infection with a high mortality rate, estimated between 32% and 70% [1]. Some of the main predisposing conditions include diabetes mellitus, haematological malignancy and solid organ transplantation. The clinical spectrum of

these infections is host-dependent: the rhino-orbital-cerebral (ROC) form is classically described in diabetic patients while the primitive pulmonary form is rather associated with haematological malignancy [2]. Cutaneous forms secondary to trauma happens regardless of the immune status.

Haemophagocytic lymphohistiocytosis (HLH), also known as haemophagocytic syndrome, was first described in 1939 by Scott and Robb-Smith [3] and is caused by a dysregulation in natural killer and cytotoxic T-cell function resulting in uncontrolled haemophagocytosis and cytokine storm. This syndrome can occur in the presence of a genetic predisposition and/or be triggered by malignancies, autoimmune diseases, or infections. It is a life-threatening disease with a high mortality rate of approximately 40% in adults [4].

*Aspergillus* infection has been suggested as rare trigger of HLH [5] but very few cases of mucormycosis associated with HLH have been reported [6–13]. Here, we describe the first case of mucormycosis and aspergillosis coinfection associated with HLH.

\* Corresponding author at: Service de Parasitologie – Mycologie, Hôpital Purpan – Institut Fédératif de Biologie (IFB), 330 avenue de Grande-Bretagne, TSA 40031, 31059 Toulouse cedex 9, France

E-mail address: [guemas.e@chu-toulouse.fr](mailto:guemas.e@chu-toulouse.fr) (E. Guemas).

## Case presentation

A 68-year-old man was admitted to intensive care unit (ICU) with acute respiratory distress, associated with fever (41 °C) and impaired consciousness. His medical history included arterial hypertension and he had been receiving treatment with corticosteroids for a herniated cervical disc syndrome for about a month (dose not specified).

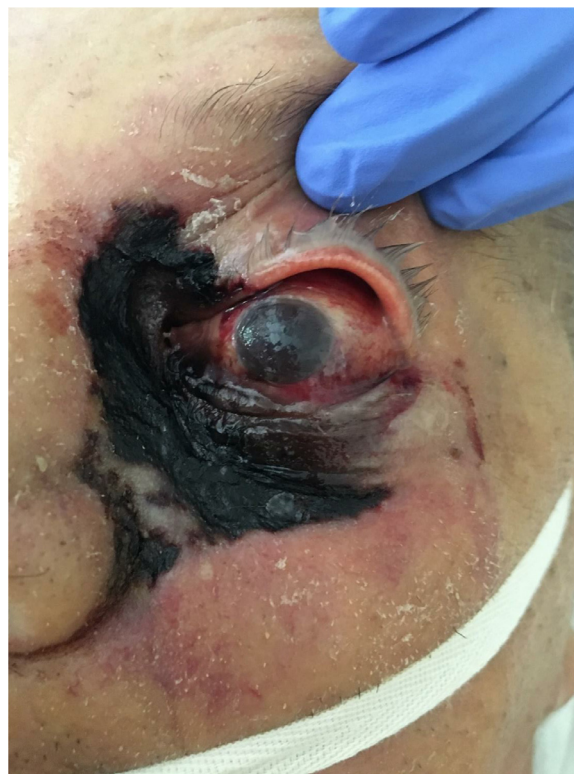On admission, day 1 (D1), he presented severe dyspnoea (SaO<sub>2</sub> 84%) and coma with a 5/15 score on the Glasgow coma scale (GCS). The initial skin examination showed a unilateral vesicular rash on the anterior side of the lower limb. Initial laboratory results showed uncompensated metabolic acidosis (pH 7.28, lactates 5.1 mmol/l; normal range (NR) 0.5 – 2.2 mmol/l); bicytopenia (platelets 31×10<sup>9</sup>/l; NR 150 – 450×10<sup>9</sup>/l, polymorphonuclear neutrophils 0.7 × 10<sup>9</sup>/l; NR 2 – 7.5 × 10<sup>9</sup>/l) and hyperglycaemia (11.4 mmol/l; NR 4.5 – 6.4 mmol/l). A SARS-CoV-2 reverse transcriptase-PCR (RT-PCR) test by a nasopharyngeal swab was negative. No tests were performed to rule out other respiratory viruses. Serologies for hepatitis A, C and human immunodeficiency virus (HIV) were negative and he had protective immunity against hepatitis B. Blood and cerebrospinal fluid (CSF) microbial cultures were negative. A chest computed tomography (CT) scan was performed and revealed aspecific bilateral consolidation. He was intubated and mechanically ventilated. Empirical broad-spectrum antibiotic treatment was started with piperacillin-tazobactam and rovamycin.

His clinical status rapidly evolved to multisystem organ failure with (i) severe haemodynamic shock requiring a high-dose noradrenaline and dobutamine infusion, (ii) severe respiratory failure with high oxygen requirements, (iii) acute hepatitis (aspartate aminotransferases 16,106 IU/l; NR < 50 IU/l), (iv) stage-3 acute kidney injury according to KDIGO guidelines [14], which required haemodialysis and (v) disseminated intravascular coagulopathy (platelets 24×10<sup>9</sup>/l, fibrinogen 1.1 g/l; NR 2 – 4 g/l, prothrombin time 22%; NR 70 – 100%, D-dimer > 4000 ng/ml; NR < 500 ng/ml).

The presence of fever, hyperferritinaemia (141,918 µg/l; NR 30 – 400 µg/l), hypertriglyceridaemia (2.56 mmol/l; NR 0.60 – 1.70 mmol/l), hypofibrinogenaemia (1.1 g/l) and pancytopenia (haemoglobin 8.9 g/dl; NR 13 – 17.5 g/dl, platelets 24×10<sup>9</sup>/l, polymorphonuclear neutrophils 0.7 × 10<sup>9</sup>/l), raised the suspicion of HLH. A myelogram showed the presence of haemophagocytosis. HLH was diagnosed with an Hscore of 99.6% (<http://saintantoine.aphp.fr/score/>) [15] and a combined corticosteroids-etoposide therapy was started on D2. Tocilizumab was initiated one day later (D3) due to poor clinical and biological outcomes [16]. Four days after treatment initiation (D6), the patient developed medullary aplasia for 14 days.

Exhaustive research for haematologic, autoimmune or infectious aetiology was investigated. Morphological and immunophenotypic flow cytometry analysis of the bone marrow excluded a lymphoid (B and T) malignancy. Karyotype analysis did not show any abnormality. There were no clinical and biological arguments for an autoimmune disease either. Microbiological investigations were negative except for varicella zoster virus (VZV) with a positive viraemia and a positive VZV-PCR on skin vesicle biopsy.

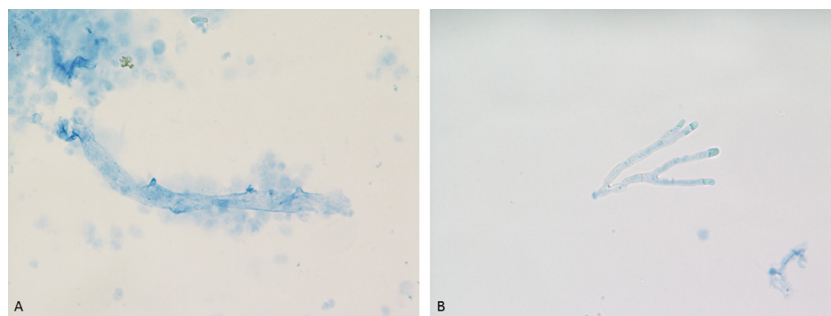
On D7, the patient developed acute respiratory distress syndrome (ARDS) associated with sepsis. *Enterococcus faecium* bacteraemia was treated with piperacillin-tazobactam and vancomycin. On D11, a chest CT scan showed pseudonodular areas in the right upper lobe which could suggested a fungal origin. Positive serum galactomannan (GM) occurred on D10 (0.82) and D15 (4.49) (Platelia *Aspergillus*; BioRad®). However, a bronchoalveolar lavage (BAL) on D10 remained negative on the direct fungal examination, culture and *Aspergillus* PCR [17]. The BAL was not tested for GM antigens. Antifungal therapy with voriconazole was nevertheless initiated on D12 (6 mg/kg intravenous on D12 followed by 4 mg/kg twice on the following days). Voriconazole therapeutic drug monitoring (TDM) 6 days after treatment initiation was adequate with a 5.11 mg/l residual plasma level.



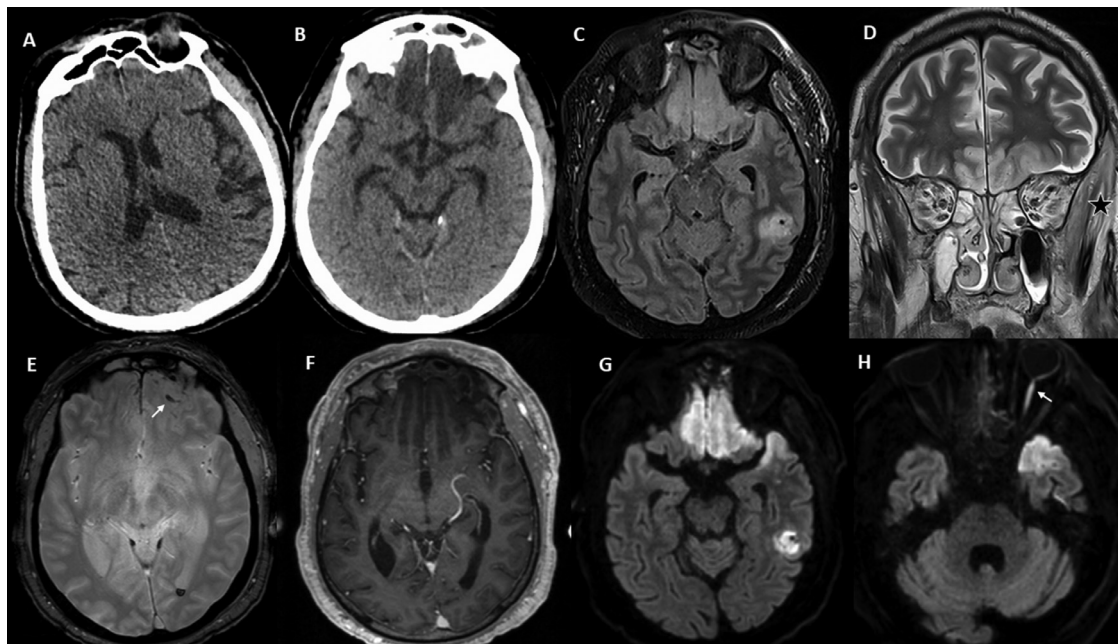
**Fig. 1.** Clinical presentation of unilateral necrotic lesion on internal canthus extended to left eye and nose on day-19.

On D19, a rapidly evolving unilateral necrotic lesion appeared on the internal canthus of the left eye (Fig. 1). Direct microscopy examination showed large and ribbon-like non-septate hyphae suggestive of Mucorales fungi. Similar fungal hyphae suggestive of Mucorales (Fig. 2A) associated with hyaline, septate hyphae with dichotomous branching suggestive of *Aspergillus* spp. (Fig. 2B) were observed in tracheal aspiration on D19. PCRs performed for Mucorales detection [18] were positive for the *Rhizomucor* genus and the *Mucor/Rhizopus* pair both in serum and tracheal aspiration while only the *Rhizomucor* PCR was positive in an ocular specimen. Fungal PCRs on tracheal aspiration were also positive for *Aspergillus*, while all Sabouraud agar cultures remained negative. PCRs in CSF were negative for both *Aspergillus* and Mucorales. Brain CT, performed D19, demonstrated bilateral hypodense lesions in the fronto-orbital regions and brain MRI showed restricted diffusion in the brain lesions, suggestive of acute cerebral infarction (Fig. 3). Chest CT scan (D19) showed an increase in pseudonodular condensation of the right upper lobe and appearance of several nodular lesions with peripheral ground glass (halo sign) suggestive of fungal infection such as aspergillosis. On D19, voriconazole was switched to liposomal amphotericin B and on D22, an antifungal salvage treatment was initiated with a combination therapy of liposomal amphotericin B (5 mg/kg), isavuconazole and caspofungin.

On D24, Mucorales PCR performed in serum were negative for *Rhizomucor* genus and still positive for *Mucor/Rhizopus*. On D24, a new CT scan showed worsening of chest and cerebral lesions. Chest CT scan revealed an increase in the size of the multiple areas of pseudonodular condensation, some with a ground glass halo and others with reverse halo sign, suggestive of mucormycosis (Fig. 4). Due to the extensive involvement of the facial bone with damage to the ethmoid, sphenoid, and both maxillary sinuses, surgery within healthy margins was not considered feasible. A decision was made by the team to administer palliative care and the patient died on D26. Retrospectively, we performed Mucorales PCR on

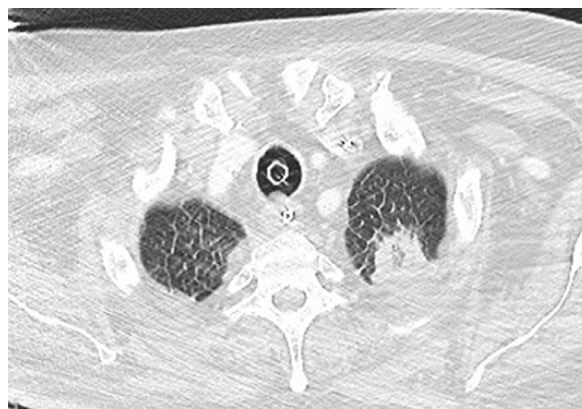


**Fig. 2.** Direct microscopic examination of respiratory sample (x400) with lactophenol blue showing (A) large non-septate hyphae suggestive of Mucorales and (B) septate hyphae suggestive of *Aspergillus*.



**Fig. 3.** 68-year-old man with severe brain infection. (A) Unenhanced brain CT was normal on admission. (B) Clinical worsening on day-19. Brain CT demonstrated bilateral hypodense lesions in the fronto-orbital regions. (C–H) Subsequent brain MRI on the same day depicted additional left temporal lobe lesions on (C) Fluid-Attenuated Inversion Recovery image, and infiltration in the left temporal fossa (black star) on (D) coronal T2-weighted image. (E) An axial gradient echo T2\*-weighted image revealed multiple foci of hypo-intensity (short arrow) suggestive of blood products, confirming the aggressiveness of brain lesions, although no enhancement was observed on (F) the post-gadolinium T1-weighted image. (G) and (H) Diffusion-weighted images showed restricted diffusion in the brain lesions, suggestive of acute cerebral infarction, but also in the left optic nerve (short arrow).

earlier samples (BAL and serum). PCR in BAL on D9 was negative for Mucorales. In serum, the first positive Mucorales PCR was on D15. These findings suggest that *Aspergillus* infection occurred before mucormycosis.



**Fig. 4.** Chest CT demonstrated consolidation with reverse halo sign in left upper lobe on day-24.

### Discussion

We reported a case of fatal mucormycosis with both pulmonary and ROC lesions associated with pulmonary aspergillosis. The patient had predisposing factors for both mucormycosis and aspergillosis such as neutropenia, corticosteroids use for a herniated cervical disc and immunosuppressive treatment for HLH [2,19]. Although he had no previous diagnosis of diabetes mellitus, a well-known predisposing factor for mucormycosis [2], his glycaemia levels were high on admission. Haematological malignancy was ruled out.

HLH can be primary (genetic) or secondary (reactive), in which case it is associated with autoimmune diseases, neoplasia or infections, especially those caused by viruses. Epstein-Barr virus (EBV) is the most frequent trigger virus (43%) [4], but other Herpes viruses (herpes simplex virus, cytomegalovirus, human herpes viruses 6 and 8 and VZV) have also been associated with HLH [5]. Fungi are rare triggers of HLH. *Histoplasma* is the most frequently described [4] followed by other fungi such as *Candida*, *Cryptococcus*, *Aspergillus*, *Fusarium* and *Pneumocystis* [5]. On the other hand, aspergillosis can be a complication of HLH. In a cohort of 71 HLH patients admitted to the ICU, invasive aspergillosis complicated the disease in 25% of patients [20]. In our case, aspergillosis seemed to be more a consequence of

**Table 1**  
Reported cases of mucormycosis associated with haemophagocytic lymphohistiocytosis (HLH).

	Case 1 [6]	Case 2 [7]	Case 3 [8]	Case 4 [9]	Case 5 [10]	Case 6 [11]	Case 7 [12]	Case 8 [13]	Presented case
Age / gender	23 / m	2 / f	32 / m	13 / f	22 / f	12 / f	7 mo / m	23 / m	68 / m
Underlying disease	Lymphoma	None	None	Diabetes	None	EBV hepatitis	Unknown	None	Unknown
Pancytopenia	Yes*	Yes*	Yes*	Yes	Yes*	Yes*	Yes*	Yes*	Yes*
Hyperferritinaemia	Yes*	Yes*	Yes*	Unknown	Yes*	Yes*	Yes*	Yes*	Yes*
HLH suspected	Lymphoma + EBV	Not found	Not found Mm?	Not found Mm?	EBV	EBV	Not found Mm?	Familial HLH	VZV
HLH aetiology									
HLH treatment	Steroids/ cyclosporin/ etoposide, then ESHAP, then CHOP	Steroids	Steroids/ cyclosporin/ etoposide	Steroids	Steroids/ etoposide/ phos phamide	Steroids/ etoposide	None	Steroids/IC/ cyclosporin/ Eto- posid/ MSC therapy	Steroids/ etoposide/ tocilizumab
Mm clinical form	Pulmonary	Sinusitis (ethmoidal and maxillary)	Disseminated (lung, kidney and digestive)	ROC	Pulmonary	Disseminated	Pulmonary	Disseminated	Disseminated (lung and ROC)
Mm diagnosis	PM	D30	PM	D2	PM	PM	PM	Unknown	D18
Antifungal treatment	FCZ/MIC then AMB	FCZ/AMB	None	AMB	FCZ	None	None	Unknown	VCZ then ICZ/AMB/ CAS
Outcome	Fatal	Fatal	Fatal	Fatal	Fatal	Fatal	Fatal	Fatal	Fatal
Death date**	D28	D50	D7	D22	D35	D11	D3	Unknown	D26

AMB: amphotericin B; CAS: caspofungin; CHOP: cyclophosphamide, doxorubicin, vincristine and prednisolone; D: days; EBV: Epstein-Barr virus; ESHAP: etoposide, cisplatin, methyprednisolone and cytarabine; f: female; FCZ: fluconazole; HLH: haemophagocytic lymphohistiocytosis; ICZ: isavuconazole; IC: immunoglobulin; m: male; MIC: micafungin; Mm: mucormycosis; mo: months; MSC: mesenchymal stromal cells; PM: post-mortem; ROC: rhino-orbito-cerebral; VZV: varicella zoster virus; \*, abnormality present before diagnosis of mucormycosis, \*\*, date is referring to the hospitalisation.

HLH. Indeed, ARDS and first positive aspergillosis marker (serum GM) occurred five and eight days after HLH diagnosis, respectively.

Mucormycosis is not usually mentioned, neither as an HLH trigger, nor as a complication. Nevertheless, a review of the English and French language in Avril 2022 in the PubMed database using search term “mucormycosis AND hemophagocytic syndrome” identified eight cases of mucormycosis associated with concomitant HLH (Table 1) [6–13]. The clinical manifestations of mucormycosis were pulmonary, disseminated and ROC infections. There was no gender or age specificity. There was a post-mortem diagnosis of mucormycosis for five patients. One case was a familial HLH and EBV infection was suspected to be the HLH trigger for three patients. HLH aetiology was not identified in four patients. As with aspergillosis, the relation between HLH and mucormycosis remains unclear. In some cases, mucormycosis seemed to trigger HLH whereas for other patients HLH preceded mucormycosis (as in our own case). All patients died within 2 to 50 days after hospitalisation. In all the cases described, the patients had pancytopenia during hospitalisation. Except for one patient [9], pancytopenia was present before the diagnosis of mucormycosis. Neutropenia caused by both HLH and its treatments, is a well-known predisposing factor for mucormycosis [2] and is associated with mortality [21]. A high serum-ferritin concentration, found in 90% of the patients with HLH [4], is also associated with mortality in patients with mucormycosis [21]. Hyperferritinaemia may increase the risk of mucormycosis, although this has not been formally demonstrated [22].

Early diagnosis of IMIs is crucial to improve patient outcome, but these infections are difficult to diagnose. Actually, fungal culture sensitivity is as low as 20 to 50% [23,24]. In our case, the first biological argument for mucormycosis was a positive direct examination of ocular samples on D19. Unfortunately, infections due to Mucorales fungi cannot be detected via galactomannan assays and rarely via beta-D-glucan assays. For aspergillosis, the first biological marker was a positive galactomannan in serum on D10. All fungal cultures remained negative for both Mucorales and *Aspergillus*. These results highlighted the need to associate various techniques such as direct examination, culture, PCR and antigen detection.

On imaging, pulmonary mucormycosis and aspergillosis can have a nonspecific appearance and similar lesions such as peribronchial ground-glass opacity, consolidation, nodules, or masses. In our case, lung imaging was in favour of a coinfection of aspergillosis and mucormycosis, a hypothesis supported by positive biological markers (GM, direct microscopy examination of pulmonary samples and specific PCRs). The reverse halo sign, closely associated (but not absolutely specific [25]) with pulmonary mucormycosis, occurs in 19% to 94% of patients [26]. The underlying disease and the presence of neutropenia may explain the wide range in the reported frequency of the reverse halo sign. In our case, this sign appeared on D24, i.e. 7 days after the diagnosis by PCR.

In conclusion IMIs during HLH are life-threatening and the uncommon association of mucormycosis and HLH was lethal in all reported cases, despite appropriate treatment. Our case suggests that non-invasive tests for fungal biomarkers should be included in the diagnostic workup for patients with HLH suspected of infections in order to optimize an early management.

**Declaration of Competing Interest**

The authors have no conflict of interest.

**References**

[1] Serris A, Danion F, Lantermier F. Disease entities in mucormycosis. J Fungi Basel Switz 2019;5(1):E23. doi: 10.3390/jof5010023.  
 [2] Jeong W, et al. The epidemiology and clinical manifestations of mucormycosis: a systematic review and meta-analysis of case reports. Clin Microbiol Infect 2019;25(1):26–34. doi: 10.1016/j.cmi.2018.07.011.

- [3] Scott RB, Robb-Smith AHT. Histiocytic medullary reticulosis. *Lancet* 1939;234(6047):194–8. doi: [10.1016/S0140-6736\(00\)61951-7](https://doi.org/10.1016/S0140-6736(00)61951-7).
- [4] Ramos-Casals M, Brito-Zerón P, López-Guillermo A, Khamashta MA, Bosch X. Adult haemophagocytic syndrome. *Lancet* 2014;383(9927):1503–16. doi: [10.1016/S0140-6736\(13\)61048-X](https://doi.org/10.1016/S0140-6736(13)61048-X).
- [5] Roupheal NG, Talati NJ, Vaughan C, Cunningham K, Moreira R, Gould C. Infections associated with haemophagocytic syndrome. *Lancet Infect Dis* 2007;7(12):814–22. doi: [10.1016/S1473-3099\(07\)70290-6](https://doi.org/10.1016/S1473-3099(07)70290-6).
- [6] Inagaki N, et al. Disseminated Mucor infection and thrombotic microangiopathy in lymphoma-associated hemophagocytic syndrome. *Int J Hematol* 2008;88(3):355–6. doi: [10.1007/s12185-008-0156-6](https://doi.org/10.1007/s12185-008-0156-6).
- [7] Abilkassem R, Dini N, En-Nouali H, Lemkhente Z, Agadr A, Lmimouni B. Rhinofacial mucormycosis: a case report. *J Mycol Med* 2011;21(1):51–4. doi: [10.1016/j.mycmed.2010.11.008](https://doi.org/10.1016/j.mycmed.2010.11.008).
- [8] Arena V, et al. Haemophagocytic syndrome associated with mucormycosis infection. *Int J Immunopathol Pharmacol* 2012;25(3):751–5. doi: [10.1177/039463201202500321](https://doi.org/10.1177/039463201202500321).
- [9] Bahloul M, et al. Rhinocerebral mucormycosis complicated by hemophagocytic lymphohistiocytosis: case report from Tunisia. *Med Sante Trop* 2012;22(2):210–2. doi: [10.1684/mst.2012.0049](https://doi.org/10.1684/mst.2012.0049).
- [10] Hirayama Y, et al. Disseminated infection and pulmonary embolization of *Cunninghamella bertholletiae* complicated with hemophagocytic lymphohistiocytosis. *Intern Med Tokyo Jpn* 2013;52(19):2275–9. doi: [10.2169/internalmedicine.52.0171](https://doi.org/10.2169/internalmedicine.52.0171).
- [11] Dien Bard J, Mangahis A, Hofstra TC, Bender JM. First case report of bloodstream infection by *Rhizomucor pusillus* in a child with hemophagocytic lymphohistiocytosis. *Med Mycol Case Rep* 2014;5:20–3. doi: [10.1016/j.mmcr.2014.05.002](https://doi.org/10.1016/j.mmcr.2014.05.002).
- [12] Bhattacharya D, Iyer R, Nallasamy K, Vaiphei K. Haemophagocytic lymphohistiocytosis with pulmonary mucormycosis: fatal association. *BMJ Case Rep* 2019;12(5):e230587. doi: [10.1136/bcr-2019-230587](https://doi.org/10.1136/bcr-2019-230587).
- [13] Mougiakakos D, et al. Treatment of familial hemophagocytic lymphohistiocytosis with third-party mesenchymal stromal cells. *Stem Cells Dev Nov*. 2012;21(17):3147–51. doi: [10.1089/scd.2012.0214](https://doi.org/10.1089/scd.2012.0214).
- [14] Khwaja A. KDIGO clinical practice guidelines for acute kidney injury. *Nephron Clin Pract* 2012;120(4):c179–84. doi: [10.1159/000339789](https://doi.org/10.1159/000339789).
- [15] Fardet L, et al. Development and validation of the HScore, a score for the diagnosis of reactive hemophagocytic syndrome. *Arthritis Rheumatol Hoboken NJ* 2014;66(9):2613–20. doi: [10.1002/art.38690](https://doi.org/10.1002/art.38690).
- [16] Dufranc E, Del Bello A, Belliere J, Kamar N, Faguer S, TAIDI (Toulouse Acquired Immune Deficiency and Infection) study group. IL6-R blocking with tocilizumab in critically ill patients with hemophagocytic syndrome. *Crit Care Lond Engl* 2020;24(1):166. doi: [10.1186/s13054-020-02878-7](https://doi.org/10.1186/s13054-020-02878-7).
- [17] Costa C, Costa J-M, Desterke C, Botterel F, Cordonnier C, Bretagne S. Real-time PCR coupled with automated DNA extraction and detection of galactomannan antigen in serum by enzyme-linked immunosorbent assay for diagnosis of invasive aspergillosis. *J Clin Microbiol* 2002;40(6):2224–7. doi: [10.1128/JCM.40.6.2224-2227.2002](https://doi.org/10.1128/JCM.40.6.2224-2227.2002).
- [18] Millon L, et al. Early diagnosis and monitoring of mucormycosis by detection of circulating DNA in serum: retrospective analysis of 44 cases collected through the French Surveillance Network of Invasive Fungal Infections (RESSIF). *Clin Microbiol Infect* 2016;22(9):810.e1–810.e8. doi: [10.1016/j.cmi.2015.12.006](https://doi.org/10.1016/j.cmi.2015.12.006).
- [19] Donnelly JP, et al. Revision and update of the consensus definitions of invasive fungal disease from the European organization for research and treatment of cancer and the mycoses study group education and research consortium. *Clin Infect Dis Off Publ Infect Dis Soc Am* 2020;71(6):1367–76. doi: [10.1093/cid/ciz1008](https://doi.org/10.1093/cid/ciz1008).
- [20] Barba T, et al. Hemophagocytic lymphohistiocytosis in intensive care unit: a 71-case stroke-compliant retrospective study. *Medicine* 2015;94(51):e2318. doi: [10.1097/MD.0000000000002318](https://doi.org/10.1097/MD.0000000000002318).
- [21] Spellberg B, et al. Risk factors for mortality in patients with mucormycosis. *Med Mycol* 2012;50(6):611–8. doi: [10.3109/13693786.2012.669502](https://doi.org/10.3109/13693786.2012.669502).
- [22] Narayanan S, Chua JV, Baddley JW. COVID-19 associated mucormycosis (CAM): risk factors and mechanisms of disease. *Clin Infect Dis* 2021 ciab726. doi: [10.1093/cid/ciab726](https://doi.org/10.1093/cid/ciab726).
- [23] Scherer E, et al. Quantitative PCR (qPCR) detection of mucorales DNA in bronchoalveolar lavage fluid to diagnose pulmonary mucormycosis. *J Clin Microbiol* 2018;56(8):e00289–18. doi: [10.1128/JCM.00289-18](https://doi.org/10.1128/JCM.00289-18).
- [24] Arvanitis M, Anagnostou T, Fuchs BB, Caliendo AM, Mylonakis E. Molecular and nonmolecular diagnostic methods for invasive fungal infections. *Clin Microbiol Rev* 2014;27(3):490–526. doi: [10.1128/CMR.00091-13](https://doi.org/10.1128/CMR.00091-13).
- [25] Thomas R, Madan R, Gooptu M, Hatabu H, Hammer MM. Significance of the reverse halo sign in immunocompromised patients. *Am J Roentgenol* 2019;213(3):549–54. doi: [10.2214/AJR.19.21273](https://doi.org/10.2214/AJR.19.21273).
- [26] Agrawal R, Yeldandi A, Savas H, Parekh ND, Lombardi PJ, Hart EM. Pulmonary mucormycosis: risk factors, radiologic findings, and pathologic correlation. *Radiographics* 2020;40(3):656–66. doi: [10.1148/rg.2020190156](https://doi.org/10.1148/rg.2020190156).