



**HAL**  
open science

## A Causal Classification System for Intracerebral Hemorrhage Subtypes

Nicolas Raposo, Maria Clara Zanon Zotin, David J Seiffge, Qi Li, Martina B Goeldlin, Andreas Charidimou, Ashkan Shoamanesh, Hans Rolf Jäger, Charlotte Cordonnier, Catharina Jm Klijn, et al.

► **To cite this version:**

Nicolas Raposo, Maria Clara Zanon Zotin, David J Seiffge, Qi Li, Martina B Goeldlin, et al.. A Causal Classification System for Intracerebral Hemorrhage Subtypes. *Annals of Neurology*, 2023, 93 (1), pp.16-28. 10.1002/ana.26519 . hal-04717307

**HAL Id: hal-04717307**

**<https://ut3-toulouseinp.hal.science/hal-04717307v1>**

Submitted on 1 Oct 2024


**HAL** is a multi-disciplinary open access archive for the deposit and dissemination of scientific research documents, whether they are published or not. The documents may come from teaching and research institutions in France or abroad, or from public or private research centers.

L'archive ouverte pluridisciplinaire **HAL**, est destinée au dépôt et à la diffusion de documents scientifiques de niveau recherche, publiés ou non, émanant des établissements d'enseignement et de recherche français ou étrangers, des laboratoires publics ou privés.



Distributed under a Creative Commons Attribution - NonCommercial - NoDerivatives 4.0 International License

# A Causal Classification System for Intracerebral Hemorrhage Subtypes

Nicolas Raposo, MD, PhD <sup>1,2</sup> Maria Clara Zanon Zotin, MD,<sup>3,4</sup> David J. Seiffge, MD <sup>5</sup>  
 Qi Li, MD, PhD <sup>6</sup> Martina B. Goeldlin, MD,<sup>5,7</sup> Andreas Charidimou, MD, PhD,<sup>3</sup>  
 Ashkan Shoamanesh, MD <sup>8</sup> Hans Rolf Jäger, MD, FRCP,<sup>9</sup>  
 Charlotte Cordonnier, MD, PhD,<sup>10</sup> Catharina JM Klijn, MD, PhD <sup>11</sup>  
 Eric E. Smith, MD, MPH,<sup>12</sup> Steven M. Greenberg, MD, PhD,<sup>3</sup> David J. Werring, MD, PhD,<sup>9</sup>  
 and Anand Viswanathan, MD, PhD<sup>3</sup>

**Objective:** Determining the underlying causes of intracerebral hemorrhage (ICH) is of major importance, because risk factors, prognosis, and management differ by ICH subtype. We developed a new causal CLASsification system for ICH Subtypes, termed CLAS-ICH, based on recent advances in neuroimaging.

**Methods:** CLAS-ICH defines 5 ICH subtypes: arteriolosclerosis, cerebral amyloid angiopathy, mixed small vessel disease (SVD), other rare forms of SVD (genetic SVD and others), and secondary causes (macrovascular causes, tumor, and other rare causes). Every patient is scored in each category according to the level of diagnostic evidence: (1) well-defined ICH subtype; (2) possible underlying disease; and (0) no evidence of the disease. We evaluated CLAS-ICH in a derivation cohort of 113 patients with ICH from Massachusetts General Hospital, Boston, USA, and in a derivation cohort of 203 patients from Inselspital, Bern, Switzerland.

**Results:** In the derivation cohort, a well-defined ICH subtype could be identified in 74 (65.5%) patients, including 24 (21.2%) with arteriolosclerosis, 23 (20.4%) with cerebral amyloid angiopathy, 18 (15.9%) with mixed SVD, and 9 (8.0%) with a secondary cause. One or more possible causes were identified in 42 (37.2%) patients. Interobserver agreement was excellent for each category (kappa value ranging from 0.86 to 1.00). Despite substantial differences in imaging modalities, we obtained similar results in the validation cohort.

**Interpretation:** CLAS-ICH is a simple and reliable classification system for ICH subtyping, that captures overlap between causes and the level of diagnostic evidence. CLAS-ICH may guide clinicians to identify ICH causes, and improve ICH classification in multicenter studies.

ANN NEUROL 2023;93:16–28

View this article online at [wileyonlinelibrary.com](https://www.wileyonlinelibrary.com). DOI: 10.1002/ana.26519

Received Mar 3, 2022, and in revised form Sep 30, 2022. Accepted for publication Oct 3, 2022.

Address correspondence to Dr Raposo, Service de Neurologie, Hôpital Pierre-Paul Riquet, Centre Hospitalier Universitaire de Toulouse, Place Baylac, 31059 Toulouse Cedex 9, France. E-mail: [raposo.n@chu-toulouse.fr](mailto:raposo.n@chu-toulouse.fr)

From the <sup>1</sup>Department of Neurology, Toulouse University Hospital, Toulouse, France; <sup>2</sup>Toulouse NeuroImaging Center, Toulouse University, Toulouse, France; <sup>3</sup>Stroke Research Center, Massachusetts General Hospital, Harvard Medical School, Boston, Massachusetts, USA; <sup>4</sup>Center for Imaging Sciences and Medical Physics, Department of Medical Imaging, Hematology and Clinical Oncology, Ribeirão Preto Medical School, University of São Paulo, São Paulo, Brazil; <sup>5</sup>Department of Neurology, Inselspital, Bern University Hospital, University of Bern, Bern, Switzerland; <sup>6</sup>Department of Neurology, The First Affiliated Hospital of Chongqing Medical University, Chongqing, China; <sup>7</sup>Graduate School for Health Sciences, University of Bern, Bern, Switzerland; <sup>8</sup>Division of Neurology, Population Health Research Institute, McMaster University, Hamilton, Ontario, Canada; <sup>9</sup>Stroke Research Centre, Department of Brain Repair and Rehabilitation, UCL Queen Square Institute of Neurology, London, UK; <sup>10</sup>Univ. Lille, Inserm, CHU Lille, U1172–LiNCog–Lille Neuroscience & Cognition, Lille, France; <sup>11</sup>Department of Neurology, Donders Institute for Brain, Cognition and Behavior, Radboud University Medical Center, Nijmegen, the Netherlands; and <sup>12</sup>Department of Clinical Neurosciences, Hotchkiss Brain Institute, University of Calgary, Calgary, Alberta, Canada

## Introduction

Spontaneous (ie, nontraumatic) intracerebral hemorrhage (ICH), affecting >3 million people worldwide each year,<sup>1</sup> is the most severe stroke subtype with a high risk of death,<sup>2</sup> dependence,<sup>3</sup> and dementia.<sup>4,5</sup> ICH is a heterogeneous cerebrovascular disease with a diverse range of conditions and >30 known potential causes.<sup>6,7</sup> Determining underlying causes of ICH is of major importance, because risk factors, mechanisms, prognosis, and management differ by ICH subtype.

Etiological classification systems have been shown to be useful for patients with ischemic stroke in clinical routine practice (enabling individualized stroke risk estimation and targeted treatment regimens based on the stroke subtype), as well as in clinical research (well-phenotyped cohorts for epidemiological studies and clinical trials).<sup>8–10</sup> Subtyping ICH must face many challenges, including lack of standardized etiological work-up, variable levels of diagnostic certainty, and possible co-occurrence of multiple causes. To date, there is no consensus on the optimal causal classification system for ICH subtypes, although a few algorithms for classifying ICH causes have been previously proposed.<sup>11,12</sup>

In the current study, we aimed to develop a causal CLASsification system for ICH Subtypes (CLAS-ICH), based on the most recent advances in neuroimaging, ICH epidemiology, and cerebral small vessel disease (SVD) phenotyping, defining ICH subgroups with presumed similar pathogenesis and prognosis, with potential clinical relevance for specific acute and preventive management strategies. We sought to design a classification system that may guide clinicians in determining the underlying cause of ICH and in providing urgent specific care. At the same time, the classification tool can be useful for researchers in defining well-phenotyped ICH subtypes for epidemiological and clinical studies.

## Methods

In 2019, we drafted a proposal that aimed to develop a novel causal classification system for ICH subtypes. We invited experts from various countries in Europe, America, and Asia to participate in an international collaborative effort. Our core group included experts in neurology, stroke, neuroimaging, neuroepidemiology, cerebral SVD, and ICH. We critically reviewed pre-existing causal ICH classification systems in the context of the most recent advances in ICH epidemiology and neuroimaging. We searched PubMed without language restriction for publications regarding causal ICH classification systems published from inception up to June 10, 2019. We used the search terms “intracerebral hemorrhage” or “intracranial hemorrhage”

AND “cause” or “etiology” AND “classification” or “system” or “classification system.” Based on the strengths and weakness of previous systems, we identified key principles and developed a new classification system for ICH subtypes, through call meetings. We provided clinical and imaging clues to guide etiologic investigations. We tested the interobserver reliability of the classification system in a single-center cohort of consecutive patients with acute spontaneous ICH.

## Rationale for a New ICH Subtype Classification System

Spontaneous ICH have numerous potential causes, most often cerebral SVD and macrovascular structural lesions.<sup>6,7</sup> As there is no consensus on an etiologic classification system,<sup>13</sup> the prevalence of each ICH cause remains uncertain. Spontaneous ICH are usually categorized as: (1) primary ICH when ICH is caused by the rupture of small brain vessels damaged by different forms of SVD, or (2) secondary ICH when the bleeding is caused by structural brain vascular malformation, brain tumor, inherent coagulopathy, or other rare diseases.<sup>14</sup> It is widely accepted that SVD are the main causes, accounting for approximately 80% of spontaneous ICH.<sup>6,7</sup> This large ICH subgroup includes mainly two sporadic age-related SVDs: arteriolosclerosis – also called hypertensive angiopathy or deep perforator arteriopathy – and sporadic cerebral amyloid angiopathy (CAA).<sup>15,16</sup> Other rare forms comprise inherited (such as familial CAA, CADASIL, or COL4A1 mutations) and infrequent sporadic SVD (post-radiation angiopathy).<sup>17</sup> Secondary causes account for approximately 20% of spontaneous ICH, even if this proportion may vary according to the study population. A macrovascular structural lesion, such as arteriovenous malformation, dural arteriovenous fistula, or cerebral cavernous malformation, has been reported in 15 to 23% of adults with ICH,<sup>18–20</sup> and brain tumors in <5%.<sup>21</sup> Other various ICH causes (cerebral venous thrombosis, reversible cerebral vasoconstriction syndrome, posterior reversible encephalopathy syndrome, moyamoya, etc.) occur more rarely.

To date, a few anatomical ICH classification systems have been proposed,<sup>22</sup> and just two causal ICH classification systems have been previously published. The SMASH-U classification system was proposed in 2012 to provide a simple and practical clinical classification for the etiology of ICH.<sup>11</sup> The authors used a retrospective registry of consecutive patients ( $n = 1,013$ ) with ICH from the Helsinki University Central Hospital to apply the etiologic classification system. An elimination strategy algorithm was used to assign one exclusive ICH cause among the following 6 categories: structural lesion (S), medication

(M), amyloid angiopathy (A), systemic/other disease (S), hypertension (H), undetermined (U).

A second classification system, named H-ATOMIC, has been more recently developed and applied in a prospective multicenter cohort study in Spain ( $n = 439$ ).<sup>12</sup> H-ATOMIC includes 7 ICH categories: arterial hypertension (H), cerebral amyloid angiopathy (A), tumor (T), oral anticoagulants (O), arterio-venous malformations and cavernoma (M), infrequent causes (I), and cryptogenic (C). The rater scores each category according to the degree of diagnostic certainty: (1) Definite, (2) Probable, and (3) Possible. Strengths and weakness of each classification system are summarized in Table 1.

**A Novel Causal Classification System for ICH**

**Subtypes: CLAS-ICH**

**Key Principles for the Classification System.** First, the new classification system is an imaging-based classification for

ICH etiology (or etiologies) using validated neuroimaging biomarkers of small vessel and macrovascular pathologies rather than risk factors. Oral anticoagulants are considered as an important risk factor for ICH, but not as a direct cause.<sup>23,24</sup>

Second, the new classification is a comprehensive classification system that applies to all subtypes of spontaneous (ie, nontraumatic) ICH, that must be distinguished from ischemic stroke (brain imaging) and traumatic ICH (major head trauma <24 h of symptom onset causing loss of consciousness and thought to be sufficient to have caused the intracerebral bleeding).

Third, ICH subgroups of the classification system include the main known causes of ICH, and recognize that SVD and structural macrovascular lesions are predominant causes.

Fourth, ICH subgroups of the classification system are based on the premise that pathogenesis, prognosis, or

**TABLE 1. Characteristics of Previous Intracerebral Hemorrhage Classification Systems**

	SMASH-U	H-ATOMIC
Minimum etiologic work-up	Not described	Non-contrast head CT (MRI is an acceptable alternative) Blood tests Electrocardiogram and chest radiography CT-angio or other angiographic modalities (when SICH score >2)
Decision algorithm to assign ICH cause(s)	Elimination strategy  Only 1 cause is allowed  In case of multiple cause, the rater should select the most likely cause	More flexible strategy grading each ICH category  Allowing (theoretically) multiple causes  But an alternative cause is excluded in most definite causes
Criteria for each ICH category	Some ICH subgroups are based on validated imaging markers Others are based on risk factors which are not true causes (hypertension, anticoagulant use)	Some ICH subgroups are based on validated imaging markers Others are based on risk factors which are not true causes (hypertension, anticoagulant use)
Level of diagnostic evidence	Not captured	Diagnostic certainty is graded as: (1) definite (2) probable (3) possible
Interobserver reliability	Very good ( $\kappa = 0.89$ )	Good ( $\kappa = 0.76$ )
Easy and fast to apply	+++	-

Abbreviations: CT = computed tomography; ICG = intracerebral hemorrhage; SICH score = Secondary Intracerebral Hemorrhage score (ranging from 0 to 6).<sup>36</sup>

both, differ by ICH subtypes, and might thus affect the management strategies.

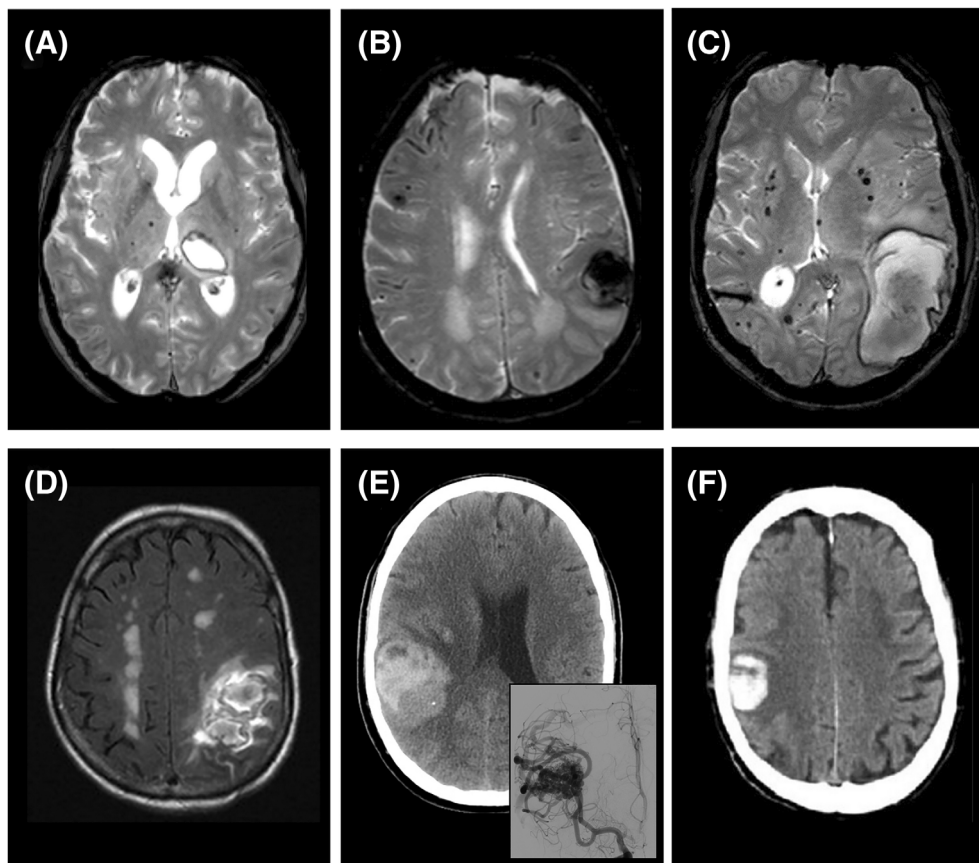
Fifth, the classification system recognizes that patients can have multiple potential causes of ICH, particularly presumed “mixed” small vessel disease (ie, potential arteriosclerosis/CAA combination). Instead of selecting only the single most likely cause of ICH (which may be subject to interpretation), the classification system should also allow overlap between ICH subtypes.

Sixth, when identifying ICH subtype, the level of diagnostic certainty might be affected by different factors, including etiologic work-up completeness, imaging parameters, and image quality. Neuroimaging investigation modalities (e.g. computed tomography [CT] vs magnetic resonance imaging [MRI]) for evaluating ICH may also vary across centers and countries. The classification system

should capture the level of diagnostic evidence and the work-up quality.

**ICH Subtypes of CLAS-ICH.** The new classification system – termed CLAS-ICH (Causal CLASsification system for ICH Subtypes) – defines 5 ICH subtypes, representative of the main causes of spontaneous ICH (Fig. 1 & Table 2A and 2B). These 5 ICH categories include: (A) arteriosclerosis, (C) cerebral amyloid angiopathy, (M) mixed cerebral small vessel diseases, (O) other rare forms of cerebral small vessel disease, and (S) secondary causes (Table 3).

**Level of Diagnostic Evidence and Evaluation of Work-Up Quality.** Every patient is scored in each of the main ICH categories according to the level of diagnostic evidence: (1) well-defined ICH subtype; (2) possible underlying



**FIGURE 1:** Examples of intracerebral hemorrhage (ICH) subtyping using CLASification system for ICH Subtypes (CLAS-ICH) system. (A–C) Axial T2\*-weighted gradient recalled echo and (D) fluid-attenuated inversion recovery magnetic resonance imaging sequences. (E, F) Axial non-contrast computed tomography. Every patient is scored in each ICH subgroup (arteriosclerosis [A], cerebral amyloid angiopathy [C], mixed small vessel disease [M], other form of small vessel disease [O], secondary cause [S]) according to the level of diagnostic evidence: (1) well-defined ICH subtype; (2) possible underlying disease; and (0) absence of evidence of the disease that may have caused ICH. (A) Deep left thalamic ICH with multiple strictly deep microbleeds (A1 C0 M0 O0 S0). (B) Left lobar ICH with multiple strictly lobar microbleeds and disseminated cortical superficial siderosis (A0 C1 M0 O0 S0). (C) Left lobar ICH with multiple hemorrhages (microbleeds and ICH) located both in lobar and deep regions of the brain (A0 C0 M1 O0 S0), (D) Single (ie, without other hemorrhage) left lobar ICH with confluent white matter hyperintensities in a 68-year-old man, and normal magnetic resonance angiography (A0 C2 M2 O0 S0). (E) Right lobar ICH with underlying arteriovenous malformation (A0 C0 M0 O0 S1). (F) Right lobar ICH without evidence of small vessel disease on computed tomography and normal computed tomography angiography in a 72-year-old woman (A0 C2 M0 O0 S2).

TABLE 2A. CLASSification System for ICH Subtypes System

**(A) Arteriosclerosis**

A1- Well-defined ICH subtype	(a) Pathologically-proven arteriosclerosis on brain biopsy or autopsy or  (b) Multiple hemorrhages (including ICH and CMB) confined to the deep (basal ganglia, thalamus, brainstem) regions of the brain (cerebellar hemorrhages [ICH or CMB] allowed) or  (c) Single (without other ICH/CMB) deep ICH  - <i>and</i> evidence of severe (confluent) WMH and/or lacunes in the deep regions of the brain
A2- Possible underlying disease	Single (without other ICH/CMB) deep ICH - <i>and</i> no evidence of severe (confluent) WMH and/or lacunes  - <i>and</i> absence of other well-defined cause of ICH
A0- Absence of evidence of the disease	MRI (or CT) does not show strictly deep hemorrhage(s) (ICH/CMB).  Cases where there is both deep and lobar hemorrhages are classified as “Mixed SVD” (defined below).
A9- Insufficient work-up	MRI (or CT) not available. MRI can detect CMB (unlike CT) and is preferable to evaluate imaging markers suggesting the presence of arteriosclerosis. Non-contrast CT is an alternative imaging when MRI is contraindicated, not tolerated or not available.

**(C) Cerebral Amyloid Angiopathy\***

C1- Well-defined ICH subtype	(a) Pathologically-proven CAA on brain biopsy or autopsy or  (b) Multiple strictly lobar (cortical or corticosubcortical) hemorrhages, including ICH, CMB, or cSS (cerebellar hemorrhages [ICH or CMB] allowed)  - <i>and</i> age $\geq 55$ years  - <i>and</i> absence of other well-defined cause of ICH
C2- Possible underlying disease	(a) Single strictly lobar (cortical or corticosubcortical) hemorrhages on MRI (or CT), including ICH, CMB or cSS  - <i>and</i> age $\geq 55$ years,  - <i>and</i> absence of other well-defined cause of ICH
C0- Absence of evidence of the disease	Absence of pathological evidence of CAA.  Neuroimaging does not show strictly lobar ICH/CMB nor cSS.  Cases where there is both deep and lobar hemorrhages are classified as “Mixed SVD” (defined below).
C9- Insufficient work-up	MRI (or CT) not available. In the absence of pathological examination, MRI can detect CMB and cSS (unlike CT), and is preferable to rule out CAA. Non-contrast CT is an alternative imaging when MRI is contraindicated, not tolerated or not available.

**(M) Mixed cerebral small vessel diseases**

M1- Well-defined ICH subtype	(a) Pathologically-proven coexistence of arteriosclerosis and CAA on brain biopsy or autopsy or  (b) Mixed hemorrhages: multiple brain hemorrhages (including ICH, CMB, and cSS) located both in lobar and deep regions (cerebellar hemorrhages [ICH or CMB] allowed)
M2- Possible underlying disease	(a) Single (without other ICH/CMB/cSS) lobar ICH  - <i>and</i> evidence of severe (confluent) WMH and lacunes  (b) Single (without other ICH/CMB/cSS) cerebellar ICH  - <i>and</i> evidence of severe (confluent) WMH and lacunes
M0- Absence of evidence of the disease	MRI (or CT) does not show evidence of multiple ICH/CMB or other imaging markers of SVD including severe (confluent) WMH and lacunes
M9- Insufficient work-up	MRI (or CT) not available. MRI can detect CMB and cSS (unlike CT) and is preferable to rule out cerebral small vessel disease. Non-contrast CT is an alternative imaging when MRI is contraindicated, not tolerated or not available.

*Note.* \*Diagnosis of CAA is based on the modified Boston criteria (version 1.5).<sup>25</sup> Well-defined CAA (C1) would also include patients meeting criteria for probable CAA according to Boston criteria 2.0<sup>33</sup> or the simplified Edinburgh criteria for high probability of CAA.<sup>35</sup> Possible underlying CAA (C2) would also include patients meeting criteria for possible CAA according to Boston criteria 2.0<sup>33</sup> or medium probability of CAA according to the simplified Edinburgh criteria.<sup>35</sup> Abbreviations: CAA, cerebral amyloid angiopathy; CMB, cerebral microbleed; CSF, cerebrospinal fluid; cSS, cortical superficial siderosis; CT, computed tomography; ICH, intracerebral hemorrhage; MRI, magnetic resonance imaging; PET, positron emission tomography; SVD, small vessel disease; WMH, white matter hyperintensities.



**TABLE 2B. CLASSification System for ICH Subtypes System****(O) Other form of cerebral small vessel disease**

O1- Well-defined ICH subtype	(a) Inherited SVD (for example: familial forms of CAA, CADASIL, CARASIL, COL4A1 mutations) confirmed with genetic testing
	(b) Well-demonstrated SVD that does not fulfill all criteria for other SVD subtypes. Example could include patient with multiple strictly lobar hemorrhage (ICH/CMB/cSS) but age <55 years
	(c) other rare well-defined causes of SVD (for example post-radiation angiopathy)
O2- Possible underlying disease	(a) Suspected inherited SVD not confirmed with genetic testing based on: - evidence of imaging markers of SVD including CMB, cSS, severe (confluent) WMH, and/or lacunes - documented familial history of ICH
O0- Absence of evidence of the disease	MRI (or CT) does not show evidence imaging markers of SVD including CMB, cSS, severe (confluent) WMH, and lacunes Absence of evidence of genetic SVD Absence of familial history of ICH
O9- Insufficient work-up	MRI (or CT) not available. MRI can detect CMB (unlike CT) and is preferable to rule out cerebral small vessel disease. Non-contrast CT is an alternative imaging when MRI is contraindicated, not tolerated or not available.

**(S) Secondary causes of ICH**

S1- Well-defined ICH subtype	Etiologic investigations have clearly demonstrated the presence of a secondary cause of ICH as listed in Table 3.
S2- Possible underlying disease	Despite a complete work-up, a definite secondary cause of ICH has not been demonstrated, but remain highly suspected based on: - the presence of imaging clues for a secondary cause (early draining vein, disproportionate perihematomal edema) - and/or age < 55 years - and/or absence of imaging markers of SVD
S0- Absence of evidence of the disease	Negative investigations for a secondary cause. When suspected, ruling out a secondary cause may require: brain MRI, CT/MR angiography, intra-arterial digital subtraction angiography, venography, body CT/PET, brain or extracerebral biopsy, blood tests, CSF tests
S9- Insufficient work-up	Unable to reasonably rule out a secondary cause based on the best available etiologic investigations whereas it is suspected based on the clinical context or imaging findings (see Table 3)

Abbreviations: CAA, cerebral amyloid angiopathy; CMB, cerebral microbleed; CSF, cerebrospinal fluid; cSS, cortical superficial siderosis; CT, computed tomography; ICH, intracerebral hemorrhage; MRI, magnetic resonance imaging; PET, positron emission tomography; SVD, small vessel disease; WMH, white matter hyperintensities.

disease; and (0) absence of evidence of the disease that may have caused ICH. Clinical and imaging criteria to define well-defined ICH subtypes are pre-specified. When available, we used validated diagnostic criteria, such as the modified Boston criteria for CAA.<sup>25</sup> The level of diagnostic evidence is considered as “possible” in patients who have imaging markers or clues suggesting the presence of an underlying disease without enough criteria for “well-

defined” ICH subtype. When a patient cannot be scored in an ICH category, because etiological investigations are insufficient, a score (9) for insufficient work-up is given.

**Interobserver Reliability**

We determined the interobserver reliability of the classification system. Two stroke neurologists (D.J.S. and N.R.) independently performed subtype classification using

**TABLE 3. Secondary Causes of Intracerebral Hemorrhage**

Category	Examples	Clinical and imaging clues
Macrovascular causes	<ul style="list-style-type: none"> <li>- Brain arteriovenous malformation (AVM)</li> <li>- Intracranial aneurysm</li> <li>- Dural arteriovenous fistula</li> <li>- Cavernous malformation (CM)</li> </ul>	<ul style="list-style-type: none"> <li>- ICH lobar location, absence of SVD</li> <li>- Extension to subarachnoid and subdural spaces, flow voids and calcifications along the hematoma (AVM)</li> <li>- Subarachnoid hemorrhage in the basal cisterns (intracranial aneurysm)</li> <li>- Subarachnoid or subdural extension and/or abnormal dilated cortical vessels (dural fistula)</li> <li>- Small, well-demarcated ICH with homogenous density on CT (often with heterogeneous intensity on MRI) and no extension to other brain compartments (CM). CM can occur anywhere in the brain, but should be particularly considered in ICH with the above characteristics isolated to the medulla or midbrain.</li> </ul>
Brain tumor	<ul style="list-style-type: none"> <li>- Primary tumor</li> <li>- Metastasis</li> </ul>	<ul style="list-style-type: none"> <li>- Clinical context (fatigue, unexplained weight loss, anorexia, known solid cancer)</li> <li>- Pre-existing headache and other neurological symptoms</li> <li>- Disproportionate perihematomal edema</li> <li>- Active or history of malignancy that is reported to metastasize to the brain</li> </ul>
Hemostatic and hematologic disorders	<ul style="list-style-type: none"> <li>- Severe thrombocytopenia</li> <li>- Severe clotting factor deficiency such as hemophilia</li> <li>- Afibrinogenemia</li> <li>- Other</li> </ul>	<ul style="list-style-type: none"> <li>- Abnormal platelet count or coagulation tests</li> </ul>
Cerebral venous thrombosis (CVT)	<ul style="list-style-type: none"> <li>- CVT from local cause (head trauma, head and CNS infections, tumor)</li> <li>- CVT from systemic cause (pregnancy and puerperium, cancer, prothrombotic disorder, etc.)</li> </ul>	<ul style="list-style-type: none"> <li>- Clinical context (pregnancy or puerperium, known prothrombotic disease, oral contraceptive use, fever, etc.)</li> <li>- Pre-existing headache</li> <li>- ICH location close to venous sinuses</li> <li>- Disproportionate perihematomal edema</li> </ul>
Hemorrhagic infarction	<ul style="list-style-type: none"> <li>- Spontaneous hemorrhagic infarction</li> <li>- Hemorrhagic infarction occurring in patients receiving anticoagulant or thrombolytic therapy</li> </ul>	<ul style="list-style-type: none"> <li>- Presence of acute moderate/large territorial infarcts adjacent to ICH or in other arterial territories</li> </ul>
Vasculitis and related vasculopathies	<ul style="list-style-type: none"> <li>- Primary angiitis of the CNS</li> <li>- Systemic vasculitis</li> <li>- Moyamoya</li> <li>- Reversible Cerebral Vasoconstriction Syndrome</li> <li>- Posterior reversible encephalopathy syndrome</li> <li>- Infective endocarditis, infections of CNS</li> <li>- Other vasculopathies</li> </ul>	<ul style="list-style-type: none"> <li>- Clinical context (valvular cardiopathy, fever, known systemic disease, vasoactive medication or drug)</li> <li>- Pre-existing headache</li> <li>- Co-existence of acute ischemic lesions</li> <li>- Cerebral microbleeds, mycotic aneurysm (infective endocarditis)</li> </ul>
Toxic	<ul style="list-style-type: none"> <li>- Cocaine</li> <li>- Other sympathomimetic drugs</li> </ul>	<ul style="list-style-type: none"> <li>- Clinical context</li> <li>- Laboratory tests</li> </ul>
Rare entities	<ul style="list-style-type: none"> <li>- Dissection of intracranial arteries</li> <li>- Hyperperfusion syndrome</li> <li>- Other</li> </ul>	<ul style="list-style-type: none"> <li>- Clinical context (carotid endarterectomy or angioplasty, endovascular treatment)</li> </ul>

Abbreviations: CT = computed tomography; ICH = intracerebral hemorrhage; MRI = magnetic resonance imaging; PET = positron emission tomography; SVD = small vessel disease;



CLAS-ICH in a derivation cohort and an external validation cohort. Our derivation cohort included 113 consecutive patients admitted at Massachusetts General Hospital, Boston (USA) for spontaneous ICH between May 2017 and August 2019. In the validation cohort, we enrolled 203 consecutive patients with acute ICH admitted at the Inselspital, Bern (Switzerland) between July 2018 and December 2019. The study was performed with approval of the appropriate local review boards. Informed consent was not required due to the retrospective observational design of the study.

Each observer reviewed extracted data from medical records. Data extraction was performed by two investigators (M.C.Z. in the derivation cohort; M.B.G. in the validation cohort) who did not participate in case assessments. Extracted data included age, sex, medical history and medication, brain imaging modalities (non-contrast CT, MRI) and results (acute ICH location categorized as lobar [affecting the cortex or subcortical white matter], deep [affecting the thalamus, basal ganglia, or brainstem], or cerebellar<sup>26</sup>; presence and location of chronic ICH or cerebral microbleeds; presence of cortical superficial siderosis; presence of severe [Fazekas 3] white matter hyperintensities, presence of lacunes; neuroimaging markers of SVD were assessed according to the STandards for Reporting Vascular changes on nEuroimaging [STRIVE]<sup>27</sup>), vascular brain imaging modalities (CT angiography; MR angiography; intra-arterial digital subtraction angiography), and results, blood tests, and other specific investigations. Each observer was provided with a copy of the classification system and was asked to strictly apply related rules (Tables 2 and 3). We also evaluated the interobserver agreement of other pre-existing classification systems (SMASH-U and H-ATOMIC) in the derivation cohort. The interobserver reliability was evaluated using the  $\kappa$  statistic. A  $\kappa$  of 1 indicates perfect agreement, whereas zero shows only chance agreement; in general, excellent agreement refers to values greater than 0.80, whereas 0.61 to 0.80 indicates substantial agreement, and 0.41 to 0.60 indicates moderate agreement.

## Results

The demographics and baseline characteristics of patients in the derivation cohort ( $n = 113$ ) and in the validation cohort ( $n = 203$ ) are shown in Table 4. The mean (SD) age of included patients was 74.7 (11.5) years in the derivation cohort, and 73.3 (12.2) years in the validation cohort. Vascular risk factors and anticoagulant use were more common in the derivation cohort. The distribution of ICH locations was comparable across the study cohorts. Brain imaging was performed in all patients using brain non-contrast CT for 80.7% ( $n = 255$ ) and/or brain MRI

for 56.3% ( $n = 178$ ) of the cohorts. Angiography was obtained to evaluate underlying vascular causes using CT angiography ( $n = 188$ , 59.5%), MR angiography ( $n = 59$ , 18.7%), and/or digital subtraction angiography ( $n = 18$ , 5.7%) based on clinical judgment. There were substantial differences in imaging modalities between the two cohorts. A total of 79 (69.9%) patients from the derivation cohort were evaluated with brain MRI compared with 99 (48.8%) in the validation cohort. CT angiography and MR angiography were also more frequently obtained in the derivation cohort than in the validation cohort.

## ICH Subtypes

Using the CLAS-ICH system, a well-defined ICH subtype was identified in 74 of 113 (65.5%) patients in the derivation cohort, and 130 of 203 (64.0%) patients in the validation cohort ( $p = 0.797$ ). In the derivation cohort, arteriosclerosis ( $n = 24$ ; 21.2%), CAA ( $n = 23$ ; 20.4%), and mixed SVD ( $n = 18$ ; 15.9%) were the most common well-defined ICH subtypes, followed by secondary causes ( $n = 9$ ; 8.0%). Structural macrovascular lesions ( $n = 3$ ) and cerebral venous thrombosis ( $n = 3$ ) were the most frequent well-defined secondary causes. The distribution of well-defined ICH subtypes was comparable in the validation cohort. In the derivation cohort, one or more possible underlying disease(s) were identified in 42 (37.2%) patients, and 36 (31.9%) had multiple possible causes. These proportions were similar in the validation cohort. Within the whole population (derivation and validation cohorts), none of the patients presented with a non-traumatic ICH without any well-defined (level 1) or possible (level 2) underlying disease.

## Overlap Between ICH Subtypes

In the derivation cohort, 36 (31.9%) patients had multiple possible causes (level 2) of ICH (Fig. 2). The most frequent overlapping was observed in patients with possible secondary cause who had a possible other cause, including possible arteriosclerosis ( $n = 16$ ), possible CAA ( $n = 15$ ) or possible mixed SVD ( $n = 1$ ). Overlapping was also observed in 4 patients with possible CAA and possible mixed SVD.

## Interobserver Reliability

There was excellent agreement for ICH phenotyping using CLAS-ICH. The  $\kappa$  value (95% confidence interval) for each category ranged from 0.86 (0.78–0.95) to 1.00 (1.00–1.00) in the derivation cohort, and from 0.91 (0.86–0.96) to 1.00 (1.00–1.00) in the validation cohort (Table 5). In the derivation cohort, ICH subtyping using other classification systems showed higher variability in the interobserver agreement. The  $\kappa$  value (95% confidence interval) for each category ranged from 0.71 (0.41–1.00) to 1.00 (1.00–1.00) when using SMASH-U, and from

**TABLE 4. Patients Characteristics and Distribution of Intracerebral Hemorrhage Subtypes in the Derivation and Validation Cohorts**

	Derivation cohort ( <i>n</i> = 113)	Validation cohort ( <i>n</i> = 203)	<i>p</i> value
Demographics and clinical data			
Age (yr), mean (SD)	74.7 (11.5)	73.3 (12.2)	0.324
Female, <i>n</i> (%)	47 (41.6)	110 (54.2)	0.032
Hypertension, <i>n</i> (%)	100 (88.5)	154 (75.9)	0.007
Diabetes, <i>n</i> (%)	39 (34.5)	36 (17.7)	0.001
Anticoagulant use, <i>n</i> (%)	42 (37.2)	48 (23.6)	0.011
Imaging			
Location of index ICH			0.840
Lobar, <i>n</i> (%)	53 (46.9)	101 (49.8)	
Deep, <i>n</i> (%)	50 (44.2)	87 (42.9)	
Cerebellum, <i>n</i> (%)	10 (8.8)	15 (7.4)	
Brain NCCT performed, <i>n</i> (%)	113 (100)	142 (70.0)	<0.001
CTA performed, <i>n</i> (%)	95 (84.1)	93 (45.8)	<0.001
Brain MRI performed, <i>n</i> (%)	79 (69.9)	99 (48.8)	<0.001
MRA performed, <i>n</i> (%)	34 (30.1)	25 (12.3)	<0.001
DSA performed, <i>n</i> (%)	4 (3.5)	14 (6.9)	0.230
CLAS-ICH subtypes			
Well-defined cause (grade 1)	74 (65.5)	130 (64.0)	0.797
Arteriosclerosis (grade 1)	24 (21.2)	38 (18.7)	0.589
CAA (grade 1)	23 (20.4)	40 (19.7)	0.890
Mixed SVD (grade 1)	18 (15.9)	32 (15.8)	0.969
Other form of SVD (grade 1)	0 (0)	0 (0)	–
Secondary cause (grade 1)	9 (8.0)	20 (9.9)	0.577
Possible cause (grade 2)	42 (37.2)	73 (36.0)	0.831
Multiple causes (≥2 grades 1 or 2)	36 (31.9)	63 (31.0)	0.880
Absence of identified cause (grade 0 or 9)	0 (0)	0 (0)	–

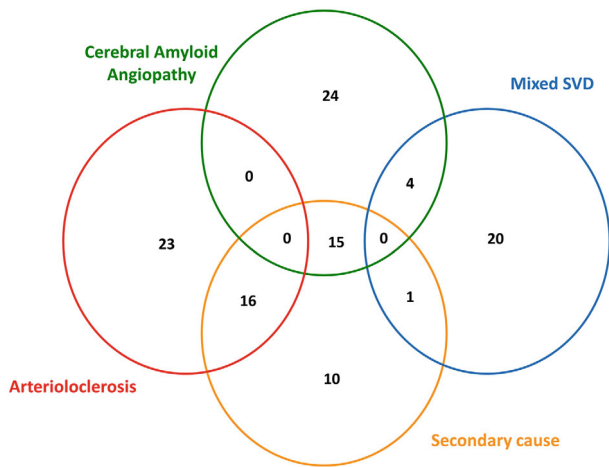
Abbreviations: CAA = cerebral amyloid angiopathy; CLAS-ICH = CLASsification System for Intracerebral Hemorrhage Subtypes; CTA = computed tomography angiography; DSA = digital subtraction angiography; ICH = intracerebral hemorrhage; MRA = magnetic resonance angiography; MRI = magnetic resonance imaging; NCCT = non-contrast computed tomography; SVD = small vessel disease.

0.39 (−0.15–0.93) to 1.00 (1.00–1.00) when using H-ATOMIC (Table 6).

## Discussion

We developed a novel causal classification system for ICH subtyping, termed CLAS-ICH, which is simple to apply

and based on validated neuroimaging markers. In addition to its excellent interobserver reliability, ICH phenotyping using CLAS-ICH in unselected hospital-based cohorts revealed several advantages. This classification system could determine a well-defined ICH subtype in >65% of all ICH cases. When a well-defined ICH subtype was not identified, all other patients had one or more possible



**FIGURE 2: Overlap between intracerebral hemorrhage subtypes.** Venn diagram showing overlap between ICH subtypes (level 1 or 2) included in CLASsification system for ICH Subtypes (CLAS-ICH). SVD = small vessel disease.

cause(s), which may guide clinicians for further investigations. Face validity for CLAS-ICH is provided by the finding that SVD (including arteriolosclerosis, CAA, but also mixed SVD) are the most frequent causes of non-traumatic ICH in the cohort used to test the system. Finally, CLAS-ICH offers the possibility to capture potential overlap between ICH causes, as well as the level of diagnostic evidence.

CLAS-ICH is an imaging-based classification system for ICH. Compared with other ICH classification systems that categorize ICH subgroups based on risk factors, such as hypertension or oral anticoagulant use,<sup>11, 12</sup> CLAS-ICH considers that a pathological process directly or indirectly affecting the cerebral vasculature (ie, cerebral small vessel disease, vascular malformation, brain tumor, cerebral venous thrombosis) is necessary to cause a brain hemorrhage. CLAS-ICH includes evidence derived from comprehensive imaging of the brain parenchyma and intracranial vessels. Assignment to each ICH subgroup relies on the evidence of presumed or validated neuroimaging markers that characterize this subgroup. This may explain substantial differences in ICH subtyping using CLAS-ICH compared with other systems. In our cohort, based on the SMASH-U and H-ATOMIC system, anticoagulants were considered as the cause of ICH in one-third of patients, whereas CLAS-ICH considers anticoagulant as a risk factor and not as a cause. Furthermore, 15% of our cohort classified as mixed hemorrhage using CLAS-ICH are not considered in other classification systems.

CLAS-ICH defines 5 ICH subgroups that are representative of the most frequent causes of spontaneous ICH. Cerebral SVD subgroups are the most common categories in this causal classification system (4 of 5 categories), because they are the main causes of ICH. In the present study, SVD, including arteriolosclerosis, CAA, and mixed

**TABLE 5. Interobserver Agreement for Intracerebral Hemorrhage Phenotyping Using CLASsification System for Intracerebral Hemorrhage Subtypes in the Derivation and Validation Cohorts**

ICH subtypes	Interobserver agreement	
	$\kappa$ value	95% Confidence interval
Derivation cohort ( $n = 113$ )		
Arteriosclerosis (A)	0.86	0.78–0.95
Cerebral amyloid angiopathy (C)	1.00	1.00–1.00
Mixed cerebral small vessel diseases (M)	0.93	0.85–1.00
Other form of Cerebral small vessel disease (O)	1.00	1.00–1.00
Secondary causes of ICH (S)	0.91	0.83–0.98
Validation cohort ( $n = 203$ )		
Arteriosclerosis (A)	0.94	0.89–0.99
Cerebral amyloid angiopathy (C)	0.91	0.86–0.96
Mixed cerebral small vessel diseases (M)	0.87	0.80–0.94
Other form of cerebral small vessel disease (O)	1.00	1.00–1.00
Secondary causes of ICH (S)	0.94	0.89–0.99

Abbreviations: ICH = intracerebral hemorrhage.

SVD, accounted for >85% of all well-defined ICH subtypes. Arteriolosclerosis and CAA are two key ICH subtypes of CLAS-ICH, characterized by different underlying pathological lesions, risk factors, and outcome. CLAS-ICH also consider two additional important ICH subgroups (ie, “mixed” and “other” forms of SVD) that were not considered in pre-existing ICH classifications, although these groups remain likely to be associated with SVD. Recent advances in pathology and neuroimaging suggest that CAA and arteriolosclerosis often co-occur in aging populations.<sup>28,29</sup> The resulting imaging feature of these patients combining imaging markers of CAA (lobar ICH/cerebral microbleeds) and arteriolosclerosis (deep ICH/cerebral microbleeds), often termed “mixed hemorrhages,” is commonly encountered in patients with ICH.<sup>30–32</sup> These cases, which do not fulfill the criteria for

**TABLE 6. Distribution of Intracerebral Hemorrhage Subtypes by Classification System and Interobserver Agreement**

	<i>n</i> (%)	Interobserver agreement, $\kappa$ value (95% CI)
CLAS-ICH		
Arteriosclerosis (grade 1*)	24 (21.2)	0.86 (0.78–0.95)
CAA (grade 1)	23 (20.4)	1.00 (1.00–1.00)
Mixed SVD (grade 1)	18 (15.9)	0.93 (0.85–1.00)
Other form of SVD (grade 1)	0 (0)	1.00 (1.00–1.00)
Secondary cause (grade 1)	9 (8.0)	0.91 (0.83–0.98)
Absence of identified cause (grade 0 or 9)	0 (0)	1.00 (1.00–1.00)
H-ATOMIC		
Hypertension (grade 1 or 2†)	29 (25.7)	0.90 (0.84–0.97)
CAA (grade 1 or 2)	20 (17.7)	0.97 (0.83–0.98)
Tumor (grade 1 or 2)	2 (1.8)	1.00 (1.00–1.00)
Oral anticoagulant (grade 1 or 2)	42 (37.2)	0.93 (0.85–1.00)
AVM/Cavernoma (grade 1 or 2)	2 (1.8)	1.00 (1.00–1.00)
Infrequent cause (grade 1 or 2)	4 (3.5)	0.74 (0.53–0.95)
Cryptogenic	4 (3.5)	0.39 (–0.15–0.93)
SMASH-U		
Structural vascular lesion	6 (5.3)	1.00 (1.00–1.00)
Medication	38 (33.6)	1.00 (1.00–1.00)
CAA	30 (26.5)	0.89 (0.79–0.98)
Systemic disease	1 (0.9)	1.00 (1.00–1.00)
Hypertension	31 (27.4)	0.96 (0.89–1.00)
Undetermined	4 (3.5)	0.71 (0.41–1.00)

Note: Distribution of intracerebral hemorrhage subtypes within the derivation cohort ( $n = 113$ ) according to CLAS-ICH, H-ATOMIC and SMASH-U classification systems.

Abbreviations: AVM = arteriovenous malformation; CAA = cerebral amyloid angiopathy; SVD = small vessel disease.

\*CLAS-ICH grade 1 is defined as a well-defined intracerebral hemorrhage subtype;

†H-ATOMIC grade 1 is defined as a definite cause, and grade 2 as a probable cause.

“pure” arteriosclerosis or “pure” CAA are likely to relate to a combination of these two diseases and are categorized in CLAS-ICH as mixed SVD. Other rare forms of SVD, including genetic SVD (eg, COL4A1, CADASIL) are also considered in CLAS-ICH. The last category of CLAS-ICH—secondary causes—accounting for 12% of well-defined ICH subtypes in our cohort, comprises structural

macrovascular lesions and other rare causes of ICH. Although it might seem quite heterogeneous, this latest ICH subgroup includes ICH cases requiring specific etiological work-up and treatment, compared with SVD-related ICH.

The philosophy of CLAS-ICH is analogous to the ASCOD classification for ischemic stroke subtyping.<sup>9</sup> Instead of selecting one single ICH cause, which is thought to be more likely linked to ICH (elimination strategy applied in SMASH-U classification), CLAS-ICH evaluates all potential underlying causes in a given patient and captures the overlap between ICH subgroups. The present findings showed that overlaps between ICH subtypes primarily concern “possible” secondary causes with “possible” arteriosclerosis or CAA. This has important clinical relevance suggesting that in the absence of other marker of SVD, a secondary cause should be sought in patients with a single lobar or single deep ICH despite normal first-line investigations.

Another important difference between CLAS-ICH and previous ICH classification systems is the absence of “cryptogenic” or “undetermined” ICH subgroups. These are default categories, which are difficult to define. The concept of “cryptogenic” ICH may lead clinicians to consider that some ICH can occur without any underlying vascular disease. Using CLAS-ICH, such hemorrhages are classified as one (or multiple) “possible underlying cause(s)” based on patient’s age, ICH location, and other imaging findings. This information is useful for clinicians, and can guide further etiological investigations and/or repeated neuroimaging to determine a definite cause, instead of accepting a final diagnosis of “cryptogenic ICH.”

Another strength of CLAS-ICH is that this classification system is quite simple and fast to apply, based on imaging markers that are routinely collected in daily practice. Each ICH case is graded in all potential ICH subtypes instead of selecting the most likely cause (that may be interpretative and source of inter-observer variability). Accordingly, CLAS-ICH has been shown to classify ICH subtypes accurately with high interobserver reliability, and less variability in interobserver agreement than other systems. Defining ICH subgroups can have different purposes, such as patient’s selection for clinical trial, providing well-phenotyped ICH cohorts for epidemiological studies, patients prognostication, and identifying ICH subgroups requiring specific therapies in routine clinical practice. Similarly to causative classification systems developed for subtyping ischemic stroke, we believe CLAS-ICH will help harmonize decision on ICH causes among physicians and to improve comparability among studies.

The present study had limitations. Brain imaging modalities may vary across centers, and MRI is sometimes contraindicated or not tolerated in patients with severe ICH. As this novel classification system was designed to be widely applicable to most patients with non-traumatic ICH, CLAS-ICH can be used in patients evaluated either with MRI or CT. We acknowledge that the ability of CLAS-ICH to determine underlying cause of ICH might be affected by imaging modalities. However, despite substantial differences in imaging evaluation in our derivation and validation cohorts (70% vs 49% with available MRI), CLAS-ICH could determine a well-defined ICH subtype in 65% of cases in the derivation cohort, but also in the validation cohort. In the current version of CLAS-ICH, diagnosis of CAA was based on the modified Boston criteria (version 1.5) instead of the recently published Boston criteria V2.0,<sup>33</sup> which were not available when we designed the structure of CLAS-ICH. Although Boston criteria V2.0 include additional MRI markers (such as centrum semi ovale enlarged perivascular spaces, or multispot white matter hyperintensities) compared with Boston criteria V1.5, these two versions have many similarities, and diagnosis of CAA in CLAS-ICH may also be made according to the Boston criteria V2.0. Nevertheless, CLAS-ICH should be updated and validated in the future to fit with the Boston criteria V2.0. We also might have considered the Edinburgh CT and genetic diagnostic criteria for CAA, which have shown high diagnostic accuracy in patients with large fatal lobar ICH.<sup>34</sup> Nevertheless, we did not include these CT-based criteria in the novel classification system, because those require apolipoprotein E genotyping (which is not performed in routine clinical practice in many centers), and the Edinburgh criteria have not been yet validated in ICH survivors. However, we may update CLAS-ICH and include the simplified Edinburgh criteria,<sup>35</sup> which have shown high diagnostic performance in patients with large ICH.

## Conclusion

Advances in neuroimaging enable accurate ICH phenotyping, but standardized etiological work-up and validated causal classification system are needed. ICH is a heterogeneous disease with various causes that can coexist in a given patient. We believe that the novel CLAS-ICH system might be useful to fill this clinical and research need to guide clinicians in determining underlying cause(s) of ICH and provide appropriate treatment. As CLAS-ICH offers high interobserver reliability in ICH subtyping, this new classification system would also be widely used by researchers, enabling the features of well-phenotyped ICH cohorts to be compare across study centers.

## Author Contributions

Nicolas Raposo and Anand Viswanathan contributed to study concept and design. Nicolas Raposo, Maria Clara Zanon Zotin, David J. Seiffge, Qi Li, Martina B. Goeldlin, Andreas Charidimou, Ashkan Shoamanesh, Hans Rolf Jäger, Charlotte Cordonnier, Catharina J.M. Klijn, Eric E. Smith, Steven M. Greenberg, David J. Werring, and Anand Viswanathan contributed to acquisition and analysis of data. Nicolas Raposo and Anand Viswanathan contributed to drafting the manuscript and the figures.

## Acknowledgements

The authors thank Andrew D. Warren for expert technical assistance. This study was supported by the following NIH grants: P50 AG005134, R01 AG047975, R01 NS104130. Open Access funding enabled and organized by Projekt DEAL.

## Potential Conflict of Interest

Charlotte Cordonnier received research grants from the French ministry of health (PHRC) for the A3ICH and TICH3-Fr trials, and honoraria for lectures from Bristol Myers Squibb. The other authors have nothing to report.

## Data Availability Statement

The data of this study are available upon reasonable request.

## References

1. Collaborators GBDS. Global, regional, and national burden of stroke and its risk factors, 1990-2019: a systematic analysis for the global burden of disease study 2019. *Lancet Neurol* 2021;20:795–820.
2. van Asch CJ, Luitse MJ, Rinkel GJ, et al. Incidence, case fatality, and functional outcome of intracerebral haemorrhage over time, according to age, sex, and ethnic origin: a systematic review and meta-analysis. *Lancet Neurol* 2010;9:167–176.
3. Roquer J, Rodriguez-Campello A, Jimenez-Conde J, et al. Sex-related differences in primary intracerebral hemorrhage. *Neurology* 2016;87:257–262.
4. Moulin S, Labreuche J, Bombois S, et al. Dementia risk after spontaneous intracerebral haemorrhage: a prospective cohort study. *Lancet Neurol* 2016;15:820–829.
5. Planton M, Saint-Aubert L, Raposo N, et al. High prevalence of cognitive impairment after intracerebral hemorrhage. *PLoS One*. 2017; 12:e0178886.
6. Cordonnier C, Demchuk A, Ziai W, Anderson CS. Intracerebral haemorrhage: current approaches to acute management. *Lancet* 2018;392:1257–1268.
7. Gross BA, Jankowitz BT, Friedlander RM. Cerebral Intraparenchymal hemorrhage: a review. *JAMA* 2019;321:1295–1303.
8. Adams HP Jr, Bendixen BH, Kappelle LJ, et al. Classification of subtype of acute ischemic stroke. Definitions for use in a multicenter

- clinical trial. TOAST. Trial of org 10172 in acute stroke treatment. *Stroke* 1993;24:35–41.
9. Amarenco P, Bogousslavsky J, Caplan LR, et al. The ASCOD phenotyping of ischemic stroke (updated ASCO phenotyping). *Cerebrovasc Dis* 2013;36:1–5.
  10. Ay H, Furie KL, Singhal A, et al. An evidence-based causative classification system for acute ischemic stroke. *Ann Neurol* 2005;58:688–697.
  11. Meretoja A, Strbian D, Putaala J, et al. SMASH-U: a proposal for etiologic classification of intracerebral hemorrhage. *Stroke* 2012;43:2592–2597.
  12. Marti-Fabregas J, Prats-Sanchez L, Martinez-Domeno A, et al. The H-ATOMIC criteria for the etiologic classification of patients with intracerebral hemorrhage. *PLoS One* 2016;11:e0156992.
  13. Cordonnier C, Klijn CJ, van Beijnum J, Al-Shahi SR. Radiological investigation of spontaneous intracerebral hemorrhage: systematic review and trinational survey. *Stroke* 2010;41:685–690.
  14. Qureshi AI, Tuhim S, Broderick JP, et al. Spontaneous intracerebral hemorrhage. *N Engl J Med* 2001;344:1450–1460.
  15. Charidimou A, Gang Q, Werring DJ. Sporadic cerebral amyloid angiopathy revisited: recent insights into pathophysiology and clinical spectrum. *J Neurol Neurosurg Psychiatry* 2012;83:124–137.
  16. Charidimou A, Boulouis G, Pasi M, et al. MRI-visible perivascular spaces in cerebral amyloid angiopathy and hypertensive arteriopathy. *Neurology* 2017;88:1157–1164.
  17. Pantoni L. Cerebral small vessel disease: from pathogenesis and clinical characteristics to therapeutic challenges. *Lancet Neurol* 2010;9:689–701.
  18. Delgado Almandoz JE, Schaefer PW, Forero NP, et al. Diagnostic accuracy and yield of multidetector CT angiography in the evaluation of spontaneous intraparenchymal cerebral hemorrhage. *AJNR Am J Neuroradiol* 2009;30:1213–1221.
  19. van Asch CJ, Velthuis BK, Rinkel GJ, et al. Diagnostic yield and accuracy of CT angiography, MR angiography, and digital subtraction angiography for detection of macrovascular causes of intracerebral haemorrhage: prospective, multicentre cohort study. *BMJ* 2015;9:h5762.
  20. Hilkens NA, van Asch CJJ, Werring DJ, et al. Predicting the presence of macrovascular causes in non-traumatic intracerebral haemorrhage: the DIAGRAM prediction score. *J Neurol Neurosurg Psychiatry* 2018;89:674–679.
  21. Licata B, Turazzi S. Bleeding cerebral neoplasms with symptomatic hematoma. *J Neurosurg Sci* 2003;47:201–210. discussion 10.
  22. Rannikmae K, Woodfield R, Anderson CS, et al. Reliability of intracerebral hemorrhage classification systems: a systematic review. *Int J Stroke* 2016;11:626–636.
  23. Dequatre-Ponchelle N, Henon H, Pasquini M, et al. Vitamin K antagonists-associated cerebral hemorrhages: what are their characteristics? *Stroke* 2013;44:350–355.
  24. Seiffge DJ, Wilson D, Ambler G, et al. Small vessel disease burden and intracerebral haemorrhage in patients taking oral anticoagulants. *J Neurol Neurosurg Psychiatry* 2021;92:805–881.
  25. Linn J, Halpin A, Demaerel P, et al. Prevalence of superficial siderosis in patients with cerebral amyloid angiopathy. *Neurology* 2010;74:1346–1350.
  26. Charidimou A, Schmitt A, Wilson D, et al. The cerebral Haemorrhage anatomical RaTing inStrument (CHARTS): development and assessment of reliability. *J Neurol Sci* 2017;15:178–183.
  27. Wardlaw JM, Smith EE, Biessels GJ, et al. Neuroimaging standards for research into small vessel disease and its contribution to ageing and neurodegeneration. *Lancet Neurol* 2013;12:822–838.
  28. Ritter MA, Droste DW, Hegedus K, et al. Role of cerebral amyloid angiopathy in intracerebral hemorrhage in hypertensive patients. *Neurology* 2005;64:1233–1237.
  29. Schreiber S, Wilisch-Neumann A, Schreiber F, et al. Invited review: the spectrum of age-related small vessel diseases: potential overlap and interactions of amyloid and nonamyloid vasculopathies. *Neuropathol Appl Neurobiol* 2020;46:219–239.
  30. Pasi M, Charidimou A, Boulouis G, et al. Mixed-location cerebral hemorrhage/microbleeds: underlying microangiopathy and recurrence risk. *Neurology* 2018;90:e119–e126.
  31. Blanc C, Viguier A, Calviere L, et al. Underlying small vessel disease associated with mixed cerebral microbleeds. *Front Neurol* 2019;10:1126.
  32. Tsai HH, Pasi M, Tsai LK, et al. Microangiopathy underlying mixed-location intracerebral hemorrhages/microbleeds: a PiB-PET study. *Neurology* 2019;92:e774–e781.
  33. Charidimou A, Boulouis G, Frosch MP, et al. The Boston criteria version 2.0 for cerebral amyloid angiopathy: a multicentre, retrospective, MRI-neuropathology diagnostic accuracy study. *Lancet Neurol* 2022;21:714–725.
  34. Rodrigues MA, Samarasekera N, Lerpiniere C, et al. The Edinburgh CT and genetic diagnostic criteria for lobar intracerebral haemorrhage associated with cerebral amyloid angiopathy: model development and diagnostic test accuracy study. *Lancet Neurol* 2018;17:232–240.
  35. Schwarz G, Banerjee G, Hostettler IC, et al. MRI and CT imaging biomarkers of cerebral amyloid angiopathy in lobar intracerebral hemorrhage. *Int J Stroke* 2022;7:17474930211062478.
  36. Delgado Almandoz JE, Schaefer PW, Goldstein JN, et al. Practical scoring system for the identification of patients with intracerebral hemorrhage at highest risk of harboring an underlying vascular etiology: the secondary intracerebral hemorrhage score. *AJNR Am J Neuroradiol* 2010;31:1653–1660.