



**HAL**  
open science

## Takotsubo cardiomyopathy

Anthony Matta, Clement Delmas, Francesco Campelo-Parada, Thibault Lhermusier, Frederic Bouisset, Meyer Elbaz, Vanessa Nader, Stephanie Blanco, Jérôme Roncalli, Didier Carrié

► **To cite this version:**

Anthony Matta, Clement Delmas, Francesco Campelo-Parada, Thibault Lhermusier, Frederic Bouisset, et al.. Takotsubo cardiomyopathy. *Reviews in Cardiovascular Medicine*, 2022, 23 (1), 8 p. 10.31083/j.rcm2301038 . hal-04469405

**HAL Id: hal-04469405**

**<https://ut3-toulouseinp.hal.science/hal-04469405v1>**

Submitted on 20 Feb 2024

**HAL** is a multi-disciplinary open access archive for the deposit and dissemination of scientific research documents, whether they are published or not. The documents may come from teaching and research institutions in France or abroad, or from public or private research centers.

L'archive ouverte pluridisciplinaire **HAL**, est destinée au dépôt et à la diffusion de documents scientifiques de niveau recherche, publiés ou non, émanant des établissements d'enseignement et de recherche français ou étrangers, des laboratoires publics ou privés.



Distributed under a Creative Commons Attribution 4.0 International License

Review

## Takotsubo cardiomyopathy

Anthony Matta<sup>1,2</sup>, Clement Delmas<sup>1</sup>, Francesco Campelo-Parada<sup>1</sup>, Thibault Lhermusier<sup>1</sup>, Frederic Bouisset<sup>1</sup>, Meyer Elbaz<sup>1</sup>, Vanessa Nader<sup>1</sup>, Stephanie Blanco<sup>1</sup>, Jérôme Roncalli<sup>1</sup>, Didier Carrié<sup>1,\*</sup>

<sup>1</sup>Department of Cardiology, Toulouse University Hospital, 31000 Toulouse, France

<sup>2</sup>Faculty of Medicine, Holy Spirit University of Kaslik, 446 Jounieh, Lebanon

\*Correspondence: [carrie.didier@chu-toulouse.fr](mailto:carrie.didier@chu-toulouse.fr) (Didier Carrié)

Academic Editor: Giuseppe Andò

Submitted: 19 September 2021 Revised: 9 November 2021 Accepted: 10 November 2021 Published: 20 January 2022

### Abstract

Takotsubo cardiomyopathy (TTC) is a clinical condition of transient acute heart failure correlated to regional wall motion abnormalities extending beyond the distribution of a single epicardial coronary artery. It is classified into four major types: apical, basal, mid-ventricular and focal. Sympathetic nerve stimulation and catecholamine storm are the main players in the pathogenesis of TTC. The clinical course of disease is generally benign but it may end with life-threatening complications. Coronary angiography, left ventriculogram, transthoracic echocardiography and cardiac magnetic resonance imaging (CMR) are the main tools for making diagnosis. Except for critical cases with hemodynamic instability and/or complications, the overall management is limited to conventional heart failure therapy.

**Keywords:** Takotsubo cardiomyopathy; Heart failure; Apical ballooning syndrome; Acute coronary syndrome; Cardiac MRI

### 1. Introduction

Takotsubo cardiomyopathy (TTC) also known as « broken heart syndrome », « stress-induced cardiomyopathy » and « apical ballooning syndrome » is a clinical entity characterized by transient wall motion abnormalities of the left ventricle causing acute reversible heart failure that is not linked to obstructive coronary artery disease [1]. Its clinical presentation, typically precipitated by emotional or physical stressors, mimics acute coronary syndrome (ACS). It was firstly described by Hikaru Sato in 1990 [2] and the term « Takotsubo » derived from the octopus pots used by Japanese Fishermen which resemble the heart's form in the setting of apical TTC [3]. Temporary regional wall motion abnormalities exceeding a single epicardial vascular distribution, no evidence of significant coronary artery disease, new electrocardiogram (EKG) and/or cardiac biomarker modifications and absence of underlying pheochromocytoma or myocarditis are the main diagnostic criteria [4]. The observed EKG abnormalities include ST-segment elevation particularly in the anterior leads, ST-depression, T-wave inversion, prolonged QT-interval, ventricular tachycardia and fibrillation [5], thereby causing misdiagnosis of TTC as ACS especially when these changes are associated with positive cardiac troponin level. This overlap in clinical presentation emphasizes on the importance of early coronary angiography according to the clinical setting for differential diagnosis. Otherwise, TTC may mimic variant diseases like subarachnoid hemorrhage, intracerebral bleeding, pheochromocytoma and cocaine abuse which can be easily distinguished via the obvious clinical manifestation. The inter TAK Diagnostic Score is a novel clin-

ical score developed to differentiate TTC from ACS in the acute stage with high specificity and sensitivity levels [6]. Noteworthy that relevant coronary artery disease may coexist in a high proportion of TTC patients and negatively impacts the overall prognosis [7]. Since the first reported case, the prevalence of TTC is steadily increasing and represents 1–3% of all ACS and 5–6% of ST-segment elevation myocardial infarction (STEMI) presentation in women [8–10]. TTC is markedly more common in women especially in post-menopausal period. Indeed, women with a mean age of 67–70 years account for 90% of TTC [11–13]. The risk of TTC is 10 times higher in women than men and 5 folds greater in women aged above 55 years compared to those aged below 55 years [14]. The hypothesis behind female preponderance was that men are more protected against cardiac adverse effects of catecholamines as they are more frequently exposed to physical stress [14]. The modifications in sensitivity and density of myocardial adrenergic receptors from base to apex during menopause may explain the age-sex difference in women [14]. It is worthy to mention that TTC occurs in adulthood and childhood noticing that the youngest reported case in the published literature was in a premature neonate [15]. There are several described variants of TTC with specific cardiac features but sharing in common the clinical signs, symptoms, pathophysiological mechanisms and the presence of identifiable preceding stressful trigger in two-third of cases [16]. Triggers are divided into two main categories: the emotional or psychological stressors such as grief, fear, panic, anger, anxiety, financial or employment problems, embarrassment, natural disasters and happy heart syndrome [17–19] which were



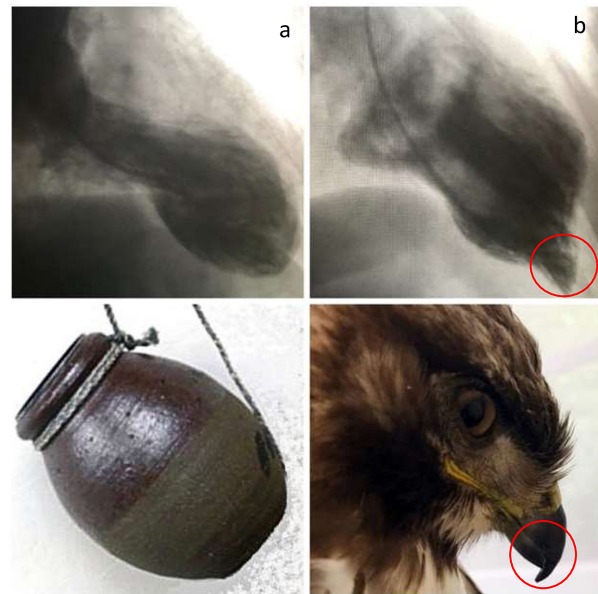
more common in female patients [11] and the physical stressors including physical activities, medical conditions and procedures [1,20,21] which were more frequently observed in male patients [11]. Herein, we briefly review the different types, pathophysiology and treatment of TTC.

## 2. Types of TTC

Based on the anatomical distribution of the regional wall motion abnormalities, TTC is classified into four major types. The apical type is the classical form accounting for 80% of Tako tsubo cases and characterized by basal hyperkinesis, apical ballooning and hypokinesis of the mid-ventricular and apical segments figuring out a fluoroscopic aspect of the left ventriculogram like the octopustraps in Japan [22] (Fig. 1). The basal type is the inverted variant of typical TTC and it is defined by a basal hypokinesis and apical hypercontractility [23]. Then, the mid-ventricular and focal types are the more rarer variants of TTC. The hawk's beak appearance of left ventriculogram, first reported by Roncalli *et al.* in 2007 [24], is a new angiographic sign for the mid-ventricular form of TTC, defined by hyperkinesis of the apical segment and dyskinesis of the ballooned mid-ventricular region [24,25] (Fig. 2). Patients with atypical TTC (basal, mid-ventricular and focal types) are younger, with more neurological disorders, less altered left ventricular ejection fraction, more common ST-depression on initial EKG and lower 1-year mortality than those with typical TTC [26,27]. The basal type of TTC has been recognized to be more associated with the existence of subarachnoid haemorrhage [28], pheochromocytoma [29] and epinephrine-induced TTC [30]. In addition to the four main types of TTC, further variants have been reported including the isolated right ventricular, biventricular (typical TTC with right ventricular involvement) and global forms, respectively [31–34].

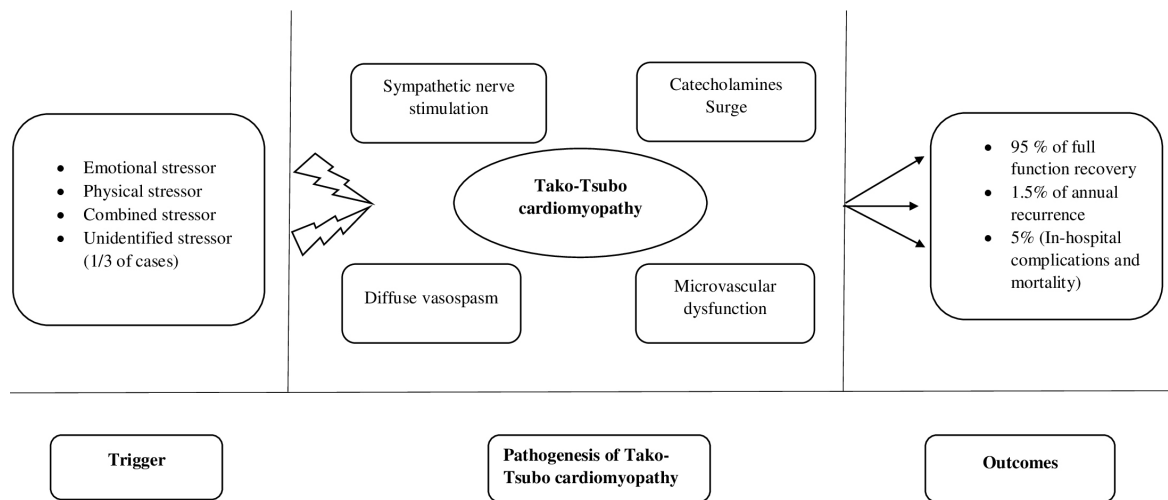
## 3. Pathophysiology

To date, the precise pathophysiology of TTC remains uncertain and multiple pathophysiological mechanisms including diffuse vasospasm, microcirculatory dysfunction, direct catecholamine toxicity on cardiomyocytes and activation of myocardial survival pathways have been suggested [1,35–37]. Conventionally, an enhanced sympathetic stimulation with massive catecholamine release plays the key role in the pathogenesis of TTC (Fig. 2). The correlation between the presence of precipitating stressful event and the onset of TTC supports the pivotal role of the sympathetic or adrenergic response. Increased serum and cardiac nerve endings catecholamine levels have been documented in TTC patients [38] which were two times more than that of patients with acute myocardial infarction [39, 40]. This catecholamine surge contributes to left ventricular outflow tract obstruction detected in 25% of TTC patients [41], apical ballooning [42,43] and vasospasm of the epicardial vessels and coronary microcirculation [38,44].



**Fig. 1. Left ventriculogram showing the apical ballooning form of TTC resembling to octopus trap (a) and the mid-ventricular type with hawk's beak appearance (b).** This figure showed the case of two patients who underwent emergent coronary angiography for acute coronary syndrome, and in whom the left ventriculogram revealed the described features of apical (a) and mid-ventricular (b) Tako-tsubo respectively.

Left ventricular dysfunction in TTC ensues from the direct toxicity of catecholamines on cardiomyocytes. The extreme catecholamine production reduces cardiomyocytes viability by promoting intracellular calcium overload, inhibiting the expression of sarcoplasmic- $\text{Ca}^{2+}$ -adenosinetriphosphatase (SERCA2a) gene expression and upregulating the expression of sarcolipin gene [45]. Thus, the increased phospholamban/SERCA2a ratio results in decreasing  $\text{Ca}^{2+}$  affinity and myocardial contractility [46]. The excess of catecholamines provokes multi-vessels epicardial spasm that amplifies cardiac workload resulting in a supply-demand mismatch and subsequently, a state of post-ischemic stunning myocardium [38,44]. It also activates  $\alpha 1$ - and type A endothelin receptors which induce vasoconstriction leading to microcirculatory dysfunction, reduction in coronary flow reserve and microvascular blood flow during the acute phase of TTC [47–49]. The participation of microcirculatory dysfunction in the pathogenesis of TTC has been supported via the improvement in myocardial perfusion, wall motion score and left ventricular ejection fraction observed after adenosine administration in the acute phase of TTC [50] and the results of endomyocardial biopsies showing apoptosis of microvascular endothelial cells [51]. The transient characteristic of TTC may be explained by the activation of two myocardial protective mechanisms. The first one is manifested by the switching of  $\beta_2$ -adrenoceptor from  $G_s$  to  $G_i$  coupling in response to catecholamine surge which initiates a negative inotropic



**Fig. 2. Pathogenesis and outcomes of Tako-Tsubo cardiomyopathy.** Physical or emotional or combined triggers were found in 2/3 of Tako-tsubo cases subsequently activating the main pathophysiological mechanisms of Tako-tsubo cardiomyopathy including the sympathetic nerve stimulation, catecholamines surge, diffuse vasospasm and microvascular dysfunction. Tako-tsubo is associated with good outcomes marked by 95% of full function recovery, 1.5% of annual recurrence and 5% of in-hospital complications and mortality.

effect restricting the degree of myocardial injury [52] and the second mechanism is represented by the activation of AKT survival pathway [53]. A role for oxidative stress in the pathophysiology of TTC has been supported by several studies which reported a correlation between the level of oxidative stress and the extension of myocardial dysfunction [54]. A recent study has reported a significant association between malignancy and TTC and showed that patients with history of malignancy are at higher risk for TTC [55]. Despite the fact that administration of exogenous catecholamines could trigger the different ventricular ballooning forms in animal models [43,56–58], the increased level of serum catecholamines is more likely to be the consequence rather than the cause of TTC. Indeed, humans are exposed to various stressful situations and medical conditions (for example pheochromocytoma) resulting in a spike in catecholamines level without generating TTC [42,59].

#### 4. Cardiac imaging in TTC

Transthoracic echocardiography (TTE) is the initial non-invasive test in TTC which is often performed in the emergency department. It delineates the area of dysfunctional myocardium and evaluates the left ventricular function, especially with the advanced echocardiographic techniques like tissue doppler velocities and speckle tracking method that denotes transient circular impairments of radial, circumferential and longitudinal left ventricular functions on top of left ventricular twist mechanics defect [60–63]. Also, the peak systolic strain is considered more useful than speckle tracking imaging in assessing the left ventricular contractility and dynamics particularly in patients with reduced LVEF [63]. The two-dimensional speckle echocardiography may point out early systolic functional impair-

ment by assessing the global and longitudinal strain. It has a prognostic value by predicting the in-hospital adverse clinical outcomes in the acute setting of TTC [64]. Furthermore, acute impairment of diastolic function parameters (E/A ratio, mean, e' and A wave duration) has been observed in the context of TTC which improves in parallel with systolic function recovery [65]. After echocardiography, CMR becomes a valuable non invasive imaging test used to assess TTC in some complicated cases. In general, physicians complete a normal or near normal coronary angiography in ACS patients with left ventriculography searching for TTC especially when precipitating trigger is present. Then, performing CMR in complicated cases provides useful data to confirm diagnosis, make differential diagnosis, detect complications, stratify risk, follow-up and assess left ventricular function, wall motion abnormalities and biventricular involvement [66,67]. Myocardial oedema, a constant CMR feature, reflects the extension of myocardial inflammation in acute TTC [67–69]. Positive late gadolinium enhancement (LGE) may appear for three reasons: increased cardiomyocytes interstitial water content [70], collagen-1 fiber density [71] and the presence of contraction band necrosis [72,73]. There is evidence that microvascular dysfunction plays an important role in the pathogenesis of TTC, therefore the usefulness of quantitative perfusion CMR which is not practically used in TTC patients, for the evaluation of microvascular ischaemia has been reported [74]. Noteworthy that microvascular dysfunction was significantly more associated to apical TTC than the other types [75]. The apex is the most distal part irrigated in a watershed area of blood supply between the epicardial coronary arteries and subsequently, it is more susceptible to blood interruption. Moreover, CMR detects the

potential complications of TTC such as systolic heart failure, intra-cavitary thrombus, acute pericarditis and left ventricular outflow tract obstruction [76]. TTC patients with positive LGE were at higher risk for cardiogenic shock and prolonged recovery interval [77] without difference in long-term adverse outcomes compared to those with intact myocardium [78]. The prognostic value of LGE in TTC is not well-settled and remains under investigation.

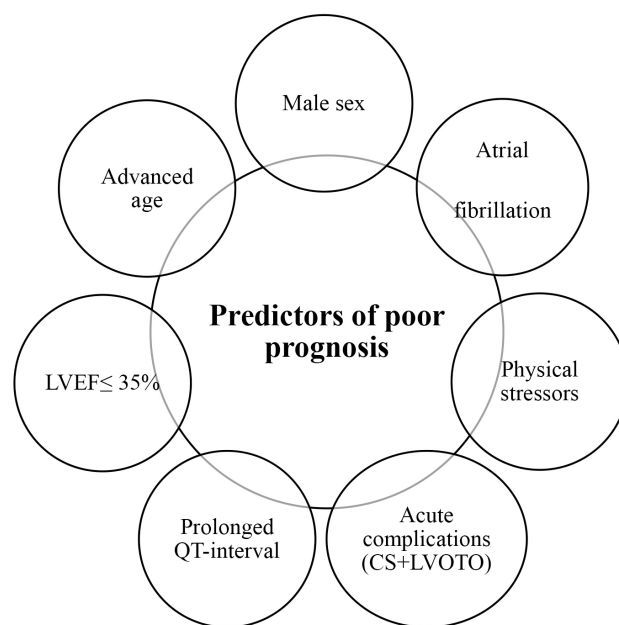
## 5. Laboratory findings in TTC

A markedly elevated level of brain natriuretic peptides (BNP) is usually observed in most TTC patients. The rationale for this finding extends from the knowledge of the pathophysiology of this cardiomyopathy characterized by regional wall motion abnormalities. The excessive production of BNP is linked to the left ventricular pressure overload ensued from regional hypercontractility (basal in the classic type and apical in the basal form) acting in a manner similar to left ventricular hypertrophy and aortic stenosis [79]. BNP level peaks in a week, then normalized within the following months [79]. Furthermore, cardiac enzymes namely troponin, CK and CK-MB were released in TTC making difficult to distinguish TTC from myocardial infarction based on cardiac biomarkers alone. However, the diagnosis of TTC seems to be unlikely in patients with troponin T level greater than 6 ng/mL and troponin I level greater than 15 ng/mL [80].

## 6. Treatment

To date, the management of TTC is mainly supportive and based on the conventional medical therapy for heart failure view the lack of clinical trials. Treatment may be continued at least till the normalisation of left ventricular function, usually occurring 3–4 weeks after the onset of TTC syndrome. It also varies in parallel with the severity of the clinical presentation from single symptomatic treatment in mild cases to aggressive mechanical cardiac support in severe refractory cases [42]. Heart failure medications like  $\beta$ -blockers, angiotensin-converting enzymes inhibitors (ACEi), angiotensin II receptor blockers (ARB) and angiotensin receptor-neprilysin inhibitors are indicated in hemodynamic stable patients [42,81,82]. Diuretics and vasodilators could be used to treat pulmonary congestion [42]. Aldosterone antagonists may have additional benefits with cardioprotective impact in TTC patients view the synergistic effect of aldosterone and catecholamines on the cardiovascular system [83–85]. Early hospital discharge within 48–72 hours is possible for those with LVEF  $\geq$ 45% and not facing any complications [86]. Compared to  $\beta$ -blockers, a systematic review and a meta-analysis study have reported that ACEi/ARB were associated to an improvement in survival and reduction in the rate of recurrence [87,88] while another study revealed the lack of efficacy of ACEi/ARB and  $\beta$ -blockers on preventing TTC recurrence [89]. In opposition, the use of  $\beta$ -blockers es-

pecially esmolol, propranolol and metoprolol decreases the incidence of left ventricular out flow obstruction in the setting of TTC [90–93] and overall 1-year mortality in the context of cardiogenic shock [94,95]. Inotropes (milrinone, dobutamine and dopamine), vasopressors and mechanical left ventricular assist devices may be mandatory in TTC patients and cardiogenic shock [42]. Data from case series have also reported the safety and feasibility of levosimendan, a calcium sensitizer, in TTC patients [96]. However, inotropes should be avoided in the context of left ventricular out flow tract obstruction as that may aggravate the obstruction while extra-corporeal membrane oxygenation and impella may be helpful in the advanced severe cases [42]. TTC patients are at risk for cerebrovascular events which occur in 7.1% of cases throughout the first 30 days of hospitalisation [97], thereby initiating prophylactic anticoagulation therapy is preferred in high risk patients, like the presence of large area of myocardial hypokinesis [42] or apical variant with high initial troponin level [98]. Otherwise, the use of antiplatelet therapy is still debatable in TTC [99,100]. No reduction in major cardiovascular events at 30 days and 5 years follow-up was observed after aspirin intake in TTC [101]. Lastly, it is important to assess and manage the emotional and/or physical trigger on top of the coexisting comorbidities because most of the long-term mortality in TTC seems linked to non-cardiac conditions [102].



**Fig. 3. Independent predictors of poor prognosis in Tako-Tsubo cardiomyopathy.** Advanced age, male sex, reduced left ventricular ejection fraction below 35%, prolonged QT-interval, presence of physical stressors, atrial fibrillation and acute complications like cardiogenic shock or left ventricular outflow tract obstruction represent the independent predictors of poor prognosis in Tako-tsubo cardiomyopathy.

## 7. Prognosis

Since a long time ago, the overall prognosis of TTC has been considered acceptable with a complete recovery rate of 95% [37,93,99]. The reported incidence of in-hospital mortality and annual recurrence were 5% [40,41] and 1.5% [85], respectively. Recent data suggest that outcomes in TTC is comparable to ACS and InterTAK Prognostic score was developed to stratify the patient's risk [103]. A score level above 22 define high risk patients [103]. The mortality is significantly higher in men [91], and in patients with old age [102,104], atrial fibrillation (two times more) [105,106] and physical stressor [84,100]. Deaths mainly occur in patients with hemodynamic instability on initial presentation [40]. Although, prolonged QT interval on electrocardiogram [107,108], reduced left ventricular ejection fraction below 35% [109,110] and the presence of acute complications (left ventricular out flow tract obstruction, free wall or septal rupture and cardiogenic shock) are independent predictors of poor outcomes (Fig. 3).

## 8. Conclusions

TTC is usually a benign disease course enrolling several variants in accordance to the anatomic distribution of regional wall motion abnormalities that share in common the clinical symptoms, EKG changes, increased cardiac biomarkers, pathophysiology and therapeutic strategies. To date, it seems that diffuse vasospasm and microvascular dysfunction ensuing from adrenergic storm play a crucial role in the pathogenesis of TTC. Searching for potential complications such as left ventricular outflow tract obstruction is essential before starting treatment, especially in patients with hemodynamic instability. Future prospective trials for risk stratification and target medical therapy standardization are required.

## Author contributions

AM—contributed to conception, design and writing of the article; CD, FCP, VN, TL, FB, ME, SB and JR—contributed to conception and design; DC—contributed to design and writing of the article and provided important intellectual contribution to the manuscript.

## Ethics approval and consent to participate

Not applicable.

## Acknowledgment

We would like to express our gratitude to all those who helped us during the writing of the manuscript and thanks to all the peer reviewers for their opinions and suggestions.

## Funding

This research received no external funding.

## Conflict of interest

The authors declare no conflict of interest.

## References

- [1] Ghadri J, Wittstein IS, Prasad A, Sharkey S, Dote K, Akashi YJ, *et al.* International expert consensus document on takotsubo syndrome (part i): clinical characteristics, diagnostic criteria, and pathophysiology. *European Heart Journal*. 2018; 39: 2032–2046.
- [2] Sato H, Tateishi H, Uchida T. Takotsubo-type cardiomyopathy due to multivessel spasm. In: K Kodama, K, Haze M Hori, editors. *Clinical aspect of myocardial injury: from ischemia to heart failure* (pp. 56–64). Kagakuhyoronsha Publishing Co: Tokyo, Japan. 1990.
- [3] Sato T, Hagiwara K, Nishikido A, Miyamoto S, Komiyama K, Matsuno H, *et al.* Takotsubo (ampulla-shaped) cardiomyopathy associated with microscopic polyangiitis. *Internal Medicine*. 2005; 44: 251–255.
- [4] Prasad A, Lerman A, Rihal CS. Apical ballooning syndrome (Tako-Tsubo or stress cardiomyopathy): a mimic of acute myocardial infarction. *American Heart Journal*. 2008; 155: 408–417.
- [5] Previtali M, Repetto A, Panigada S, Camprotondo R, Tavazzi L. Left ventricular apical ballooning syndrome: prevalence, clinical characteristics and pathogenetic mechanism in a European population. *International Journal of Cardiology*. 2009; 134: 91–96.
- [6] Ghadri JR, Cammann VL, Jurisic S, Seifert B, Napp LC, Diekmann J, *et al.* A novel clinical score (InterTAK Diagnostic Score) to differentiate takotsubo syndrome from acute coronary syndrome: results from the International Takotsubo Registry. *European Journal of Heart Failure*. 2018; 19: 1036–1042.
- [7] Napp LC, Cammann VL, Jaguszewski M, Szawan KA, Wischnowsky M, Gili S, *et al.* Coexistence and outcome of coronary artery disease in Takotsubo syndrome. *European Heart Journal*. 2020; 41: 3255–3268.
- [8] Prasad A, Dangas G, Srinivasan M, Yu J, Gersh BJ, Mehran R, *et al.* Incidence and angiographic characteristics of patients with apical ballooning syndrome (takotsubo/stress cardiomyopathy) in the HORIZONS-AMI trial: an analysis from a multicenter, international study of ST-elevation myocardial infarction. *Catheterization and Cardiovascular Interventions*. 2014; 83: 343–348.
- [9] Bybee KA, Prasad A, Barsness GW, Lerman A, Jaffe AS, Murphy JG, *et al.* Clinical characteristics and thrombolysis in myocardial infarction frame counts in women with transient left ventricular apical ballooning syndrome. *The American Journal of Cardiology*. 2004; 94: 343–346.
- [10] Redfors B, Vedad R, Angerås O, Råmunddal T, Petursson P, Haraldsson I, *et al.* Mortality in takotsubo syndrome is similar to mortality in myocardial infarction—a report from the SWEDEHEART registry. *International Journal of Cardiology*. 2016; 185: 282–289.
- [11] Templin C, Ghadri JR, Diekmann J, Napp LC, Bataiosu DR, Jaguszewski M, *et al.* Clinical features and outcomes of takotsubo (stress) cardiomyopathy. *The New England Journal of Medicine*. 2015; 373: 929–938.
- [12] Schneider B, Athanasiadis A, Stöllberger C, Pistner W, Schwab J, Gottwald U, *et al.* Gender differences in the manifestation of tako-tsubo cardiomyopathy. *International Journal of Cardiology*. 2014; 166: 584–588.
- [13] Roshanzamir S, Showkathali R. Takotsubo cardiomyopathy a short review. *Current Cardiology Reviews*. 2014; 9: 191–196.
- [14] Deshmukh A, Kumar G, Pant S, Rihal C, Murugiah K, Mehta JL. Prevalence of Takotsubo cardiomyopathy in the United States.

- American Heart Journal. 2012; 164: 66–71.e1.
- [15] Rozema T, Klein LR. Takotsubo cardiomyopathy: a case report and literature review. *Cardiology in the Young*. 2016; 26: 406–409.
- [16] Gianni M, Dentali F, Grandi AM, Sumner G, Hiralal R, Lonn E. Apical ballooning syndrome or takotsubo cardiomyopathy: a systematic review. *European Heart Journal*. 2007; 27: 1523–1529.
- [17] Sharkey SW, Windenburg DC, Lesser JR, Maron MS, Hauser RG, Lesser JN, *et al.* Natural history and expansive clinical profile of stress (tako-tsubo) cardiomyopathy. *Journal of the American College of Cardiology*. 2010; 55: 333–341.
- [18] Chan C, Elliott J, Troughton R, Frampton C, Smyth D, Crozier I, *et al.* Acute myocardial infarction and stress cardiomyopathy following the Christchurch earthquakes. *PLoS ONE*. 2014; 8: e68504.
- [19] Ghadri JR, Sarcon A, Diekmann J, Bataiosu DR, Cammann VL, Jurisic S, *et al.* Happy heart syndrome: role of positive emotional stress in takotsubo syndrome. *European Heart Journal*. 2018; 37: 2823–2829.
- [20] Lousinha A, Gilkeson R, Bezerra H. Left ventricular outflow tract obstruction and Takotsubo syndrome. *Revista Portuguesa De Cardiologia Portuguese Journal of Cardiology*. 2012; 31: 49–51.
- [21] Berry M, Roncalli J, Lairez O, Elbaz M, Carrié D, Galinier M. Takotsubo cardiomyopathy in a squash player. *Cardiology Research and Practice*. 2011; 2009: 351621.
- [22] Eitel I, von Knobelsdorff-Brenkenhoff F, Bernhardt P, Carbone I, Muellerleile K, Aldrovandi A, *et al.* Clinical characteristics and cardiovascular magnetic resonance findings in stress (takotsubo) cardiomyopathy. *Journal of the American Medical Association*. 2011; 306: 277–286.
- [23] Ennezat PV, Pesenti-Rossi D, Aubert JM, Rachenne V, Bauchart JJ, Auffray JL, *et al.* Transient left ventricular basal dysfunction without coronary stenosis in acute cerebral disorders: a novel heart syndrome (inverted Takotsubo). *Echocardiography*. 2005; 22: 599–602.
- [24] Roncalli J, Carrié D, Fauvel JM, Losordo D. A “hak’s beak” to identify the new transient midventricular Tako-Tsubo syndrome. *International Journal of Cardiology*. 2008; 127: 179–180.
- [25] Matta A, Roncalli J, Elbaz M, Lhermusier T, Parada FC, Bouisset F, *et al.* Mid-ventricular Takotsubo cardiomyopathy with Hawk’s beak appearance: a case report. *American Journal of Case Reports*. 2020; 21: e919563.
- [26] Ghadri JR, Cammann VL, Napp LC, Jurisic S, Diekmann J, Bataiosu DR, *et al.* Differences in the clinical profile and outcomes of typical and atypical takotsubo syndrome. *JAMA Cardiology*. 2016; 1: 335.
- [27] Stiermaier T, Moeller C, Oehler K, Desch S, Graf T, Eitel C, *et al.* Long-term excess mortality in takotsubo cardiomyopathy: predictors, causes and clinical consequences. *European Journal of Heart Failure*. 2017; 18: 650–656.
- [28] Shoukat S, Awad A, Nam DK, Hoskins MH, Samuels O, Higginson J, *et al.* Cardiomyopathy with inverted tako-tsubo pattern in the setting of subarachnoid hemorrhage: a series of four cases. *Neurocritical Care*. 2013; 18: 257–260.
- [29] Y-Hassan S. Clinical features and outcome of pheochromocytoma-induced takotsubo syndrome: analysis of 80 published cases. *The American Journal of Cardiology*. 2017; 117: 1836–1844.
- [30] Y-Hassan S. Clinical features and outcome of epinephrine-induced takotsubo syndrome: analysis of 33 published cases. *Cardiovascular Revascularization Medicine*. 2016; 17: 450–455.
- [31] Aizawa K, Suzuki T. Takotsubo cardiomyopathy: Japanese perspective. *Heart Failure Clinics*. 2013; 9: 243–247.
- [32] Kagiya N, Okura H, Kume T, Hayashida A, Yoshida K. Isolated right ventricular takotsubo cardiomyopathy. *European Heart Journal Cardiovascular Imaging*. 2015; 16: 285.
- [33] Stähli BE, Ruschitzka F, Enseleit F. Isolated right ventricular ballooning syndrome: a new variant of transient cardiomyopathy. *European Heart Journal*. 2012; 32: 1821.
- [34] Elikowski W, Małek M, Łanocha M, Wróblewski D, Angerer D, Kurosz J, *et al.* Reversible dilated cardiomyopathy as an atypical form of takotsubo cardiomyopathy. *Polski Merkuriusz Lekarski: Organ Polskiego Towarzystwa Lekarskiego*. 2013; 34: 219–223. (In Polish)
- [35] Hasan SM, Patel JD, Faluk M, Patel J, Singh P. Takotsubo cardiomyopathy and its variants: a case series and literature review. *Journal of Community Hospital Internal Medicine Perspectives*. 2020; 10: 210–215.
- [36] Boyd B, Solh T. Takotsubo cardiomyopathy. *Journal of the American Academy of Physician Assistants*. 2020; 33: 24–29.
- [37] Amin HZ, Amin LZ, Pradipta A. Takotsubo cardiomyopathy: a brief review. *Journal of Medicine and Life*. 2020; 13: 3–7.
- [38] Pelliccia F, Kaski JC, Crea F, Camici PG. Pathophysiology of takotsubo syndrome. *Circulation*. 2017; 135: 2426–2441.
- [39] Farid A, Dufresne W, Farid B, Amsterdam EA. A stressful situation: takotsubo cardiomyopathy. *The American Journal of Medicine*. 2019; 131: 253–256.
- [40] Wittstein IS, Thieman DR, Lima JA, Baughman KL, Schulman SP, Gerstenblith G, *et al.* Neurohormonal features of myocardial stunning due to sudden emotional stress. *The New England Journal of Medicine*. 2005; 352: 539–548.
- [41] El Mahmoud R, Mansencal N, Pillière R, Leyer F, Abbou N, Michaud P, *et al.* Prevalence and characteristics of left ventricular outflow tract obstruction in Tako-Tsubo syndrome. *American Heart Journal*. 2008; 156: 543–548.
- [42] Medina de Chazal H, Del Buono MG, Keyser-Marcus L, Ma L, Moeller FG, Berrocal D, *et al.* Stress cardiomyopathy diagnosis and treatment. *Journal of the American College of Cardiology*. 2018; 72: 1955–1971.
- [43] Williams R, Arri S, Prasad A. Current concepts in the pathogenesis of takotsubo syndrome. *Heart Failure Clinics*. 2016; 12: 473–484.
- [44] Rodríguez M, Rzechorzek W, Herzog E, Lüscher TF. Misconceptions and facts about takotsubo syndrome. *The American Journal of Medicine*. 2019; 132: 25–31.
- [45] Nef HM, Möllmann H, Troidl C, Kostin S, Voss S, Hilpert P, *et al.* Abnormalities in intracellular Ca<sup>2+</sup> regulation contribute to the pathomechanism of Tako-Tsubo cardiomyopathy. *European Heart Journal*. 2010; 30: 2155–2164.
- [46] Nef HM, Möllmann H, Akashi YJ, Hamm CW. Mechanisms of stress (Takotsubo) cardiomyopathy. *Nature Reviews. Cardiology*. 2010; 7: 187–193.
- [47] Cohen RA, Shepherd JT, Vanhoutte PM. Prejunctional and postjunctional actions of endogenous norepinephrine at the sympathetic neuroeffector junction in canine coronary arteries. *Circulation Research*. 1983; 52: 16–25.
- [48] Jaguszewski M, Osipova J, Ghadri J, Napp LC, Widera C, Franke J, *et al.* A signature of circulating microRNAs differentiates takotsubo cardiomyopathy from acute myocardial infarction. *European Heart Journal*. 2014; 35: 999–1006.
- [49] Ghadri JR, Dougoud S, Maier W, Kaufmann PA, Gaemperli O, Prasad A, *et al.* A PET/CT-follow-up imaging study to differentiate takotsubo cardiomyopathy from acute myocardial infarction. *The International Journal of Cardiovascular Imaging*. 2014; 30: 207–209.
- [50] Galiuto L, De Caterina AR, Porfidia A, Paraggio L, Barchetta S, Locorotondo G, *et al.* Reversible coronary microvascular dysfunction: a common pathogenic mechanism in apical ballooning or tako-tsubo syndrome. *European Heart Journal*. 2010; 31: 1319–1327.

- [51] Uchida Y, Egami H, Uchida Y, Sakurai T, Kanai M, Shirai S, *et al.* Possible participation of endothelial cell apoptosis of coronary microvessels in the genesis of Takotsubo cardiomyopathy. *Clinical Cardiology*. 2010; 33: 371–377.
- [52] Heubach JF, Ravens U, Kaumann AJ. Epinephrine activates both Gs and Gi pathways, but norepinephrine activates only the Gs pathway through human beta2-adrenoreceptors overexpressed in mouse heart. *Molecular Pharmacology*. 2004; 65: 1313–1322.
- [53] Nef HM, Möllmann H, Hilpert P, Troidl C, Voss S, Rolf A, *et al.* Activated cell survival cascade protects cardiomyocytes from cell death in Tako-Tsubo cardiomyopathy. *European Journal of Heart Failure*. 2009; 11: 758–764.
- [54] Zhang Z, Jin S, Teng X, Duan X, Chen Y, Wu Y. Hydrogen sulfide attenuates cardiac injury in takotsubo cardiomyopathy by alleviating oxidative stress. *Nitric Oxide: Biology and Chemistry*. 2018; 67: 10–25.
- [55] Shao Y, Redfors B, Scharin Tang M, Mollman H, Troidl C, Szardien S, *et al.* Novel rat model reveals important roles of beta-adrenoreceptors in stress-induced cardiomyopathy. *International Journal of Cardiology*. 2013; 168: 1943–1950.
- [56] Sachdeva J, Dai W, Kloner RA. Functional and histological assessment of an experimental model of Takotsubo's cardiomyopathy. *Journal of the American Heart Association*. 2015; 3: e000921.
- [57] Camman VL, Sarcon A, Ding KJ, Seifert B, Kato K, Di Vecce D, *et al.* Clinical Features and Outcomes of Patients With Malignancy and Takotsubo Syndrome: Observations From the International Takotsubo Registry. *Journal of the American Heart Association*. 2019; 8: e010881.
- [58] Redfors B, Ali A, Shao Y, Lundgren J, Gan L, Omerovic E. Different catecholamines induce different patterns of takotsubo-like cardiac dysfunction in an apparently afterload dependent manner. *International Journal of Cardiology*. 2015; 174: 330–336.
- [59] Scantlebury DC, Prasad A, Rabinstein AA, Best PJM. Prevalence of migraine and Raynaud phenomenon in women with apical ballooning syndrome (Takotsubo or stress cardiomyopathy). *The American Journal of Cardiology*. 2013; 111: 1284–1288.
- [60] Heggemann F, Hamm K, Kaelsch T, Sueselbeck T, Papavassiliu T, Borggrefe M, *et al.* Global and regional myocardial function quantification in Takotsubo cardiomyopathy in comparison to acute anterior myocardial infarction using two-dimensional (2D) strain echocardiography. *Echocardiography*. 2011; 28: 715–719.
- [61] Heggemann F, Hamm K, Brade J, Streitner F, Doesch C, Papavassiliu T, *et al.* Right ventricular function quantification in Takotsubo cardiomyopathy using two-dimensional strain echocardiography. *PLoS ONE*. 2015; 9: e103717.
- [62] Cai L, Addetia K, Medvedofsky D, Spencer KT. Myocardial strain may be useful in differentiating Takotsubo cardiomyopathy from left anterior descending coronary artery ischemia. *International Journal of Cardiology*. 2017; 230: 359–363.
- [63] Vicario MLE, Caso P, Martiniello AR, Fontanella L, Petretta M, Sardu C, *et al.* Effects of volume loading on strain rate and tissue Doppler velocity imaging in patients with idiopathic dilated cardiomyopathy. *Journal of Cardiovascular Medicine*. 2006; 7: 852–858.
- [64] Dias A, Franco E, Rubio M, Bhalla V, Pressman GS, Amanullah S, *et al.* Usefulness of left ventricular strain analysis in patients with takotsubo syndrome during acute phase. *Echocardiography*. 2018; 35: 179–183.
- [65] Kumar S, Waldenborg M, Bhumireddy P, Ramkissoon K, Loiske K, Innasimuthu AL, *et al.* Diastolic function improves after resolution of takotsubo cardiomyopathy. *Clinical Physiology and Functional Imaging*. 2016; 36: 17–24.
- [66] Eitel I, Lücke C, Grothoff M, Sareban M, Schuler G, Thiele H, *et al.* Inflammation in takotsubo cardiomyopathy: insights from cardiovascular magnetic resonance imaging. *European Radiology*. 2010; 20: 422–431.
- [67] Nakamori S, Matsuoka K, Onishi K, Ichikawa Y, Nakajima H, Ishida M, *et al.* Prevalence and signal characteristics of late gadolinium enhancement on contrast-enhanced magnetic resonance imaging in patients with Takotsubo cardiomyopathy. *Circulation*. 2012; 76: 914–921.
- [68] Rolf A, Nef HM, Möllmann H, Troidl C, Voss S, Conradi G, *et al.* Immunohistological basis of the late gadolinium enhancement phenomenon in tako-tsubo cardiomyopathy. *European Heart Journal*. 2009; 30: 1635–1642.
- [69] Sacha J, Maselko J, Wester A, Szudrowicz Z, Pluta W. Left ventricular apical rupture caused by takotsubo cardiomyopathy—comprehensive pathological heart investigation. *Circulation Journal: Official Journal of the Japanese Circulation Society*. 2007; 71: 982–985.
- [70] Maréchaux S, Fornes P, Petit S, Poisson C, Thevenin D, Le Tourneau T, *et al.* Pathology of inverted Takotsubo cardiomyopathy. *Cardiovascular Pathology: The Official Journal of the Society for Cardiovascular Pathology*. 2008; 17: 241–243.
- [71] Ismail TF, Hsu L, Greve AM, Gonçalves C, Jabbour A, Gulati A, *et al.* Coronary microvascular ischemia in hypertrophic cardiomyopathy a pixel-wise quantitative cardiovascular magnetic resonance perfusion study. *Journal of Cardiovascular Magnetic Resonance*. 2015; 16: 49.
- [72] Weinsaft JW, Kim HW, Crowley AL, Klem I, Shenoy C, Van Assche L, *et al.* LV thrombus detection by routine echocardiography: insights into performance characteristics using delayed enhancement CMR. *JACC Cardiovasc Imaging*. 2011; 4: 702–712.
- [73] Naruse Y, Sato A, Kasahara K, Makino K, Sano M, Takeuchi Y, *et al.* The clinical impact of late gadolinium enhancement in Takotsubo cardiomyopathy: serial analysis of cardiovascular magnetic resonance images. *Journal of Cardiovascular Magnetic Resonance*. 2012; 13: 67.
- [74] Bellera MN, Ortiz JT, Caralt MT, Pérez-Rodon J, Mercader J, Fernández-Gómez C, *et al.* Magnetic resonance reveals long-term sequelae of apical ballooning syndrome. *International Journal of Cardiology*. 2010; 139: 25–31.
- [75] Bathina J, Weiss S, Weintraub WS. Understanding the pathophysiology of apical ballooning syndrome: a step closer. *Expert Review of Cardiovascular Therapy*. 2015; 13: 5–8.
- [76] Ghadri J, Wittstein IS, Prasad A, Sharkey S, Dote K, Akashi YJ, *et al.* International expert consensus document on takotsubo syndrome (part ii): diagnostic workup, outcome, and management. *European Heart Journal*. 2019; 39: 2047–2062.
- [77] Filippo CD, Bacchi B, Di Mario C. Novel aspects of classification, prognosis and therapy in Takotsubo syndrome. *European Cardiology Review*. 2019; 14: 191–196.
- [78] DE Vecchis R, Ariano C. Aldosterone receptor antagonists decrease mortality and cardiovascular hospitalizations in chronic heart failure with reduced left ventricular ejection fraction, but not in chronic heart failure with preserved left ventricular ejection fraction: a meta-analysis of randomized controlled trials. *Minerva Cardioangiologica*. 2018; 65: 427–442.
- [79] Akashi YJ, Musha H, Nakazawa K, Miyake F. Plasma brain natriuretic peptide in takotsubo cardiomyopathy. *Monthly Journal of the Association of Physicians* 2004; 97: 599–607.
- [80] Ramaraj R, Sorrell VL, Movahed MR. Levels of troponin release can aid in the early exclusion of stress-induced (takotsubo) cardiomyopathy. *Experimental and Clinical Cardiology*. 2011; 14: 6–8.
- [81] Yancy CW, Jessup M, Bozkurt B, Butler J, Casey DE Jr, Colvin MM, *et al.* 2017 ACC/AHA/HFSA focused update of the 2013 ACC/AHA guideline for the management of heart failure: a report of the American College of Cardiology/American Heart Association Task Force on Clinical Practice Guidelines and the



- Heart Failure Society of America. *Journal of Cardiac Failure*. 2017; 23: 628–651.
- [82] Struthers AD. Why does spironolactone improve mortality over and above an ACE inhibitor in chronic heart failure? *British Journal of Clinical Pharmacology*. 1999; 47: 479–482.
- [83] Lyon AR, Bossone E, Schneider B, Sechtem U, Citro R, Underwood SR, *et al*. Current state of knowledge on Takotsubo syndrome: a Position Statement from the Taskforce on Takotsubo Syndrome of the Heart Failure Association of the European Society of Cardiology. *European Journal of Heart Failure*. 2016; 18: 8–27.
- [84] Templin C, Ghadri JR, Diekmann J, Napp LC, Bataiosu DR, Jaguszewski M, *et al*. Clinical Features and Outcomes of Takotsubo (Stress) Cardiomyopathy. *The New England Journal of Medicine*. 2015; 373: 929–938.
- [85] Singh K, Carson K, Usmani Z, Sawhney G, Shah R, Horowitz J. Systematic review and meta-analysis of incidence and correlates of recurrence of takotsubo cardiomyopathy. *International Journal of Cardiology*. 2015; 174: 696–701.
- [86] Santoro F, Ieva R, Musaico F, Ferraretti A, Triggiani G, Tarantino N, *et al*. Lack of efficacy of drug therapy in preventing takotsubo cardiomyopathy recurrence: a meta-analysis. *Clinical Cardiology*. 2015; 37: 434–439.
- [87] Yoshioka T, Hashimoto A, Tsuchihashi K, Nagao K, Kyuma M, Ooiwa H, *et al*. Clinical implications of midventricular obstruction and intravenous propranolol use in transient left ventricular apical ballooning (Tako-tsubo cardiomyopathy). *American Heart Journal*. 2008; 155: 526.e1–526.e7.
- [88] Kyuma M, Tsuchihashi K, Shinshi Y, Hase M, Nakata T, Ooiwa H, *et al*. Effect of intravenous propranolol on left ventricular apical ballooning without coronary artery stenosis (apical cardiomyopathy): three cases. *Circulation Journal*. 2003; 66: 1181–1184.
- [89] Santoro F, Ieva R, Ferraretti A, Fanelli M, Musaico F, Tarantino N, *et al*. Hemodynamic effects, safety, and feasibility of intravenous esmolol infusion during takotsubo cardiomyopathy with left ventricular outflow tract obstruction: results from a multicenter registry. *Cardiovascular Therapeutics*. 2017; 34: 161–166.
- [90] Migliore F, Bilato C, Isabella G, Iliceto S, Tarantini G. Haemodynamic effects of acute intravenous metoprolol in apical ballooning syndrome with dynamic left ventricular outflow tract obstruction. *European Journal of Heart Failure*. 2010; 12: 305–308.
- [91] Almendro-Delia M, Núñez-Gil IJ, Lobo M, Andrés M, Vedia O, Sionis A, *et al*. Short- and long-term prognostic relevance of cardiogenic shock in takotsubo syndrome: results from the REKATO registry. *JACC Heart Fail*. 2018; 6: 928–936.
- [92] Isogai T, Matsui H, Tanaka H, Fushimi K, Yasunaga H. Early beta-blocker use and in-hospital mortality in patients with Takotsubo cardiomyopathy. *Heart*. 2016; 102: 1029–1035.
- [93] Glaveckaitė S, Šerpytis P, Pečiūraitė D, Purnaitė R, Valevičienė N. Clinical features and three-year outcomes of Takotsubo (stress) cardiomyopathy: Observational data from one center. *Hellenic Journal of Cardiology*. 2017; 57: 428–434.
- [94] Santoro F, Stiermaier T, Tarantino N, De Gennaro L, Moeller C, Guastafierro F, *et al*. Left ventricular thrombi in Takotsubo syndrome: incidence, predictors, and management: results from the GEIST (German Italian Stress Cardiomyopathy) Registry. *Journal of the American Heart Association*. 2017; 6: e006990.
- [95] Von Känel R, Dimsdale JE. Effects of sympathetic activation by adrenergic infusions on hemostasis *in vivo*. *European Journal of Haematology*. 2000; 65: 357–369.
- [96] Santoro F, Ieva R, Ferraretti A, Ienco V, Carpagano G, Lodispoto M, *et al*. Safety and feasibility of levosimendan administration in takotsubo cardiomyopathy: a case series. *Cardiovascular Therapeutics*. 2014; 31: e133–e137.
- [97] Naegle M, Flammer AJ, Enseleit F, Roas S, Frank M, Hirt A, *et al*. Endothelial function and sympathetic nervous system activity in patients with Takotsubo syndrome. *International Journal of Cardiology*. 2016; 224: 226–230.
- [98] Kato K, Di Vece D, Cammann VL, Micek J, Szawan KA, Bacchi B, *et al*. Takotsubo recurrence. *Journal of the American College of Cardiology*. 2019; 73: 982–984.
- [99] Kurisu S, Sato H, Kawagoe T, Ishihara M, Shimatani Y, Nishioka K, *et al*. Tako-tsubo-like left ventricular dysfunction with ST-segment elevation: a novel cardiac syndrome mimicking acute myocardial infarction. *American Heart Journal*. 2002; 143: 448–455.
- [100] Sobue Y, Watanabe E, Ichikawa T, Koshikawa M, Yamamoto M, Harada M, *et al*. Physically triggered Takotsubo cardiomyopathy has a higher in-hospital mortality rate. *International Journal of Cardiology*. 2017; 235: 87–93.
- [101] D’Ascenzo F, Gili S, Bertaina M, Lannaccone M, Cammane VL, Vece DD, *et al*. Impact of aspirin on takotsubo syndrome: a propensity score-based analysis of the InterTAK Registry. *European Journal of Heart Failure*. 2020; 22: 330–337.
- [102] Brinjikji W, El-Sayed AM, Salka S. In-hospital mortality among patients with Takotsubo cardiomyopathy: a study of the national inpatient sample 2008 to 2009. *American Heart Journal*. 2012; 164: 215–221.
- [103] Wischniewsky MB, Candrea A, Bacchi B, Cammann V, Kato K, Szawan KA, *et al*. Prediction of short- and long-term mortality in takotsubo syndrome: the InterTAK Prognostic Score. *European Journal of Heart Failure*. 2019; 21: 1469–1472.
- [104] Citro R, Rigo F, Previtali M, Ciampi Q, Canterin FA, Provenza G, *et al*. Differences in clinical features and in-hospital outcomes of older adults with tako-tsubo cardiomyopathy. *Journal of the American Geriatrics Society*. 2012; 60: 93–98.
- [105] Stiermaier T, Santoro F, Eitel C, Graf T, Möller C, Tarantino N, *et al*. Prevalence and prognostic relevance of atrial fibrillation in patients with Takotsubo syndrome. *International Journal of Cardiology*. 2018; 245: 156–161.
- [106] El-Battrawy I, Lang S, Ansari U, Behnes M, Hillenbrand D, Schramm K, *et al*. Impact of concomitant atrial fibrillation on the prognosis of Takotsubo cardiomyopathy. *Europace: European Pacing, Arrhythmias, and Cardiac Electrophysiology*. 2018; 19: 1288–1292.
- [107] Madias C, Fitzgibbons TP, Alsheikh-Ali AA, Bouchard JL, Kalsmith B, Garlitski AC, *et al*. Acquired long QT syndrome from stress cardiomyopathy is associated with ventricular arrhythmias and torsades de pointes. *Heart Rhythm*. 2011; 8: 555–561.
- [108] Takashio S, Yamamuro M, Kojima S, Izumiya Y, Kaikita K, Hokimoto S, *et al*. Usefulness of SUM of ST-segment elevation on electrocardiograms (limb leads) for predicting in-hospital complications in patients with stress (takotsubo) cardiomyopathy. *The American Journal of Cardiology*. 2012; 109: 1651–1656.
- [109] El-Battrawy I, Ansari U, Lang S, Behnes M, Schramm K, Fastner C, *et al*. Impact and management of left ventricular function on the prognosis of Takotsubo syndrome. *European Journal of Clinical Investigation*. 2018; 47: 477–485.
- [110] Citro R, Radano I, Parodi G, Di Vece D, Zito C, Novo G, *et al*. Long-term outcome in patients with Takotsubo syndrome presenting with severely reduced left ventricular ejection fraction. *European Journal of Heart Failure*. 2019; 21: 781–789.