



**HAL**  
open science

## Early necrotic skin lesions after a ABO-incompatible kidney transplantation

Julie Belliere, Marion Rolland, Emilie Tournier, Sophie Cassaing, Xavier Iriart, Carle Paul, Nassim Kamar

► **To cite this version:**

Julie Belliere, Marion Rolland, Emilie Tournier, Sophie Cassaing, Xavier Iriart, et al.. Early necrotic skin lesions after a ABO-incompatible kidney transplantation. *Transplant Infectious Disease*, 2019, 21 (6), pp.e13173. 10.1111/tid.13173 . hal-03580069

**HAL Id: hal-03580069**

**<https://ut3-toulouseinp.hal.science/hal-03580069v1>**

Submitted on 18 Feb 2022

**HAL** is a multi-disciplinary open access archive for the deposit and dissemination of scientific research documents, whether they are published or not. The documents may come from teaching and research institutions in France or abroad, or from public or private research centers.

L'archive ouverte pluridisciplinaire **HAL**, est destinée au dépôt et à la diffusion de documents scientifiques de niveau recherche, publiés ou non, émanant des établissements d'enseignement et de recherche français ou étrangers, des laboratoires publics ou privés.

# Early necrotic skin lesions after a ABO-incompatible kidney transplantation: The threat of *Cunninghamella* Spp.

Julie Belliere<sup>1,2</sup>  | Marion Rolland<sup>3</sup> | Emilie Tournier<sup>4</sup> | Sophie Cassaing<sup>5</sup> | Xavier Iriart<sup>5</sup> | Carle Paul<sup>3</sup> | Nassim Kamar<sup>1,6</sup> 

<sup>1</sup>Department of Nephrology, Dialysis and Organ Transplantation, Toulouse University Hospital, Toulouse, France

<sup>2</sup>INSERM U1048, I2MC, University Paul Sabatier, Toulouse, France

<sup>3</sup>Department of Dermatology and Allergology, Toulouse University Hospital, Toulouse, France

<sup>4</sup>Department of Anatomopathology, Toulouse University Hospital, Toulouse, France

<sup>5</sup>Department of Parasitology and Mycology, Toulouse University Hospital, Toulouse, France

<sup>6</sup>INSERM U1043, IFR -BMT, University Paul Sabatier, Toulouse, France

## Correspondence

Julie Belliere, Department of Nephrology, Dialysis and Organ Transplantation, Toulouse University Hospital, Toulouse, France.

Email: julie.belliere@inserm.fr

## Abstract

A 49-year-old man underwent ABO-incompatible kidney transplantation with a living donor. At day 33 post-transplantation, he presented with undiagnosed epilepsy with generalized tonic-clonic seizures. At day 44 post-transplantation, he developed left-sided pneumonia attributed to *Aspergillus fumigatus* and treatment with liposomal amphotericin B was initiated. At day 51 post-transplantation, necrotic skin lesions appeared. DNA sequencing in a fresh cutaneous biopsy finally identified *Cunninghamella* Spp., a member of the order Mucorales. Unfortunately, the necrotic lesions spread, and the patient died at day 60 post-transplantation. This case report highlights the infectious risk related to ABO-incompatible kidney transplantation and suggests a requirement for rapid identification of every skin lesion, even in the early phases of immunosuppression.

## KEYWORDS

ABO-incompatible kidney transplantation, *Cunninghamella*, mucormycosis, necrotic skin lesions

## 1 | CASE REPORT

A 49-year-old man with severe ischemic cardiomyopathy and chronic glomerulonephritis underwent ABO-incompatible kidney transplantation from a living donor after 20 years of dialysis. He received rituximab (375 mg/m<sup>2</sup>), 5 double filtration plasmapheresis sessions, and thymoglobulin (1.25 mg/kg) as initial immunosuppressive treatment, followed by a traditional regimen comprising tacrolimus, mycophenolic acid, and steroids. The surgery was performed under anti-aggregation treatment because of the ischemic cardiomyopathy and heparin due to his history of pulmonary embolism. The urologist performed a uretero-ureteral anastomosis. The post-operative period was marked by several complications:

1. Graft function was delayed. At day 10 post-transplantation, while the creatinine level was 180 μmol/L, the patient experienced abdominal pain, revealing perirenal collection on tomography. Diagnosis of urinoma was established and

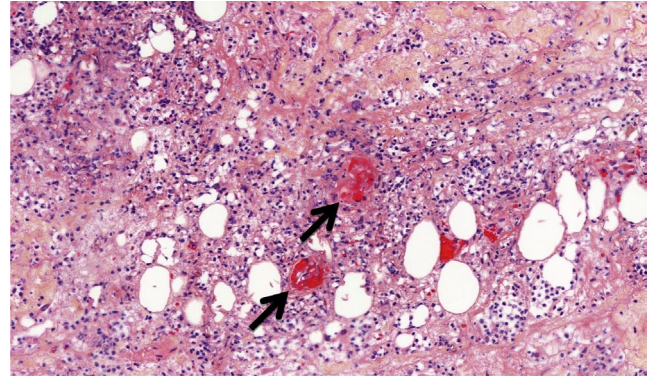
required urine derivation. After several nephrostomy placements, urine output was maintained and the creatinine level dropped from 300 to 90 μmol/L.

2. At day 33 post-transplantation, the patient presented epilepsy with generalized tonic-clonic seizures leading to orotracheal intubation. Electroencephalogram, cerebral MRI, and lumbar puncture did not reveal any abnormalities. No etiology was clearly identified and patient rapidly recovered (extubation at day 38 post-transplantation). A second MRI yielded normal results.
3. At day 44 post-transplantation, the patient presented fever, a productive, bloody cough, and left auscultatory inspiratory crackles. Chest CT scan revealed left-sided pneumonia. A tracheal aspirate culture finally detected the presence of *Aspergillus fumigatus*. Antibacterial treatment, initially relying on Tazobactam-piperacillin, was then supplemented by liposomal amphotericin B (3 mg/kg) at day 44 post-transplantation. The response to treatment was partial: The patient did not require oxygen, and

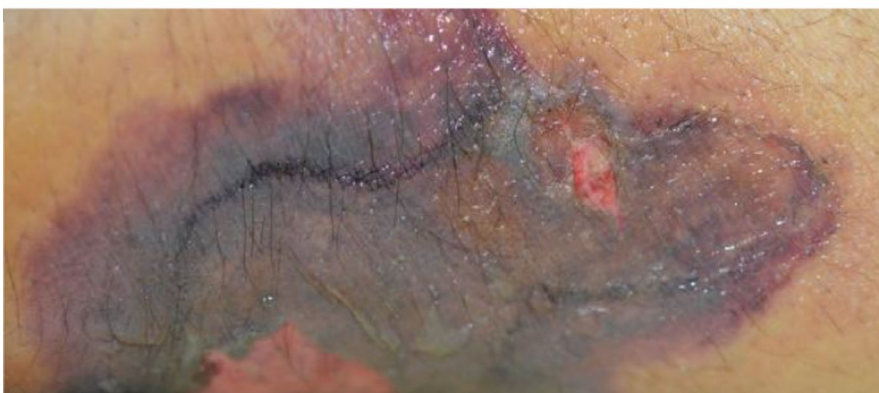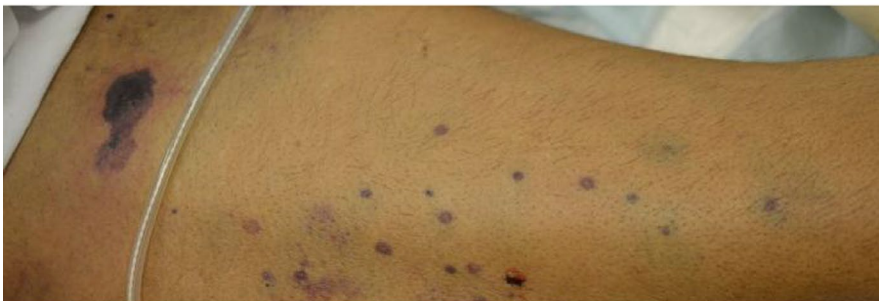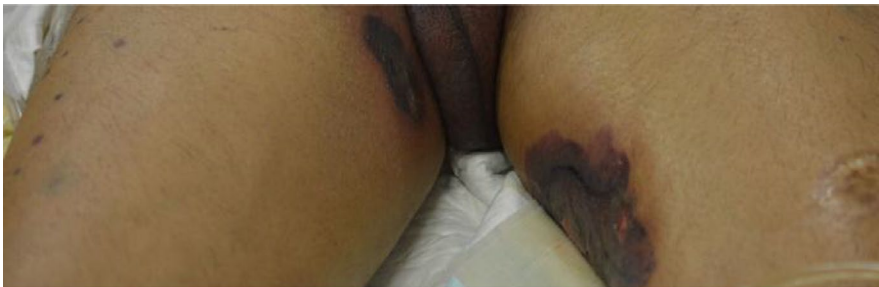some images improved on control scans performed on day 49 post-transplantation.

- At day 46 post-transplantation, a coronarography was performed due to suspicion of myocardial ischemia, but only revealed atheroma.
- At day 51 post-transplantation, necrotic skin lesions appeared (Figure 1). Skin biopsy showed epidermal necrosis and abundant dermal inflammatory infiltrate associated with fibrinoid necrosis of the vessel walls (Figure 2). Fungal organisms were detected using Grocott's methenamine silver staining (Figure 3). Microscopic examination using calcofluor white staining revealed fungal hyphae suggestive of mucormycosis, but the culture on Sabouraud agar medium remained sterile. Skin biopsy and serum samples examined using a combination of three quantitative PCR assays targeting *Rhizomucor*, *Mucor/Rhizopus*, and *Lichtheimia* genera<sup>1</sup> were negative. Direct sequencing of the D1/D2 domain of rDNA,<sup>2</sup> using an ABI 3130 XL apparatus (Applied Biosystem), was performed on the fresh skin biopsy and the serum. Two identical sequences of 419 bp were obtained on both samples and compared to the CBS database (<http://www.westerdijkinstituut.nl/Collections/>

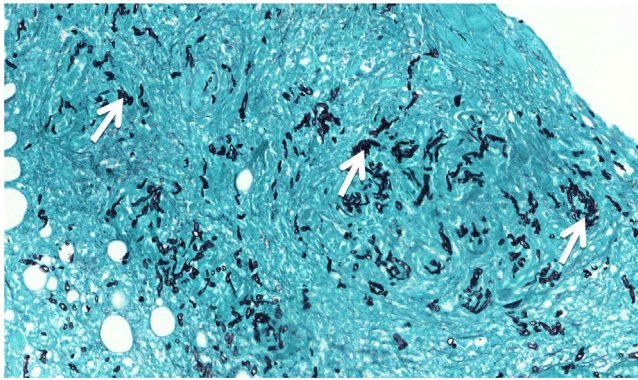
[BioloMICSSequences.aspx](http://www.westerdijkinstituut.nl/Collections/BioloMICSSequences.aspx)). *Cunninghamella* Spp. was finally identified. Nevertheless, it was not possible to distinguish between *Cunninghamella bertholletiae* and *Cunninghamella elegans* (100% overlap and similarity with best-match sequences of the two species—accession number CBS 779.68 and CBS 178.36). Treatment with liposomal amphotericin B



**FIGURE 2** Skin biopsy, ×20 magnification, hematoxylin-eosin staining. Arrows indicate fibrinoid necrosis of the vessel walls



**FIGURE 1** macroscopic view of the necrotic lesions



**FIGURE 3** Skin biopsy,  $\times 20$  magnification, Grocott's methenamine silver staining. Arrows indicate Mucorales filaments

was increased to 10 mg/kg at day 54 post-transplantation, and local skincare was performed. Unfortunately, there was no response to treatment: necrotic lesions rapidly spread, and the patient died at day 60 post-transplantation. No autopsy was performed.

## 2 | DISCUSSION

To our knowledge, this is the first report of cutaneous infection with *Cunninghamella* Spp. in an ABO-incompatible kidney transplant recipient.

Mucormycosis are emerging infections occurring mostly in patients treated for hematological malignancies but also in patients undergoing solid organ transplantation. In France, the overall incidence of invasive fungal infections was 5.9/100 000 cases/year between 2001 and 2010. Mucormycosis represented 1.5% of invasive fungal infections.<sup>3</sup> Whereas in the United States, the average annual percent increase was about 5.2% between 2000 and 2013,<sup>4</sup> in France, incidence increased by 7.8%<sup>3</sup> during the same period. Very high mortality is generally associated with these invasive fungal infections. *Cunninghamella* Spp. are ubiquitous fungi found in the environment (soil, sewage, air, water, and vegetation),<sup>5</sup> and inhalation is the primary means of contamination. *Cunninghamella* Spp. accounts for 7% of reported cases of mucormycosis.<sup>6</sup>

This species is isolated primarily in patients with pulmonary or disseminated disease,<sup>7</sup> which is why cutaneous manifestations are unusual. In our case, the most common alternative hypotheses were suspected initially: catastrophic cholesterol crystal embolism following coronarography, calciphylaxis due to a long history of dialysis, or heparin-related cutaneous necrosis. Direct identification of the pathogen on the cutaneous biopsy allowed this difficult diagnosis to be established. Although diagnosis of mucormycosis is increasingly effective because of the development of specific PCRs,<sup>8</sup> specific diagnosis of *Cunninghamella* infection remains difficult because the combination of qPCR targeting 18S rDNA,<sup>1</sup> widely used to diagnose mucormycosis in France, does not detect this species.

One should remember that kidney transplant patients are the most likely to develop *Cunninghamella* infection among solid organ transplant patients.<sup>5</sup> A table summarizing previous reported infections with *Cunninghamella* Spp is available (Table 1). The infectious risk inherent to transplantation procedure should not be underestimated and Mucorales infections should always be considered, even in the early post-surgery phase. In our case, onset of infection appeared early after transplantation (51 days), consistent with previously reported cases (between 17 days and 12 months).<sup>5</sup> Our patient exhibited neither diabetes mellitus nor neutropenia, which are classical risk factors for mucormycosis. This raises the question of the cumulative immunosuppression related to a long history of dialysis and an intensive ABO desensitization protocol, despite the patient's young age.

This case report underlines the urgency of initiating treatment as soon as possible.<sup>9</sup> Optimal treatment for mucormycosis includes prompt antifungal therapy, surgical debridement, and a decrease in risk factors such as neutropenia or immunosuppressive agents. High doses of liposomal amphotericin B (5–10 mg/kg/d) are recommended as first-line treatment. Posaconazole is used as alternative or salvage therapy line.<sup>10,11</sup> Isavuconazole, a second-generation triazole, is now approved for treatment of mucormycosis when amphotericin is inappropriate. Although the mechanism remains unclear, administration of high-dose liposomal amphotericin B combined with micafungin and lobectomy was used successfully to treat pulmonary infections caused by *Cunninghamella bertholletiae*.<sup>12</sup> In our case, the rapid removal of tacrolimus, mycophenolic acid, and steroids as soon as *Cunninghamella* was identified should have been discussed. However, extensive disease precluded the use of salvage therapy line: Although liposomal amphotericin B was prescribed 7 days before the first clinical signs, our patient died from systemic invasion. It is consistent with the high mortality associated with *Cunninghamella* Spp infections, which is significantly higher than for those caused by other Mucorales. The global mortality rate for Mucorales infections is around 50%.<sup>7</sup>

Strikingly, the patient's initial neurological signs could not be explained by routine exams. We cannot rule out the implication of *Cunninghamella* in the inaugural epilepsy: Cerebral embolism through hematogenous dissemination has recently been reported,<sup>13</sup> as well as isolated cerebral mucormycosis whose diagnosis was made only after surgical exploration.<sup>14</sup> In retrospect, the pulmonary lesions that were attributed to *Aspergillus fumigatus* are not incompatible with *Cunninghamella* infection, as co-infections with Mucorales and *Aspergillus* have been demonstrated.<sup>15</sup>

Finally, infection with *Cunninghamella* Spp. is rare, severe, and difficult to diagnose. In ABO-incompatible kidney transplant recipients, a skin lesion should be considered an emergency. A skin biopsy should be performed as soon as possible in case of any suspect lesion. Skin biopsy remains a safe procedure with high diagnosis yield and will provide rapid positive tissue culture and histologic confirmation of invasive fungal infection.<sup>16</sup> Systematic initiation of amphotericin B should be discussed in the case of necrotic lesions.

**TABLE 1** Previous reported infections with *Cunninghamella* Spp.

Year	First author	Age in years/ gender	Underlying disease	Presenting symptoms	Organ involvement	Treatment	Outcome
2010	Ashkenazi <sup>17</sup>	16/M	Multi-visceral transplantation	Cellulitis	Skin	L-AMB; drainage; posaconazole	Improved
2014	Bhandary <sup>18</sup>	54/M	No (immunocompetent patient)	Corneal ulcer	Eye	Topical medication; ketoconazole	Improved
2012	Bhutadai <sup>19</sup>	52/M	Renal transplantation	Peritonitis on peritoneal dialysis	Abdomen	Fluconazole; catheter removal	Improved
2008	Bibashi <sup>20</sup>	10/M	Leukemia	Pneumonitis	Lung	L-AMB	Died
2014	Carceller <sup>21</sup>	5/M	Leukemia	Pneumonitis	Lung	L-AMB; terbinafine; posaconazole; surgery	Improved
2014	Carceller <sup>21</sup>	17/F	Leukemia, allo-hsct, gvhd	Skin lesions	Skin	L-AMB; terbinafine; posaconazole; surgery	Died
2000	Darrisaw <sup>22</sup>	46/F	Leukemia	Pneumonitis	Lung	L-AMB	Died
2010	Garbino <sup>23</sup>	10/F	Leukemia	Pneumonitis	Lung	L-AMB; voriconazole; posaconazole; surgery	Improved
2001	Garey <sup>24</sup>	52/M	Leukemia	Pneumonitis	Lung	L-AMB; surgery	Died
2011	Gupta <sup>25</sup>	18/F	No (immunocompetent patient)	Fever, cough	Lung	Fluconazole	Improved
2005	Hampson <sup>26</sup>	68/M	Myelodysplasia, diabetes	N/A	Skin inoculation	N/A	Died
2017	Hirano <sup>27</sup>	74/M	Asthma	Pulmonary eosinophilia	Lung	L-AMB	Died
2013	Hirayama <sup>28</sup>	22/F	Hemophagocytic lymphohistiocytosis	Nodular lesions	Lung	N/A	Died
2013	Hsieh <sup>29</sup>	69/M	Leukemia	Pneumonitis	Lung	L-AMB	Died
2006	Jayasuriya <sup>30</sup>	NA	No (immunocompetent patient)	Swelling cheek	Rhinofacial	L-AMB	Improved
2012	Kimura <sup>31</sup>	53/F	Cord blood transplantation	Halo sign	Lung	L-AMB	Died
2017	Kohan <sup>32</sup>	56/M	Renal transplantation	Respiratory	Lung	L-AMB	Died
1983	Kolbeck <sup>33</sup>	40/M	Renal transplantation	Fever	Heart, disseminated	None	Died
2008	Koyama <sup>34</sup>	NA/F	Chronic renal insufficiency	Pneumonitis	Lung	L-AMB	Improved
2019	Liu <sup>35</sup>	50/F	Leukemia	Invasive rhinosinusitis	Sinus	Surgery; L-AMB	Improved
2016	Luo <sup>36</sup>	40/M	Hematopoietic stem cell transplantation	Pneumonitis	Lung	L-AMB; posaconazole	Died
2014	Malkan <sup>37</sup>	15/H	Leukemia	Cough	Lung	L-AMB; surgery	Improved
2018	Margoles <sup>38</sup>	M	Heart transplantation	Myocarditis	Heart	N/A	Died
2014	Matsumoto <sup>39</sup>	61/M	Leukemia	Septic pulmonary embolism	Lung	L-AMB	Died
2011	Mayayo <sup>40</sup>	42/M	Leukemia	Thyroiditis	Thyroid	L-AMB	Died
1989	Mostaza <sup>41</sup>	N/A	Aids	Cutaneous articular	Skin and knee	N/A	N/A
2009	Motohashi <sup>42</sup>	60/F	Leukemia	Eruption, pain	Skin	L-AMB	Died
2010	Mukasa <sup>43</sup>	75/M	Steroid therapy for interstitial pneumonia	Hypoxemia	Lung	L-AMB	Died
2014	Navanukroh <sup>5</sup>	42/F	Renal transplantation	Dry cough, fever	Lung, spine	L-AMB; surgery	Improved

(Continues)

**TABLE 1** (Continued)

Year	First author	Age in years/ gender	Underlying disease	Presenting symptoms	Organ involvement	Treatment	Outcome
1987	Nimmo <sup>44</sup>	19/F	Liver transplantation	Fever	Lung, disseminated	AMB	Died
2004	Ortin <sup>45</sup>	44/M	Leukemia	Myocardial infarct and stroke	Hematological dissemination	L-AMB	Died
2017	Ota <sup>12</sup>	69/F	Leukemia/cord blood transplantation	Fever	Lung	L-AMB; micafungin; surgery	Improved
2017	Ota <sup>12</sup>	35/M	Leukemia/cord blood transplantation	Fever	Lung	L-AMB; micafungin; surgery	Improved
2006	Paul <sup>46</sup>	57/F	Leukemia	Pneumonitis	Lung	L-AMB; voriconazole; posaconazole; surgery	Improved
2006	Pimentel <sup>47</sup>	39/F	Renal failure	Peritonitis on peritoneal dialysis	Abdomen	Voriconazole; catheter removal	Improved
2019	Pomorska <sup>48</sup>	7/F	Leukemia	Respiratory	Lung	Surgery; L-AMB, caspofungin, isavuconazole	Improved
2012	Quillet-Dye <sup>49</sup>	68/M	b-cell lymphoma	Necrotic placards	Skin	Voriconazole	Improved
2004	Quinto <sup>50</sup>	54/M	Renal transplantation	Necrotic placards	Skin	Itraconazole; surgery	Improved
2000	Rickerts <sup>51</sup>	61/F	Renal transplantation	Pneumonitis	Lung	L-AMB; 5 flucytosine	Died
2000	Rickerts <sup>51</sup>	60/F	Leukemia	Pneumonitis	Lung	L-AMB	Died
2000	Rickerts <sup>51</sup>	51/M	Leukemia	Pneumonitis	Lung	L-AMB	Died
2000	Rickerts <sup>51</sup>	55/M	Lymphoma	Pneumonitis	Lung	L-AMB	Improved
2008	Right <sup>52</sup>	41/M	Leukemia	Rhino-mastoiditis	Sinus	L-AMB; surgery	Improved
2015	Santos <sup>53</sup>	N/A	Renal transplantation	N/A	N/A	N/A	Died
2005	Sivakumar <sup>54</sup>	42/M	Leukemia	Pneumonitis	Lung	L-AMB	Died
2016	Su <sup>55</sup>	13/F	Leukemia	Cough, hemoptysis	Lung	L-AMB	Died
2015	Tadepalli <sup>56</sup>	30/M	No (immunocompetent patient)	Onycholysis and onychodystrophy	Onyx	Ciclopirox topical solution 8% along with oral itraconazole 200 mg/twice a day for one week.	N/A
2015	Tan <sup>57</sup>	52/M	Renal transplantation	Pulmonary mass	Lung	N/A	N/A
2019	Uno <sup>58</sup>	73/F	Metastasis from breast cancer	Lung atelectasis	Lung	L-AMB	Died
2005	Vazquez <sup>59</sup>	63/H	Leukemia	Fever	Sinus - brain	L-AMB; caspofungin; surgery	Improved
2016	Yamawaki <sup>60</sup>	84/M	No (immunocompetent patient)	Pneumonitis	Lung	L-AMB; sulbactam/ampicillin, trimethoprim/sulfamethoxazole, voriconazole, levofloxacin	Died
2002	Zhang <sup>61</sup>	48/F	Renal transplantation	Pulmonary mass, stroke	Disseminated	None	Died

Abbreviation: L-AMB, liposomal amphotericin B.

## AUTHOR CONTRIBUTIONS

Julie Belliere was involved in manuscript drafting and revision. Marion Rolland was involved in patient's management and diagnosis. Emilie Tournier was involved in Histopathology interpretation and critical review. Sophie Cassaing and Xavier Iriart were involved in *Cunninghamella* identification, critical review, and revision. Carle Paul was involved in patient's management, diagnosis, and critical review of manuscript. Nassim Kamar was involved in concept, design, and manuscript drafting.

## ORCID

Julie Belliere  <https://orcid.org/0000-0002-4229-8584>

Nassim Kamar  <https://orcid.org/0000-0003-1930-8964>

## REFERENCES

- Millon L, Larosa F, Lepiller Q, et al. Quantitative polymerase chain reaction detection of circulating DNA in serum for early diagnosis of mucormycosis in immunocompromised patients. *Clin Infect Dis*. 2013;56:e95-e101.
- Kurtzman CP, Robnett CJ. Identification of clinically important ascomycetous yeasts based on nucleotide divergence in the 5' end of the large-subunit (26S) ribosomal DNA gene. *J Clin Microbiol*. 1997;35:1216-1223.
- Bitar D, Lortholary O, Le Strat Y, et al. Population-based analysis of invasive fungal infections, France, 2001-2010. *Emerg Infect Dis*. 2014;20:1163-1169.
- Vallabhaneni S, Benedict K, Derado G, Mody RK. Trends in hospitalizations related to invasive Aspergillosis and Mucormycosis in the United States, 2000-2013. *Open Forum Infect Dis*. 2017;ofw268.
- Navanukroh O, Jitmuang A, Chayakulkeeree M, Ngamskulrungraj P. Disseminated *Cunninghamella bertholletiae* infection with spinal epidural abscess in a kidney transplant patient: case report and literature review. *Transpl Infect Dis*. 2014;16:658-665.
- Roden MM, Zaoutis TE, Buchanan WL, et al. Epidemiology and outcome of zygomycosis: a review of 929 reported cases. *Clin Infect Dis*. 2005;41:634-653.
- Jeong W, Keighley C, Wolfe R, et al. The epidemiology and clinical manifestations of mucormycosis: a systematic review and meta-analysis of case reports. *Clin Microbiol Infect*. 2019;25:26-34.
- Millon L, Scherer E, Rocchi S, Bellanger A-P. Molecular strategies to diagnose mucormycosis. *J Fungi (Basel, Switzerland)*. 2019;5:24.
- Jeong W, Keighley C, Wolfe R, et al. The contemporary management and clinical outcomes of mucormycosis: a systematic review and meta-analysis of case reports. *Int J Antimicrob Agents*. 2019;53:589-597.
- Tissot F, Agrawal S, Pagano L, et al. ECIL-6 guidelines for the treatment of invasive candidiasis, aspergillosis and mucormycosis in leukemia and hematopoietic stem cell transplant patients. *Haematologica*. 2017;102:433-444.
- Cornely OA, Cuenca-Estrella M, Meis JF, Ullmann AJ. European Society of Clinical Microbiology and Infectious Diseases (ESCMID) Fungal Infection Study Group (EFISG) and European Confederation of Medical Mycology (ECMM) 2013 joint guidelines on diagnosis and management of rare and emerging fungal diseases. *Clin Microbiol Infect*. 2014;20:1-4.
- Ota H, Yamamoto H, Kimura M, et al. Successful treatment of pulmonary Mucormycosis caused by *Cunninghamella bertholletiae* with high-dose liposomal Amphotericin B (10 mg/kg/day) followed by a lobectomy in cord blood transplant recipients. *Mycopathologia*. 2017;182:847-853.
- Higo T, Kobayashi T, Yamazaki S, et al. Cerebral embolism through hematogenous dissemination of pulmonary mucormycosis complicating relapsed leukemia. *Int J Clin Exp Pathol*. 2015;8:13639-13642.
- Verma A, Brozman B, Petito CK. Isolated cerebral mucormycosis: report of a case and review of the literature. *J Neurol Sci*. 2006;240:65-69.
- Mahomed S, Basanth S, Mlisana K. The successful use of amphotericin B followed by oral posaconazole in a rare case of invasive fungal sinusitis caused by co-infection with mucormycosis and aspergillus. *IDCases*. 2015;2:116-117.
- Berger AP, Ford BA, Brown-Joel Z, Shields BE, Rosenbach M, Wanat KA. Angioinvasive fungal infections impacting the skin. *J Am Acad Dermatol*. 2019;80:883-898.e2.
- Ashkenazi-Hoffnung L, Bilavsky E, Avitzur Y, Amir J. Successful treatment of cutaneous zygomycosis with intravenous amphotericin B followed by oral posaconazole in a multivisceral transplant recipient. *Transplantation*. 2010;90:1133-1135.
- Bhandary S, VijayaPai H, Rao L, Yegneswaran P. *Cunninghamella spinosum* fungal corneal ulcer- first case report. *Indian J Ophthalmol*. 2014;62:375.
- Bhutadal K, BorkarSS, MendirattaDK, ShendeVR. Successful treatment of peritonitis by *C. bertholletiae* in a chronic kidney failure patient on continuous ambulatory peritoneal dialysis after kidney rejection. *Case Rep Singapore Med J*. 2012.
- Bibashi E, Sidi V, Kotsiou M, Makrigrannaki E, Kolioukas D. Pulmonary Zygomycosis caused by *Cunninghamella bertholletiae* in a child with acute lymphoblastic leukemia. *Hippokratia*. 2008;12:43-45.
- Carceller F, Oñoro G, Buitrago MJ, et al. *Cunninghamella bertholletiae* infection in children. *J Pediatr Hematol Oncol*. 2014;36:e109-e114.
- Darrisaw L, Hanson G, Vesole DH, Kehl SC. *Cunninghamella* infection post bone marrow transplant: case report and review of the literature. *Bone Marrow Transplant*. 2000;25:1213-1216.
- Garbino J, Myers C, Ambrosioni J, Gumy-Pause F. Report of a successful treatment of pulmonary *Cunninghamella bertholletiae* infection with liposomal amphotericin and posaconazole in a child with GvHD and review of the literature. *J Pediatr Hematol Oncol*. 2010;32:85-87.
- Garey KW, Pendland SL, Huynh VT, Bunch TH, Jensen GM, Pursell KJ. *Cunninghamella bertholletiae* infection in a bone marrow transplant patient: amphotericin lung penetration, MIC determinations, and review of the literature. *Pharmacotherapy*. 2001;21:855-860.
- Gupta R, Goel N, Gupta A, Gupta KB, Chaudhary U, Sood S. A rare fungal infiltration of lungs in a healthy young girl. *Case Rep Pulmonol*. 2011;2011:1-3.
- Hampson FG, Ridgway EJ, Feeley K, Reilly JT. A fatal case of disseminated zygomycosis associated with the use of blood glucose self-monitoring equipment. *J Infect*. 2005;51:e269-e272.
- Hirano T, Yamada M, Sato K, et al. Invasive pulmonary mucormycosis: rare presentation with pulmonary eosinophilia. *BMC Pulm Med*. 2017;17:76.
- Hirayama Y, Yajima N, Kaimori M, et al. Disseminated infection and pulmonary embolization of *Cunninghamella bertholletiae* complicated with hemophagocytic lymphohistiocytosis. *Intern Med*. 2013;52:2275-2279.
- Hsieh T-T, Tseng H-K, Sun P-L, Wu Y-H, Chen G-S. Disseminated zygomycosis caused by *Cunninghamella bertholletiae* in patient with hematological malignancy and review of published case reports. *Mycopathologia*. 2013;175:99-106.
- Jayasuriya N, Tilakaratne W, Amaratunga E, Ekanayake M. An unusual presentation of rhinofacial zygomycosis due to *Cunninghamella*

- sp. in an immunocompetent patient: a case report and literature review. *Oral Dis.* 2006;12:67-69.
31. Kimura M, Araoka H, Uchida N, et al. *Cunninghamella bertholletiae* pneumonia showing a reversed halo sign on chest computed tomography scan following cord blood transplantation. *Med Mycol.* 2012;50:412-416.
  32. Kohan R, Delgado T, Zakariya-Yousef Brevall, Arbesú CruzA. Pulmonary mucormycosis due to *Cunninghamella* spp. in renal transplant patient. *Rev Esp Quimioter.* 2017;30:472-473.
  33. Kolbeck PC, Makhoul RG, Bollinger RR, Sanfilippo F. Widely disseminated *Cunninghamella* mucormycosis in an adult renal transplant patient: case report and review of the literature. *Am J Clin Pathol.* 1985;83:747-753.
  34. Koyama N, Nagata M, Hagiwara K, Kanazawa M. Survival of a patient with pulmonary *Cunninghamella bertholletiae* infection without surgical intervention. *Respirology.* 2008;13:309-311.
  35. Liu Y-C, Zhou M-L, Cheng K-J, Zhou S-H, Wen X, Chang C-D. Successful treatment of invasive fungal rhinosinusitis caused by *Cunninghamella*: a case report and review of the literature. *World J Clin Cases.* 2019;7:228-235.
  36. Luo C, Wang J, Hu Y, et al. *Cunninghamella bertholletiae* infection in a HLA-haploidentical hematopoietic stem cell transplant recipient with graft failure: case report and review of the literature. *Mycopathologia.* 2016;181:753-758.
  37. Malkan AD, Wahid FN, Rao BN, Sandoval JA. Aggressive *Cunninghamella* pneumonia in an adolescent. *J Pediatr Hematol Oncol.* 2014;36:581-582.
  38. Margoles L, DeNofrio D, Patel AR, et al. Disseminated mucormycosis masquerading as rejection early after orthotopic heart transplantation. *Transpl Infect Dis.* 2018;20:e12820.
  39. Matsumoto K, Yamamoto W, Ohgusa E, et al. Disseminated *Cunninghamella bertholletiae* infection with septic pulmonary embolism after allogeneic bone marrow transplantation. *Transpl Infect Dis.* 2014;16:304-306.
  40. Mayayo E, Klock C, Goldani L. Thyroid involvement in disseminated zygomycosis by *Cunninghamella bertholletiae*: 2 cases and literature review. *Int J Surg Pathol.* 2011;19:75-79.
  41. Mostaza JM, Barbado FJ, Fernandez-Martin J, Peña-Yañez J, Vazquez-Rodriguez JJ. Cutaneoarticular mucormycosis due to *Cunninghamella bertholletiae* in a patient with AIDS. *Clin Infect Dis.* 1989;11(2):316-318.
  42. Motohashi K, Ito S, Hagiwara M, Maruta A, Ishigatsubo Y, Kanamori H. Cutaneous zygomycosis caused by *Cunninghamella bertholletiae* in a patient with chronic myelogenous leukemia in blast crisis. *Am J Hematol.* 2009;84:447-448.
  43. Mukasa Y, Ichiyasu H, Akaike K, Okamoto S, Komohara Y, Kohroggi H. Autopsy case of pulmonary zygomycosis and pneumocystis pneumonia in a patient with interstitial pneumonia treated by corticosteroid therapy. *Nihon Kogyoku Gakkai Zasshi.* 2010;48:847-854.
  44. Nimmo GR, Whiting RF, Strong RW. Disseminated mucormycosis due to *Cunninghamella bertholletiae* in a liver transplant recipient. *Postgrad Med J.* 1988;64:82-84.
  45. Ortín X, Escoda L, Llorente A, et al. *Cunninghamella bertholletiae* infection (mucormycosis) in a patient with acute T-cell lymphoblastic leukemia. *Leuk Lymphoma.* 2004;45:617-620.
  46. Paul S, Marty FM, Colson YL. Treatment of cavitary pulmonary zygomycosis with surgical resection and posaconazole. *Ann Thorac Surg.* 2006;82:338-340.
  47. Pimentel JD, Dreyer G, Lum GD. Peritonitis due to *Cunninghamella bertholletiae* in a patient undergoing continuous ambulatory peritoneal dialysis. *J Med Microbiol.* 2006;55:115-118.
  48. Pomorska A, Malecka A, Jaworski R, et al. Isavuconazole in a successful combination treatment of disseminated mucormycosis in a child with acute lymphoblastic leukaemia and generalized haemochromatosis: a case report and review of the literature. *Mycopathologia.* 2019;184:81-88.
  49. Quillet-Dye C, Meniane J-C, Quist D, Desbois N. Mycoses cutanées à *Cunninghamella bertholletiae*, *Phomopsis* sp. et *Paraconiothyrium* sp. chez un patient immunodéprimé : à propos d'un cas martiniquais. *J Mycol Med.* 2012;22:357-361.
  50. Quinio D, Karam A, Leroy J-P, et al. Zygomycosis caused by *Cunninghamella bertholletiae* in a kidney transplant recipient. *Med Mycol.* 2004;42:177-180.
  51. Rickerts V, Böhme A, Viertel A, et al. Cluster of pulmonary infections caused by *Cunninghamella bertholletiae* in immunocompromised patients. *Clin Infect Dis.* 2000;31:910-913.
  52. Righi E, Giacomazzi CG, Lindstrom V, et al. A case of *Cunninghamella bertholletiae* rhino-cerebral infection in a leukaemic patient and review of recent published studies. *Mycopathologia.* 2008;165:407-410.
  53. Santos T, Aguiar B, Santos L, et al. Invasive fungal infections after kidney transplantation: a single-center experience. *Transplant Proc.* 2015;47:971-975.
  54. Sivakumar S, Mathews MS, George B. *Cunninghamella pneumonia* in postbone marrow transplant patient: first case report from India. *Mycoses.* 2005;48:360-362.
  55. Su Y-Y, Chang T-Y, Wang C-J, et al. Disseminated *Cunninghamella bertholletiae* infection during induction chemotherapy in a girl with high-risk acute lymphoblastic leukemia. *Pediatr Neonatol.* 2016;57:531-534.
  56. Tadepalli K, Gupta PK, Asati DP, Biswas D. Onychomycosis due to *Cunninghamella bertholletiae* in an immunocompetent male from central India. *Case Rep Infect Dis.* 2015;2015:1-4.
  57. Tan M, Gibney EM. Lung mass in a kidney transplant recipient. *Am J Transplant.* 2015;15:281-283.
  58. Uno K, Hishiya N, Matsuda M, et al. Case of endobronchial metastasis from breast cancer accompanied with *Cunninghamella bertholletiae* tracheobronchial mycetoma. *J Infect Chemother.* 2019.
  59. Vazquez L, Mateos JJ, Sanz-Rodriguez C, Perez E, Caballero D, San Miguel JF. Successful treatment of rhinocerebral zygomycosis with a combination of caspofungin and liposomal amphotericin B. *Haematologica.* 2005;90:ECR39.
  60. Yamawaki S, Nakashima K, Suzuki F, et al. Rice-field drowning-associated pneumonia in which *Pseudomonas* spp., *Aspergillus fumigatus*; and *Cunninghamella*; sp. are isolated. *Intern Med.* 2016;55:825-829.
  61. Zhang R, Zhang JW, Szerlip HM. Endocarditis and hemorrhagic stroke caused by *Cunninghamella bertholletiae* infection after kidney transplantation. *Am J Kidney Dis.* 2002;40:842-846.

**How to cite this article:** Belliere J, Rolland M, Tournier E, et al. Early necrotic skin lesions after a ABO-incompatible kidney transplantation: The threat of *Cunninghamella* Spp.. *Transpl Infect Dis.* 2019;21:e13173. <https://doi.org/10.1111/tid.13173>