



HAL
open science

A case of *Trichophyton mentagrophytes* infection in a fennec fox (*Vulpes zerda*)

Charline Pressanti, Maxence Delverdier, Xavier Iriart, Frédérique Morcel, Marie-Christine Cadiergues

► **To cite this version:**

Charline Pressanti, Maxence Delverdier, Xavier Iriart, Frédérique Morcel, Marie-Christine Cadiergues. A case of *Trichophyton mentagrophytes* infection in a fennec fox (*Vulpes zerda*). *Veterinary Dermatology*, 2012, 23 (5), pp.456-e87. 10.1111/j.1365-3164.2012.01077.x . hal-03572801

HAL Id: hal-03572801

<https://ut3-toulouseinp.hal.science/hal-03572801v1>

Submitted on 14 Feb 2022

HAL is a multi-disciplinary open access archive for the deposit and dissemination of scientific research documents, whether they are published or not. The documents may come from teaching and research institutions in France or abroad, or from public or private research centers.

L'archive ouverte pluridisciplinaire **HAL**, est destinée au dépôt et à la diffusion de documents scientifiques de niveau recherche, publiés ou non, émanant des établissements d'enseignement et de recherche français ou étrangers, des laboratoires publics ou privés.

A case of *Trichophyton mentagrophytes* infection in a fennec fox (*Vulpes zerda*)

Charline Pressanti*, Maxence Delverdier*, Xavier Iriart†, Frédérique Morcel* and Marie-Christine Cadiergues*

*INP-ENVT Toulouse veterinary school 23, chemin des Capelles, 31076 Toulouse Cedex 3, France

†Parasitology-Mycology service, Centre Hospitalier-Universitaire Hôpital Rangueil, 31059 Toulouse Cedex 9/UMR 152 IRD-UPS, Université Paul Sabatier Toulouse III, Toulouse, France

Correspondence: Marie-Christine Cadiergues, INP-ENVT Toulouse veterinary school 23, chemin des Capelles, 31076 Toulouse Cedex 3, France.
E-mail: mc.cadiergues@envt.fr

A 2-year-old male fennec fox presented with a 4 month history of nonpruritic, crusty skin lesions on the forehead, the pinnae and the tail tip.

Initial investigations, including routine haematology, biochemistry profile, multiple skin scrapings, trichoscopic examination, Wood's lamp examination and fungal culture, failed to reveal any abnormalities. Histopathological examination of a first set of skin biopsies showed an interface dermatitis pattern, with lymphocyte infiltration in the basal layer, a significant lymphocytic exocytosis and occasional apoptotic basal epidermal keratinocytes; periodic acid Schiff stain did not reveal any fungal elements. On further biopsies, there was a pustular neutrophilic dermatitis, with numerous crusts containing high numbers of arthrospores and fungal hyphae. *Trichophyton mentagrophytes* infection was confirmed on fungal culture and PCR.

The fennec fox received oral itraconazole (5 mg/kg once daily for 6 weeks) combined with a miconazole and chlorhexidine shampoo applied on affected areas once weekly, followed with an enilconazole dip. The fox improved dramatically, and a fungal culture performed at 6 weeks was negative. Unfortunately, a few days later the fennec fox developed anorexia, icterus and died.

To the authors' knowledge, this is the first report of *Trichophyton* infection in a fennec fox and, although a post-mortem examination was not performed, this is possibly the first report of fatal acute liver failure associated with itraconazole in a canid.

Introduction

The fennec fox (*Vulpes zerda*) is a small nocturnal fox found in the Sahara desert, classified into the family *Canidae* of the order *Carnivora*. The fennec fox is the smallest species of *Canidae* in the world; coat, ears and kidney functions have adapted to a high-temperature, low-water and desert environment. The fennec fox's fur is prized by the indigenous peoples of North Africa, and in some parts of the world the animal is considered an exotic pet. Fennec foxes are in Appendix II of the Convention on International Trade in Endangered Species of Wild Fauna and Flora (CITES) and considered threatened in the wild. There is little reported in the veterinary literature regarding disease conditions of fennec foxes; therefore, new information regarding medical conditions in this species is of particular interest.

Case report

A 2-year-old, 1200 g, male fennec fox (*Vulpes zerda*) presented with a 4 month history of nonpruritic, crusty skin

lesions on the forehead, the pinnae and the tail tip. He lived in a private zoo with a female, who did not have any skin lesions at the time of the consultation. There was a previous history of similar lesions on the bridge of the nose and the pinnae, which had not responded to empirical systemic griseofulvin and topical enilconazole 4 months previously. No other health problems were reported by the zoo keeper. Routine haematology and biochemistry profile had been unremarkable. The fennec was hospitalized in an individual kennel, and precautions were taken to avoid direct and indirect contact with other animals. A clinical examination did not reveal any abnormalities. Dermatological examination revealed alopecia and moderate erythema on the convex aspect of the pinnae and the ear margins. Numerous yellow crusts and large scales were additionally present (Figure 1); underneath these, the skin was bright and slightly exudative. Similar lesions, though less severe, were noted around the eyes, on the tail tip and on the bridge of the nose (Figure 2).

The initial differential diagnoses included parasitic infestations (demodicosis, leishmaniosis), infectious dermatitides (dermatophytosis, bacterial pyoderma), primary cornification disorder (sebaceous adenitis), pemphigus complex and, less likely, cutaneous lymphoma.

Multiple skin scrapings and trichoscopic examination failed to reveal any mites or fungi. Wood's lamp examination and fungal cultures (carpet square method) were

Accepted 20 May 2012

Sources of Funding: This study was self funded.

Conflict of Interest: No conflicts of interest have been declared. This case was presented as an oral communication at the British Veterinary Dermatology Study Group autumn meeting (Manchester, UK, November 2011).

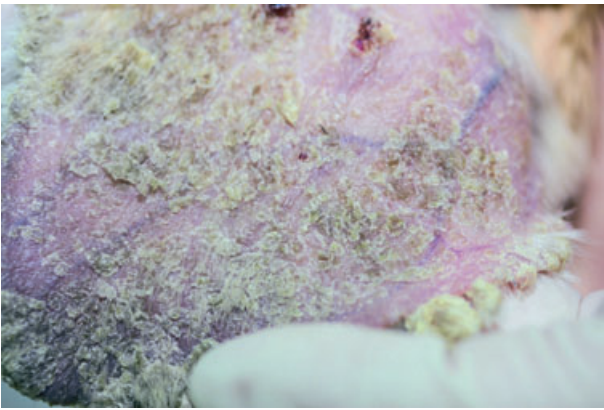


Figure 1. Close view of the convex aspect of the pinna. Numerous yellow crusts and large scales are present.



Figure 2. Alopecia and crusty lesions on the bridge of the nose.

negative. Microscopic examination of Diff-Quick stained impression smears revealed neutrophils with a few acantholytic cells and numerous coccoid bacteria. Oral cefalexin (Therios 60; Laboratoire Sogeval, Laval, France) 20 mg/kg twice daily was prescribed for 3 weeks, but lesions failed to improve. The fennec fox was then anaesthetized with isoflurane (ISOFLU 100%; Axience SAS, Pantin, France; induction via induction chamber and maintenance via facemask). Four 6-mm-punch biopsy samples were obtained from pinnal lesional skin and submitted for histopathological examination. There was epidermal regular acanthosis, laminated hyperkeratosis and mild multifocal spongiosis. An interface dermatitis with lymphocyte infiltration was observed in the basal layer. A significant lymphocytic exocytosis and occasional apoptotic basal epidermal keratinocytes were also present (Figure 3). In the dermis, a widespread interstitial infiltrate was mainly composed of plasma cells and macrophages. The specific periodic acid Schiff staining did not reveal any fungal elements.

Skin biopsies were collected 1 month later, with the same anaesthetic protocol. The histopathological findings were completely different. There was a pustular neutrophilic dermatitis with numerous crusts containing high numbers of arthrospores and fungal hyphae. The presence of fungal elements was confirmed with periodic acid Schiff staining (Figure 4).

Fungal culture of scales and crusts was also repeated and showed a growth of 10 colonies after 1 week. The colonies had a creamy appearance and a powdery surface. Irregularly shaped and sized macroconidia with three to nine septa, pear-shaped or more elongated microconidia attached at right-angles along the sides of hyphae and numerous coiled spirals were observed microscopically, allowing the identification of *Trichophyton mentagrophytes*. This diagnosis was confirmed by sequencing, using fungus-specific universal primers to amplify the ITS1 region [ITS1 (5'-TCCGTAGGTGAACC TGCGG-3'); ITS2 (5'-GCTGCGTTCTTCATCGATGC-3')].¹ The PCR product was then sequenced in an ABI-PRISM3100 (Applied Biosystems, Foster City, CA, USA). One sequence of 330 bp was obtained and compared against the CBS database (<http://www.cbs.knaw.nl/collections/BioloMICSSequences.aspx?file=all>), confirm-

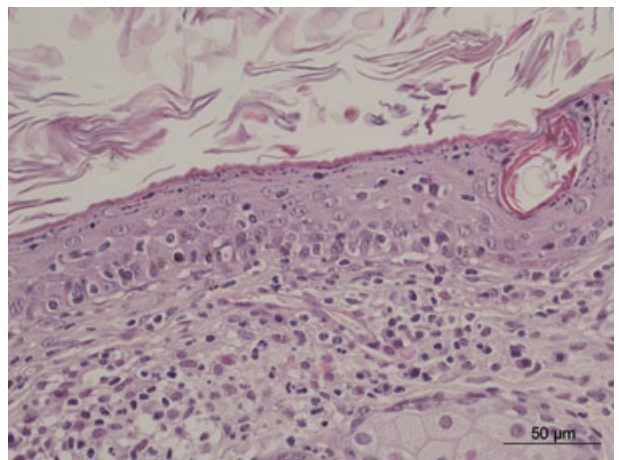


Figure 3. First set of skin biopsies. Photomicrograph showing epidermal regular acanthosis, laminated hyperkeratosis and interface dermatitis with lymphocytic exocytosis; haematoxylin and eosin stain.

ing the diagnosis of *Trichophyton mentagrophytes* (var. *erinacei*) infection (99.05% of identities with the best-match sequence—accession number 677.86).

Although data regarding epidemiology and therapy were lacking for fennec foxes, a fair prognosis was given and therapy was started, based on recommendations for dogs, i.e. combining systemic and topical treatments. Itraconazole was given orally at 5 mg/kg once daily (Itrafungol; Lilly France SA, Suresnes, France) for 6 weeks. A miconazole and chlorhexidine shampoo (Malaseb shampoo; Dechra Veterinary Products SAS, Suresnes, France) was applied on affected areas once weekly, followed by an enilconazole dip (Imaveral; Lilly France SA, Suresnes, France).

A good clinical improvement, with evidence of hair regrowth, was obtained. A fungal culture performed at 6 weeks was negative. Fungal medication was then stopped. Unfortunately, a few days later, the fennec fox developed anorexia and jaundice. Liver failure was confirmed on the biochemistry profile by elevation of alanine aminotransferase (>1000 UI/L; reference range

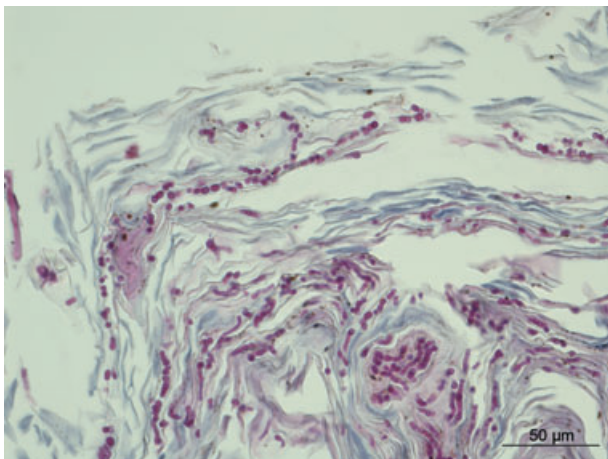


Figure 4. Second set of skin biopsies. High-power photomicrograph showing high numbers of arthrospores and fungal hyphae in the stratum corneum; periodic acid Schiff stain.

35–162 UI/L), alkaline phosphatase (2040 UI/L; reference range 16–142 UI/L) and total bilirubin (221 $\mu\text{mol/L}$; reference range 1.7–5.1 $\mu\text{mol/L}$). Despite intravenous fluid infusion, the fennec fox deteriorated and died. The body could not be obtained for postmortem examination.

Discussion

This case illustrates the challenging diagnosis of *Trichophyton* dermatophytosis and the difficulty in selecting therapeutic protocols for exotic animals due to lack of data. Mycological culture remains the most reliable technique for confirming dermatophytosis.² In this case, the carpet square method proved ineffective on its own to collect fungal spores, which were located in the superficial layers of the stratum corneum but not widespread in the haircoat. It would have been preferable to collect crusts and scales, which might have increased fungal culture sensitivity. Moreover, the histopathological examination failed to show arthrospores or hyphae in the samples, even after careful re-examination of the slides once a definitive diagnosis had been established. Although histopathological examination is less sensitive than fungal culture, most of the time this technique is efficient and useful to reveal fungal infection. In *Trichophyton* infection, fungal arthrospores and hyphae are often difficult to observe and far less numerous than in *Microsporum canis* infection.³ Alternatively, the very few fungal elements contained in the most superficial layers of the skin (crusts and scales) could have detached during formalin fixation.

The first biopsy series showed an interface dermatitis pattern on histopathological examination. This particular presentation without observation of fungal elements introduced confusion. The histopathological features of dermatophytosis commonly consist of suppurative luminal folliculitis, sometimes associated with furunculosis.^{3,4} Much less frequently, acantholysis can be associated with dermatophytosis, which both clinically and histologically resembles superficial pemphigus. This has been mainly reported with *Trichophyton* spp. and *Micro-*

sporum persicolor, which preferentially colonize the epidermal surface keratin.^{5–8} Acantholysis is ascribed to keratinases and other proteolytic enzymes produced by the fungi.⁵ Acantholytic keratinocytes were observed on the initial cytological examination, most probably caused by the concurrent bacterial infection, but acantholysis was not confirmed on histopathology. In very few cases, dermatophytosis shows as an interface-like dermatitis, with an inflammatory reaction restricted to the superficial dermis and the follicular wall. In dogs, a case series of *Trichophyton* infections was described, and in all four cases, histopathological findings suggested an immune-mediated disease and more specifically, pemphigus erythematosus, combining an acantholytic intraepidermal pustular dermatitis and a severe epidermal and follicular interface dermatitis.⁹ More recently, in a retrospective study of 16 cases of dermatophytosis due to *M. persicolor*, a lichenoid interface dermatitis was present in all 10 cases that were biopsied.¹⁰ This pattern seems to be more common in *Trichophyton* and in *M. persicolor* (formerly named *Trichophyton persicolor*) infections. *Trichophyton* spp. could be less adapted to the host and hence induce a more intense cell-mediated immune response than the better adapted *M. canis*.^{9,11–13}

Dermatophytes are usually identified on the basis of macroscopic and microscopic characteristics of fungal colonies obtained on specific media.² Molecular biology techniques, such as RT-PCR, can be used successfully with high specificity and sensitivity.¹ Nevertheless, this method remains a research tool. The PCR test requires a preliminary fungal culture and isolation of dermatophytes from the very numerous contaminants found in pets and wild animals. In a previous study, PCR test permitted the distinction between two different species of *T. mentagrophytes* complex: *Arthroderma benhamiae* and *Arthroderma vanbreuseghemii*.¹⁴ The first type seemed to be more common in guinea pigs and the second type in cats and dogs with outdoor living conditions in rural areas.¹⁵ In the present case, the PCR test did not permit the distinction between the two species. Nevertheless, the macroscopic and microscopic features were most consistent with *A. benhamiae*.

No bibliographic data are available concerning treatment of dermatophytosis in the fennec fox. Systemic itraconazole in a liquid form seemed to be most appropriate, considering its greater safety than ketoconazole^{2,16} and its ease of administration. With regard to the topical therapy, the skin was carefully dried after each application to minimize stress, hypothermia and possible oral intake. Itraconazole is believed to carry a lower risk of hepatic toxicity than ketoconazole. In humans, hepatic failure caused by itraconazole is very rare.^{17,18} Acute liver failure due to itraconazole is not reported in dogs. Postmortem examination could not be performed, leaving uncertainty about itraconazole toxicity causative of the death of the fennec fox. To the best of our knowledge, in addition to being the first report of dermatophytosis in a fennec fox, although a complete postmortem examination could not be performed, this is possibly the first report of fatal acute liver failure caused by itraconazole in a canid species.

References

1. Ciardo DE, Lucke K, Imhof A *et al.* Systematic internal transcribed spacer sequence analysis for identification of clinical mold isolates in diagnostic mycology: a 5-year study. *J Clin Microbiol* 2010; 48: 2809–2813.
2. Bond R. Superficial veterinary mycoses. *Clin Dermatol* 2010; 28: 226–236.
3. Fairley RA. The histological lesions of *Trichophyton mentagrophytes* var *erinacei* infection in dogs. *Vet Dermatol* 2001; 12: 119–122.
4. Gross T, Ihrke P, Walder E *et al.* *Skin Diseases of the Dog and Cat: Clinical and Histopathologic Diagnosis*, 2nd edn. Oxford: Blackwell Science Ltd, 2005, 413–414.
5. Hino H, Kobayashi T, Asboe-Hansen G. Acantholysis induced by proteolytic enzymes. I. Porcine pancreatic elastase. *Acta Derm Venereol* 1982; 62: 277–282.
6. Scott D. Marked acantholysis associated with dermatophytosis due to *Trichophyton equinum* in two horses. *Vet Dermatol* 1994; 5: 105–110.
7. Peters J, Scott DW, Erb HN *et al.* Comparative analysis of canine dermatophytosis and superficial pemphigus for the prevalence of dermatophytes and acantholytic keratinocytes: a histopathological and clinical retrospective study. *Vet Dermatol* 2007; 18: 234–240.
8. Droual R, Bickford AA, Walker RL *et al.* Favus in a backyard flock of game chickens. *Avian Dis* 1991; 35: 625–630.
9. Parker WM, Yager JA. *Trichophyton* dermatophytosis – a disease easily confused with pemphigus erythematosus. *Can Vet J* 1997; 38: 502–505.
10. Muller A, Guaguère E, Degorce-Rubiales F *et al.* Dermatophytosis due to *Microsporum persicolor*: a retrospective study of 16 cases. *Can Vet J* 2011; 52: 385–388.
11. Almeida SR. Immunology of dermatophytosis. *Mycopathologia* 2008; 166: 277–283.
12. Wagner DK, Sohnle PG. Cutaneous defenses against dermatophytes and yeasts. *Clin Microbiol Rev* 1995; 8: 317–335.
13. Romani L. The T cell response against fungal infections. *Curr Opin Immunol* 1997; 9: 484–490.
14. Ninet B, Jan I, Bontems O *et al.* Identification of dermatophyte species by 28S ribosomal DNA sequencing with a commercial kit. *J Clin Microbiol* 2003; 41: 826–830.
15. Drouot S, Mignon B, Fratti M *et al.* Pets as the main source of two zoonotic species of the *Trichophyton mentagrophytes* complex in Switzerland, *Arthroderma vanbreuseghemii* and *Arthroderma benhamiae*. *Vet Dermatol* 2009; 20: 13–18.
16. Foy DS, Trepanier LA. Antifungal treatment of small animal veterinary patients. *Vet Clin North Am Small Anim Pract* 2010; 40: 1171–1188.
17. Chang CH, Young-Xu Y, Kurth T *et al.* The safety of oral antifungal treatments for superficial dermatophytosis and onychomycosis: a meta-analysis. *Am J Med* 2007; 120: 791–798.
18. Gupta AK, Chwetzoff E, Del Rosso J *et al.* Hepatic safety of itraconazole. *J Cutan Med Surg* 2002; 6: 210–213.

Résumé

Un renard fennec mâle de 2 ans présente des lésions cutanées croûteuses, non prurigineuses sur la tête, les pavillons auriculaires et l'extrémité de la queue.

Les premiers examens comprenant une hématologie de routine, un profil biochimique, de multiples raclages cutanés, un trichogramme, un examen à la lampe de Wood et une culture fongique n'ont révélé aucune anomalie. Un examen histopathologique d'une première série de biopsies cutanées a montré une dermatite d'interface, un infiltrat lymphocytaire de la couche basale, une exocytose lymphocytaire significative et d'occasionnels kératinocytes apoptotiques épidermiques basaux; une coloration à l'acide périodique de Schiff n'a révélé aucun élément fongique. Sur des biopsies supplémentaires, on observait une dermatite pustuleuse neutrophilique avec de nombreuses croûtes contenant un grand nombre d'arthrospores et d'hyphes fongiques. La culture fongique et une PCR ont permis de confirmer une infection à *Trichophyton mentagrophytes*.

L'animal a reçu de l'itraconazole oral (5 mg/kg une fois par jour pendant 6 semaines) associé à des shampoings de miconazole et de chlorhexidine appliqués sur les zones atteintes une fois par semaine puis suivi de bain d'énilconazole. Une amélioration considérable a été observée et une culture fongique réalisée après 6 semaines était négative. Malheureusement, après quelques jours, le fennec est devenu anorexique, ictérique et n'a pas survécu.

A la connaissance des auteurs, ceci est le premier rapport d'une infection à *Trichophyton* chez un renard fennec et bien qu'aucun examen postmortem n'ait été réalisé, ceci est probablement la première fois qu'une insuffisance hépatique aigue fatale associée à l'itraconazole est rapportée chez un canidé.

Resumen

Un fennec macho de 2 años se presentó con una historia de 4 meses de lesiones no pruriginosas de la piel y con costras en la frente, los pabellones auriculares y la extremidad de la cola.

Las investigaciones iniciales, incluyendo hematología rutinaria, perfil de bioquímica sanguínea, raspados múltiples de la piel, examen tricoscópico, examen con lámpara de Wood y cultivo de hongos no revelaron ninguna anomalía. El examen histopatológico de una primera toma de biopsias de la piel demostró un patrón de dermatitis de interfase, con infiltración de linfocitos en el estrato basal de la epidermis, exocitosis importante de linfocitos y algunos queratinocitos basales en apoptosis; la tinción ácida periódica de Schiff no desveló la presencia de hongos. En nuevas biopsias se observó una dermatitis neutrofílica con pustulas, y en las costras había un elevado número de artrosporas y de hifas de hongos. Se confirmó una infección por *Trichophyton mentagrophytes* mediante cultivo y PCR.

El fennec recibió itraconazol oral (5 mg/kg una vez al día durante 6 semanas) combinado con un champú de miconazol y de clorhexidina aplicado en áreas afectadas una vez a la semana, seguido de una inmersión en enilconazol. El animal mejoró dramáticamente, y un cultivo de hongos realizado a las 6 semanas fue negativo. Desafortunadamente, algunos días después el fennec desarrolló anorexia, icterus y murió al poco tiempo.

A nuestro entender este es el primer informe de infección por *Trichophyton* en un fenec y aunque la autopsia no fue realizada, éste posiblemente sea el primer caso de fallo hepático agudo asociado con el tratamiento con itraconazol en un cánido.

Zusammenfassung

Ein 2-Jahre alter männlicher Wüstenfuchs wurde mit der Anamnese einer bereits 4 Monate andauernden Erkrankung vorgestellt, die sich in Form von juckenden, krustigen Hautveränderungen an der Stirn, an den Pinnae und an der Schwanzspitze äußerte.

Mit den anfänglichen Untersuchungen, bestehend aus routinemäßiger Hämatologie, Biochemie, multiplen Hautgeschabseln, trichoskopischer Untersuchung, Untersuchung mit der Wood Lampe und Pilzkultur konnten keine Abweichungen gezeigt werden. Die histopathologische Untersuchung der ersten Hautbiopsien zeigte das Muster einer Interface Dermatitis, mit einer Lymphozyteninfiltration in die Basalschicht, einer signifikanten Lymphozytenexozytose und gelegentlichen apoptotischen basalen epidermalen Keratinozyten; mittels einer Periodic-acid Schiff Färbung konnten keine Pilzelemente gefunden werden. Auf weiteren Biopsien zeigte sich eine pustulöse neutrophile Dermatitis mit zahlreichen Krusten, die eine hohe Zahl an Arthrosporen und Pilzhypen beinhalteten. Eine *Trichophyton mentagrophytes* Infektion wurde mittels Pilzkultur und PCR bestätigt.

Der Wüstenfuchs erhielt Itrakonazol (5 mg/kg einmal täglich für 6 Wochen) *per os* in Kombination mit einem Mikonazol-Chlorhexidin Shampoo, welches einmal wöchentlich an den betroffenen Stellen verwendet wurde. Danach wurde ein Enilikonazol Dip aufgetragen. Es folgte eine dramatische Verbesserung und eine weitere Pilzkultur, die 6 Wochen später durchgeführt wurde, war negativ. Unglücklicherweise entwickelte der Wüstenfuchs wenige Tage danach Anorexie und Ikterus und verstarb.

Nach dem besten Wissen der Autoren handelt es sich hierbei um den ersten Bericht einer *Trichophyton* Infektion bei einem Wüstenfuchs. Obwohl keine Sektion durchgeführt wurde, handelt es sich hierbei möglicherweise um den ersten Bericht eines fatalen akuten Leberversagens im Zusammenhang mit Itrakonazolverabreichung bei einem Caniden.

要約

2歳齢の雄のフェネックギツネが、4ヶ月前から額、耳介、尾の先に非そう痒性の痂皮を伴う皮膚病変を示すということで来院した。

一般血液検査と生化学検査ならびに複数箇所からの皮膚搔爬検査、被毛検査などの初期検査を行った。ウッド灯検査と真菌培養では異常所見はなかった。最初の皮膚生検による病理組織学的な検査では、基底膜へのリンパ球浸潤、リンパ球の表皮内細胞浸潤、ときに基底膜側の表皮ケラチノサイトのアポトーシスを伴う境界部皮膚炎が認められた；過ヨウ素酸シッフ染色では真菌成分は認められなかった。さらなる生検にて、多数の分節胞子と菌糸を含む複数の痂皮を伴う膿胞性好中球性皮膚炎が認められた。*Trichophytonmentagrophytes* 感染が真菌培養とPCRにて確認された。

フェネックギツネにはイトラコナゾール（5 mg/kg 1日1回6週間）を経口投与し、ミコナゾール、クロルヘキシジン配合シャンプーで患部をシャンプーした後に、エニルコナゾールへの浸漬を週に1回行った。症状は劇的に改善し、6週間後に実施した真菌培養は陰性であった。不運なことに、数日後にフェネックの食欲は減退、黄疸が認められ死亡した。

筆者の知るところにおいて、これはフェネックギツネでの *Trichophyton* 感染症の最初の報告で、剖検は行われなかったが、イヌ科動物でのイトラコナゾールによる、最初の致死的な急性肝不全の報告である可能性がある。

摘要

一只 2 岁雄性非洲狐有四个月的皮肤病史，无瘙痒，前额、耳廓和尾尖可见结痂性皮肤病变。

最初的调查研究，包括常规的血液病学、全面生化检查、多张皮肤刮片、毛发形态检查、伍德氏灯检查和真菌培养，未发现任何异常情况。首次的一套皮肤活检采样，显示界面性皮炎模式，基底层伴有淋巴细胞浸润，显著的淋巴细胞胞吐和偶见基部表皮角质形成细胞的凋亡；高碘酸希夫染色未发现真菌元素。之后的活检可见脓疱性中性粒细胞皮炎，很多结痂含有大量分生孢子和菌丝。经真菌培养和PCR确定为须毛癣菌感染。

这只非洲狐口服伊曲康唑（5 mg/kg，每天一次，持续 6 周），并应用咪康唑和氯己定香波每周一次清洗患处，随后使用恩康唑浸泡。皮肤改善显著，在 6 周时进行真菌培养，结果阴性。不幸的是，几天后这只非洲狐出现厌食、黄疸并死亡。

作者所知，这是首例非洲狐须毛癣菌感染的报道，尽管未进行尸体剖检，这可能是首例与伊曲康唑有关的犬科动物肝功能衰竭致死的报道。