



HAL
open science

Control of canine idiopathic nasal hyperkeratosis with a natural skin restorative balm

Mathilde Catarino, Daniel Combarros-Garcia, Philippe Mimouni, Charline Pressanti, Marie Cadiergues

► To cite this version:

Mathilde Catarino, Daniel Combarros-Garcia, Philippe Mimouni, Charline Pressanti, Marie Cadiergues. Control of canine idiopathic nasal hyperkeratosis with a natural skin restorative balm. *Veterinary Dermatology*, 2018, 29 (2), pp.134-e53. 10.1111/vde.12506 . hal-03536727

HAL Id: hal-03536727

<https://ut3-toulouseinp.hal.science/hal-03536727v1>

Submitted on 21 Jan 2022

HAL is a multi-disciplinary open access archive for the deposit and dissemination of scientific research documents, whether they are published or not. The documents may come from teaching and research institutions in France or abroad, or from public or private research centers.

L'archive ouverte pluridisciplinaire **HAL**, est destinée au dépôt et à la diffusion de documents scientifiques de niveau recherche, publiés ou non, émanant des établissements d'enseignement et de recherche français ou étrangers, des laboratoires publics ou privés.

Control of canine idiopathic nasal hyperkeratosis with a natural skin restorative balm: a randomized double-blind placebo-controlled study

Mathilde Catarino*, Daniel Combarros-Garcia*, Philippe Mimouni†, Charline Pressanti* and Marie C. Cadiergues‡ 

*Université de Toulouse, ENVT, 23 chemin des Capelles, 31076 Toulouse, France

†Clinique vétérinaire "les Poumadères", Centre de Reproduction des Carnivores du Sud-Ouest (CRECS), 32600 Isle Jourdain, France

‡UDEAR, Université de Toulouse, INSERM, ENVT, 23 chemin des Capelles, 31076 Toulouse, France

Correspondence: Marie C. Cadiergues, Université de Toulouse, ENVT, 31076 Toulouse cedex3, France. E-mail: mc.cadiergues@envt.fr

Background – Nasal hyperkeratosis may cause discomfort in dogs by predisposing them to fissures and secondary bacterial infection. Approaches to treatment have been described anecdotally; the effectiveness of such therapies remains unproven.

Hypothesis/Objectives – To investigate the efficacy of a balm containing essential oils and essential fatty acids in dogs with idiopathic nasal hyperkeratosis.

Animals – Client-owned dogs with noncomplicated nasal hyperkeratosis.

Methods – The study was conducted as a randomized, double-blind, placebo-controlled clinical trial with parallel group design and two month follow-up period. Dogs received daily topical application of a commercial balm product (group DBB) or placebo (aqueous gelling agent with preservatives, group PB). The main outcome variables were lichenification, dryness, suppleness and extent of lesions. Subjective owner satisfaction index score was a secondary variable. Evaluation was performed on days (D)0, 30 and 60. Response to treatment was assessed as the change from baseline to each examination day for each criterion.

Results – Forty eight dogs, principally French (26 of 48) and English (seven of 48) bulldogs, were included and 39 completed the study. No major adverse events were reported. On D60, changes from baseline for lichenification, lesion extent, suppleness and total score were –31.2%, –18.3%, –72.8% and –36.8% in group DBB (23 dogs) and –11.9%, 2.3%, –42.1% and –14% in group PB (16 dogs), respectively. The total score was significantly improved on D60 in group DBB compared to PB (Wilcoxon–Mann–Whitney *U*-test, $P = 0.0016$).

Conclusions and clinical importance – The balm proved safe and helpful in managing canine idiopathic non-complicated nasal hyperkeratosis.

Introduction

Canine nasal hyperkeratosis reflects an excessive multiplication of keratinocytes, their retention or a lack of desquamation. The planum nasale, which is normally smooth, pliable and shiny, becomes dry, firm and hyperplastic.¹ Nasal hyperkeratosis can be secondary to a large variety of diseases, including distemper, leishmaniasis, pemphigus foliaceus, systemic lupus erythematosus,

zinc-responsive dermatosis, cutaneous lymphoma or necrolytic migratory erythema.² In otherwise healthy animals, this clinical presentation may be observed as a congenital hereditary disorder (as in Labrador retrievers),³ as a senile change, or because of nasal anatomical abnormalities.³ Nasal hyperkeratosis can be associated with footpad hyperkeratosis in some cases, usually with a similar aetiology.²

When nasal hyperkeratosis is not associated with a systemic disease or other skin signs, it is often solely a cosmetic issue and does not necessarily justify treatment. However, it can lead to fissuring, bleeding and secondary bacterial or fungal infections which may be associated with pain. When there is no primary cause that can be addressed, treatment aims to soften and remove the excessive keratinized material. In idiopathic cases, life-long treatment is usually required. Treatments reported for idiopathic hyperkeratosis include mechanical removal of excessive keratin and topical application of agents such as petroleum jelly, propylene glycol, salicylic acid, ichthammol ointment or tretinoin gel.^{2,4} These interventions have produced variable outcomes,⁵ and can be

Abbreviations: DBB, Dermoscent BIO BALM®; PB, placebo.

Accepted 14 September 2017

Sources of funding This study was partly funded by LDCA, Castres, France, including provision of the DBB product.

Conflicts of interest Mathilde Catarino's veterinary thesis was partly supported by LDCA. Daniel Combarros-Garcia, Philippe Mimouni and Charline Pressanti have no conflict of interest to declare. Marie C. Cadiergues has been a consultant for LDCA. This study was presented at the European Society of Veterinary Dermatology-European College of Veterinary Dermatology annual congress, 2015, Krakow, Poland. *Vet Dermatol* 2015; 26: 303 (Abstract)

time-consuming and difficult to apply to noncooperative animals.

Dermoscent BIO BALM® (LDCA; Castres, France) has been developed as a balm to maintain the hydration and suppleness of the nose, paws and calluses. It is composed of the essential oil of *Melaleuca cajuputi*, soybean oil, allantoin and cetyl palmitate, and contains no preservatives or petroleum jelly. We evaluated the efficacy and safety of a daily application of Dermoscent BIO BALM® on the nose of client-owned healthy dogs with idiopathic nasal hyperkeratosis. Our objectives were (i) to determine whether a daily application of the balm for a 60 day period would improve nasal lesions (primary outcome) and (ii) to evaluate owner satisfaction and record any adverse events (secondary outcomes).

Materials and methods

Study design

The study was conducted as a randomized, double-blind, placebo-controlled clinical trial with parallel group design and two month follow-up period. Privately owned dogs were used, and both owner consent and approval from the University Ethical Committee were obtained prior to enrolling subjects.

Enrolment criteria

Client-owned dogs, irrespective of breed, sex or age, with an increased thickness of the nasal planum were enrolled. Dogs were excluded if they have received any treatment that could have modified the appearance of the planum nasale during the six weeks prior to inclusion. Dogs presenting with ulceration, depigmentation, atrophy or purulent crusts on the nose or a systemic disease that could affect the nose also were excluded from the study.

Study protocol

All dogs were evaluated by the same investigator (MC) at days (D) 0, D30 and D60. At the beginning of each visit, each dog went through a general and dermatological examination aimed at detecting any abnormalities that could fulfil the exclusion criteria.

A lesion scale assessing the following four parameters was developed by the investigators for the purpose of conducting this study and has not yet been validated independently (Table 1). Scoring was always performed at least 12 hours after the most recent application of the product. Lichenification was scored from 0 (normal nose) to 4 (exophytic projections of keratin); dryness was scored 0 if the nose was moist, or 1 if the nose was dry; suppleness was scored from 0 (spongy tissue and supple surface)

to 2 (solid tissue and firm surface); and the extent of lesions was scored from 0 (no lesions) to 4 (the whole nose was affected). These four criteria scores were summed to establish the total clinical score. Thus, the higher the total score (maximum =11), the more pronounced were the lesions.

At each follow-up visit (D30 and D60) owners were asked to evaluate the product and its efficacy using scales developed by the investigators for this particular study: (i) a Visual Analog Scale (VAS) extending from severe worsening of the clinical signs to marked improvement; (ii) a numerical scale which evaluated both the owner's satisfaction and the estimated efficacy of the product on a scale of 0 to 10; and (iii) a verbal scale which evaluated the owner's overall satisfaction (not at all, slightly, moderately or very satisfied).

Tolerance

Tolerance was assessed by monitoring and recording adverse events (AEs) and withdrawals at any time during the study. Owners were asked to report any AE, even if its occurrence was not necessarily caused by or related to the product.

Study products

Dogs were randomly allocated to the Dermoscent BIO BALM® (DBB) or the placebo balm (PB) groups using an online tool (<http://biostat.med.univ-tours.fr/mediawiki/images/biostat/ListeRandom.php>). Dog owners and the primary investigator were blinded to group assignments. Owners in the PB group received a 50 g jar, identical in appearance to DBB but containing aqueous gelling agent with preservatives. Owners were asked to apply a small quantity of the product (approximately one Finger Tip Unit) and massage onto the nose once daily in the evening or just prior to walking or feeding, if possible. Owners were asked not to make any comments about the colour, odour or consistency of the product during the visits.

Concomitant treatments

During the study period, any other topical treatment for the nose or systemic treatment that could affect the appearance of the nose (e.g. corticosteroids, retinoids, essential fatty acid supplementation) was prohibited.

Statistical procedures

Data were analysed using the software Graphpad Prism (Graphpad Software, Inc.; La Jolla, CA, USA). An intention-to-treat analysis was performed. The normality of data was assessed by the D'Agostino & Pearson omnibus and Shapiro–Wilk tests. When data were not normally distributed, the Wilcoxon–Mann–Whitney *U*-test was used to compare the medians of two independent samples for each criterion at D0 and D60 and the total score. Differences with a *P*-value <0.05 were considered to be statistically significant. Owner evaluations were not subjected to statistical analysis.

Table 1. Clinical scoring system for dogs with idiopathic nasal hyperkeratosis

Criterion	Score	Details
Dryness	0	Humid
	1	Dry
Suppleness	0	Spongy nose associated with a supple surface
	1	Spongy nose associated with a firm surface
	2	Solid nose associated with a firm surface
Extension	0	No visible lesion
	1	One affected alar fold or only the junction with the muzzle <1 mm
	2	Both alar folds affected or the junction with the muzzle >1 mm
	3	Whole dorsal part affected
	4	Whole nose affected
Lichenification	0	None (normal planum nasale)
	1	Mild (normal dermatoglyphic pattern*, no detachment)
	2	Moderate (marked thickening, no detachment)
	3	Intense (very marked thickening with detachment)
	4	Severe (keratinized exophytic projections)

*Dermatoglyphics refers to the formation of naturally occurring ridges on certain body parts.

Results

Study population

A total of 48 dogs were enrolled. Nine cases did not complete the study. One dog was withdrawn before D60 because adverse reactions occurred (sneezing, nasal pruritus) and the other eight were withdrawn for owners' personal reasons. One case was not taken in consideration for analysis because of the inability to contact the owners after D10. From the 47 dogs that were included in the analyses, 24 were males and 23 were females. French bulldogs and English bulldogs were most commonly represented ($n = 26$; 55% and $n = 7$; 15%, respectively), followed by pugs and Boxers ($n = 3$; 6%), and Boston terriers ($n = 2$; 4%). All other breeds were represented by a single dog. Mean age at enrolment was 4.4 years (range 6 months to 11 years) with 51.1% of dogs under the age of three and 30.4% over the age of eight. Twenty six dogs were allocated to the treatment (DBB) group and 21 to the PB group. The distribution of dog characteristics between groups (age, sex, breed and clinical baseline) showed no statistically significant differences, suggesting adequate randomization procedures.

Lesions

Data were not normally distributed. The Wilcoxon–Mann–Whitney U -test confirmed a statistical difference between the treatment groups. The total score was reduced by 36.8% after 60 days in the DBB group and by 14% in the PB group ($P = 0.0016$). Statistically significant improvements ($P < 0.05$) for each of the individual parameters were also observed (Table 2, Figure 1). Suppleness and lichenification were the individual criteria that improved the most within the 60 days, reaching 72.8% and 31.2%, respectively. In the PB group, the extent of lesions increased slightly (+2.3%) during the 60 day period and the suppleness score in the PB group declined by -42.1%.

Owner's satisfaction survey

The opinions of 31 owners were collected. Responses are reported as descriptive data. Using the VAS, a moderate to marked improvement of the nasal lesions was observed

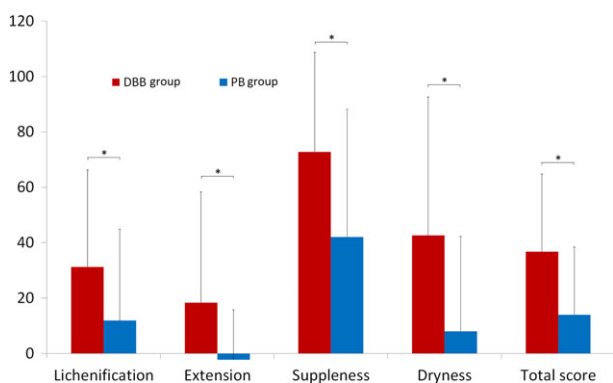


Figure 1. Percentage reduction and standard deviation of clinical scores up to day 60 for dogs receiving Dermoscent BIO BALM® (DBB) or placebo balm (PB) for nasal hyperkeratosis. An asterisk (*) represent a significant difference between the two groups ($P < 0.05$).

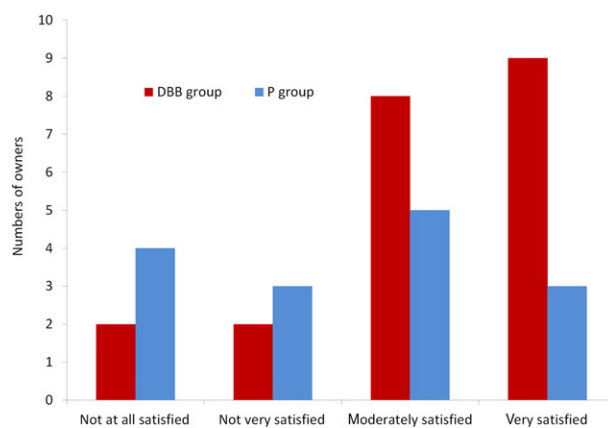


Figure 2. Efficacy of the treatment evaluated by the owners, expressed in numbers of owners per category. DBB dogs received Dermoscent BIO BALM® product; PB placebo balm group.

by the owners in 81% of the DBB group against 44.4% of the PB group. In the latter, 27.8% of the owners did not notice any change in the nasal appearance and 16.7% even noticed a worsening of the lesions. Using the numerical scale, owners rated the effectiveness of DBB as 7.25 of 10 versus 5.28 of 10 for PB. Seven owners (29%) did not appreciate the use of the product because of its odour, the reluctance of the dog to receive the application, or the greasy and liquid consistency of the balm at warm temperatures. Using the verbal scale, 42.9% of owners in the DBB group were very satisfied with the response to treatment versus only 20% in the PB group; 26.7% of owners in the PB group were “not at all satisfied” versus only 9.5% in the DBB group (detailed results are presented in Figure 2). Some owners in the DBB (two of three) noticed a clear and rapid improvement of the lesions until D30 with no additional change thereafter, and one owner reported a more progressive and gradual progression until D60.

Assessment of safety

Three of 26 cases (11.5%) in the DBB group reported the occurrence of an AE. Erythema of the skin surrounding the nose was observed. This sign resolved spontaneously a few hours after removal of the remaining product. The three cases were associated with difficulty in application of the balm (the product was being applied not only on the planum nasale but also on the bridge of the haired skin just caudal to the nasal planum). Two of these cases were exposed to hot temperatures and direct sunlight. No AEs were reported in the placebo group.

Discussion

There are no controlled trials reporting on the treatment of localized hyperkeratosis in dogs. The present study provides evidence for the usefulness of DBB in controlling uncomplicated nasal hyperkeratosis, with each of the efficacy variables assessed being significantly better for the DBB-treated dogs than for the placebo-treated dogs. Lichenification and suppleness were the individual criteria showing most improvement in the treated group (31.2%

Table 2. Mean (\pm standard deviation) scoring results and percentage of reduction for dogs with nasal hyperkeratosis receiving Dermoscent BIO BALM[®] (DBB) or placebo balm (PB) over a 60 day period

	Clinical score (mean \pm SD)				Percentage reduction in score (%) (mean \pm SD)	
	D0	D30	D60	D60–D0	From D0 to D30	From D0 to D60
Lichenification (L) (0–4)						
DBB	2.3 \pm 0.8	1.7 \pm 0.7	1.6 \pm 0.9	0.7 \pm 0.8	28.3 \pm 28	31.2 \pm 35.1
PB	2.4 \pm 0.7	2.2 \pm 0.7	2.2 \pm 0.7	0.3 \pm 0.7	8.6 \pm 23.5	11.9 \pm 33
Extension (E) (0–4)						
DBB	2.6 \pm 0.8	2.3 \pm 0.9	2.1 \pm 1.1	0.5 \pm 0.8	10.1 \pm 32	18.3 \pm 40
PB	2.2 \pm 0.8	2.2 \pm 0.8	2.2 \pm 0.8	0.1 \pm 0.4	8.6 \pm 12	-2.3 \pm 18
Suppleness (S) (0–2)						
DBB	1.6 \pm 0.5	0.8 \pm 0.7	0.4 \pm 0.6	1.1 \pm 0.6	49.4 \pm 39.5	72.8 \pm 36
PB	1.5 \pm 0.5	1.2 \pm 0.7	0.9 \pm 0.8	0.7 \pm 0.6	23.0 \pm 40.8	42.1 \pm 46
Dryness (D) (0–1)						
DBB	0.6 \pm 0.5	0.6 \pm 0.5	0.4 \pm 0.4	0.3 \pm 0.5	4.9 \pm 34	42.6 \pm 50
PB	0.5 \pm 0.5	0.3 \pm 0.5	0.5 \pm 0.5	0.1 \pm 0.4	38 \pm 47.9	8 \pm 34.2
Total score (L + E + S + D)						
DBB	7.1 \pm 2.3	5.7 \pm 2.2	4.5 \pm 2.4	2.6 \pm 1.9	24.4 \pm 25	36.8 \pm 28
PB	6.7 \pm 2.0	5.9 \pm 2.3	5.7 \pm 2.3	0.9 \pm 1.4	11.3 \pm 19.35	14 \pm 24.4

An asterisk (*) represents a significant difference between the two groups ($P < 0.05$).

and 72.8%, respectively), with a total score reduction of 36.8% after 60 days of a daily application. One of the limitations of the study is the use of a nonvalidated outcome scale with unknown intra- and interobserver reliability. However, all the dogs were evaluated blind, at each visit, by the same investigator which should have reduced observational biases.

It can be hypothesized that the positive outcomes observed in this study resulted from the combination of the various active ingredients contained in DBB. The essential oil of *M. cajuputi* contains different molecules including 1,8-cineole, with strong mucolytic, expectorant and anti-inflammatory properties,^{6,7} and other monoterpenes and sesquiterpenes with antimicrobial and analgesic properties.^{8–10} Soybean oil is the main excipient of the product and contains vitamins (A, D, E and K) and essential fatty acids (linoleic, linolenic and oleic acids).^{11,12} Allantoin acts as a moisturizer of the epidermis,¹³ favours desquamation by destruction of intercellular cohesive elements,¹⁴ and stimulates skin cicatrization.^{15–17} Cetyl palmitate, another excipient which is often used in cosmetic products, creates an impermeable film that prevents transepidermal water loss and therefore contributes to hydration and prolonged residence time of active ingredients.¹⁸

Clinical improvement was also observed in the placebo group and may have been due to the moisturizing properties of the excipients. Apart from the different molecules contained in the balm, the gentle massage performed when applying the product may have also contributed to improvement via mechanical removal of the excess keratin. Although each owner had received similar instructions and demonstrations at the beginning of the study, some may have been more assiduous in applying the balm and massaging the affected area.

In hereditary nasal parakeratosis of Labrador retrievers, clinical improvement has been reported with application of propylene glycol, topical vitamin E or petroleum jelly, used separately.^{2,5} This highlights the importance of topical management and the direct action of emollient and moisturizing agents in addition to mechanical removal of

crusts. Combining active ingredients with emollients, as in the tested product, may enhance efficacy. A clear improvement in clinical signs was observed after the first 30 days of treatment. This progression was less obvious during the second month. Other clinical studies should be performed to determine the ideal frequency of application for maintenance. However, this factor may be dog-dependent as we observed marked differences in the degree and rapidity of improvement between individuals (Figure S1). Therefore, each case should be managed based on the clinician's observations.

Minor AEs were observed in three of 26 dogs (11.5%) treated with DBB; manifest as alopecia and erythema of the skin around the nose which could represent contact or irritant dermatitis. Some components of the balm – such as the limonene present in cajeput essential oil – can be oxidized at high temperatures,¹⁹ and may cause photosensitization. The clinician should inform the owner of this possible AE and advise the application of the product on the nose only, avoiding the surrounding haired skin. The product should be applied in the evening when possible to avoid direct sunlight and higher temperatures. The balm should be stored at cool temperatures (15–25°C) and should not be exposed to sunlight.¹⁹

In conclusion, we have demonstrated that a balm containing cajeput and soybean oil, allantoin and cetyl palmitate (Dermoscent BIO BALM[®]) is efficacious and well tolerated in the treatment of uncomplicated nasal hyperkeratosis of healthy dogs. When possible, manual removal of excess keratin should be associated with the topical application of the product to increase the effectiveness of the treatment.

References

- Gross TL, Ihrke PJ, Walder EJ et al. *Skin Diseases of the Dog and Cat: Clinical and Histopathologic Diagnosis*, 2nd edition. Oxford, UK: Blackwell Science Ltd; 2005. p944.
- Miller WH, Griffin CE, Campbell KL. *Muller and Kirk's Small Animal Dermatology*, 7th edition. St Louis, MO: Elsevier Mosby, 2013; 639–640.

3. Page N, Paradis M, Lapointe JM et al. Hereditary nasal parakeratosis in Labrador Retrievers. *Vet Dermatol* 2003; 14: 103–110.
4. Power H, Ihrke P. The use of synthetic retinoids in veterinary medicine. In: Bonagura J, ed. *Current Veterinary Therapy XII: Small Animal Practice*. Philadelphia, PA: Saunders, 1995; 573–581.
5. Peters J, Scott DW, Erb HN et al. Hereditary nasal parakeratosis in Labrador retrievers: 11 new cases and a retrospective study on the presence of accumulations of serum ('serum lakes') in the epidermis of parakeratotic dermatoses and inflamed nasal plana of dogs. *Vet Dermatol* 2003; 14: 197–203.
6. Juergens UR. Anti-inflammatory properties of the monoterpene 1,8-cineole: current evidence for co-medication in inflammatory airway diseases. *Drug Res (Stuttg)* 2014; 64: 638–646.
7. Santos FA, Rao VS. Anti-inflammatory and antinociceptive effects of 1,8-cineole a terpenoid oxide present in many plant essential oils. *Phytother Res* 2000; 14: 240–244.
8. Al-Abd NM, Mohamed Nor Z, Mansor M et al. Antioxidant, antibacterial activity, and phytochemical characterization of *Melaleuca cajuputi* extract. *BMC Complement Altern Med* 2015; 15: 385.
9. Falci SP, Teixeira MA, Chagas PF et al. Antimicrobial activity of *Melaleuca* sp. oil against clinical isolates of antibiotics resistant *Staphylococcus aureus*. *Acta Cir Bras* 2015; 30: 491–496.
10. Silva C, Barbosa L, Demuner A et al. Chemical composition and antibacterial activities from the essential oils of myrtaceae species planted in Brazil. *Quim Nova* 2010; 33: 104–108.
11. Arora M, Singh S, Kaur R. Phytochemical analysis, protein content and antimicrobial activities of selected samples of *Glycine max* linn. *Int J Sci Res Sci Eng Technol* 2013; 2: 570–574.
12. Ghahari S, Alinezhad H, Nematzadeh GA et al. Chemical Composition, Antioxidant and Biological Activities of the Essential Oil and Extract of the Seeds of *Glycine max* (soybean) from North Iran. *Curr Microbiol* 2017; 74: 522–531.
13. Draelos ZD. Botanicals as topical agents. *Clin Dermatol* 2001; 19: 474–477.
14. Henning T. Evaluation of the efficacy of Allantoin. *Euro Cosmetics* 2001; 9: 20–23.
15. Loots JM, Loots GP, Joubert WS. The effect of allantoin on cellular multiplication in degenerating and regenerating nerves. *S Afr Med J* 1979; 55: 53–56.
16. Posner A. Allantoin its properties and uses. *J Cosmetic Science* 1958; 9: 58–51.
17. Shestopalov AV, Shkurat TP, Mikashinovich ZI et al. [Biological functions of allantoin; in Russian]. *Izv Akad Nauk Ser Biol* 2006: 541–545.
18. Mandawgade SD, Patravale VB. Development of SLNs from natural lipids: application to topical delivery of tretinoin. *Int J Pharm* 2008; 363: 132–138.
19. Turek C, Stintzing FC. Stability of Essential Oils: A Review. *Compr Rev Food Sci Food Saf* 2013; 12: 40–53.

Supporting Information

Additional Supporting Information may be found in the online version of this article.

Figure S1. Photographs of the clinical appearance of the nasal planum of dogs treated for nasal hyperkeratosis.

Résumé

Contexte – L'hyperkératose nasale peut être inconfortable pour les chiens, celle-ci pouvant évoluer en fissures et en infections secondaires. Des approches thérapeutiques anecdotiques ont été décrites; leur efficacité n'est pas prouvée.

Hypothèses/Objectifs – Étudier l'efficacité d'un baume contenant des huiles essentielles et des acides gras essentiels chez les chiens atteints d'hyperkératose nasale idiopathique.

Sujets – Les chiens de propriétaires avec une hyperkératose nasale non compliquée.

Méthodes – L'étude a été randomisée, en double aveugle, contrôlée contre placebo avec un groupe parallèle et un suivi de 2 mois. Les chiens recevant une application topique quotidienne d'un baume commercial (groupe DBB) ou un placebo (gélifiant aqueux avec conservateurs, groupe PB). Les variables principales d'évolution étaient la lichénification, la sécheresse, la souplesse et l'étendue des lésions. L'indice de satisfaction subjective du propriétaire était une variable secondaire. L'évaluation a été réalisée à jours (D) 0, 30 et 60. La réponse au traitement a été évaluée comme le changement de la ligne de base pour chaque jour d'examen à chaque critère.

Résultats – Quarante huit chiens, principalement des bouledogues français (26 sur 48) et anglais (sept sur 48) ont été inclus et 39 ont finalisé l'étude. Aucun effet secondaire majeur n'a été rapporté. À D60, les changements de ligne de base pour la lichénification, l'étendue des lésions, la souplesse et le score total étaient respectivement 31.2%, 18.3%, 72.8% et 36.8% dans le groupe DBB (23 chiens) et 11.9%, 2.3%, 42.1% et 14% dans le groupe PB (16 chiens). Le score total a été significativement amélioré à D60 comparé à PB (Wilcoxon–Mann–Whitney *U*-test, $P = 0.0016$).

Conclusions et importance clinique – Le baume a montré son efficacité et son utilité dans la gestion de l'hyperkératose nasale idiopathique canine non compliquée.

Resumen

Introducción – La hiperqueratosis nasal puede causar molestias en los perros al predisponerlos a fisuras e infecciones secundarias. Las pautas de tratamiento se han descrito sólo de forma anecdótica; la eficacia de tales terapias sigue sin haberse probado.

Hipótesis/Objetivos – Investigar la eficacia de una pomada que contiene aceites esenciales y ácidos grasos esenciales en perros con hiperqueratosis nasal idiopática.

Animales – Perros de propietarios privados con hiperqueratosis nasal no complicada.

Métodos – El estudio clínico se realizó como al azar, doble ciego, controlado con placebo con diseño de grupos en paralelo y 2 meses de seguimiento. Los perros recibieron aplicación tópica diaria de una pomada comercial (grupo DBB) o placebo (agente gelificante acuoso con conservantes, grupo PB). Los principales resultados fueron liquenificación, sequedad, flexibilidad y extensión de las lesiones. La puntuación

subjetiva del índice de satisfacción del propietario fue una variable secundaria. La evaluación se realizó en los días (D) 0, 30 y 60. La respuesta al tratamiento se evaluó como el cambio desde el estado inicial a cada día de examen para cada criterio.

Resultados – Se incluyeron 48 perros, principalmente franceses (26 de 48) e ingleses (siete de 48), y 39 completaron el estudio. No se detectaron efectos adversos de importancia. En el D60, los cambios a partir del estado inicial para la liqenificación, extensión de lesiones, la flexibilidad y la puntuación total fueron de $_31,2\%$, $_18,3\%$, $_72,8\%$ y $_36,8\%$ en el grupo DBB (23 perros) y $_11,9\%$, $2,3\%$, $_42,1\%$ y $_14\%$ en el grupo PB (16 perros), respectivamente. La valoración total mejoró significativamente en D60 en el grupo DBB en comparación con PB (Wilcoxon-Mann-Whitney U-test, $P = 0,0016$).

Conclusiones y importancia clínica – La pomada demostró ser segura y útil en el manejo de la hiperqueratosis nasal idiopática no complicada canina.

Zusammenfassung

Hintergrund – Eine nasale Hyperkeratose kann Hunden unangenehm sein, indem sie zu Fissuren und Sekundärinfektionen prädisponiert. Es gibt anekdotenhafte Berichte über Behandlungsstrategien; die Wirksamkeit derartiger Therapien bleibt unbestätigt.

Hypothese/Ziele – Eine Untersuchung der Wirksamkeit von Balsam, welcher essentielle Öle und essentielle Fettsäuren beinhaltet, zur Behandlung der nasalen Hyperkeratose.

Tiere – Hunde in Privatbesitz mit unkomplizierter nasaler Hyperkeratose.

Methoden – Die Studie wurde als randomisierte, doppelblinde, Placebo-kontrollierte klinische Studie mit einem parallelen Gruppensdesign und einer 2 monatigen Follow-Up Periode angelegt. Die Hunde erhielten täglich topische Anwendungen eines kommerziellen Balsamprodukts (Gruppe DBB) oder Placebo (wässriges Gel mit Konservierungsstoffen, Gruppe PB). Die hauptsächlichen Unterschiede bestanden in der Lichenifizierung, Trockenheit, Geschmeidigkeit und dem Ausmaß der Veränderungen. Eine weitere Variable war der Indexwert der Besitzerzufriedenheit. Eine Evaluierung wurde am Tag (D)0, 30 und 60 durchgeführt. Die Antwort auf die Behandlung wurde als Veränderung vom Ausgangswert zur Untersuchung am jeweiligen Untersuchungstag für jedes Kriterium ermittelt.

Ergebnisse – Achtundvierzig Hunde, hauptsächlich Französische (26 von 48) und Englische (sieben von 48) Bulldoggen wurden inkludiert und 39 beendeten die Studie. Es wurden keine Nebenwirkungen beschrieben. Am Tag D60 betrugen die Werte der Veränderungen vom Ausgangswert für die Lichenifizierung, das Ausmaß der Veränderungen, die Geschmeidigkeit und der Totalwert $_31,2\%$, $_18,3\%$, $_72,8\%$ und $_36,8\%$ in Gruppe DBB (23 Hunde) bzw. $_11,9\%$, $_2,3\%$, $_42,1\%$ und $_14\%$ in Gruppe PB (16 Hunde). Der Totalwert war am D60 in Gruppe DBB signifikant besser im Vergleich zu PB (Wilcoxon-Mann-Whitney U-Test, $P = 0,0016$).

Schlussfolgerungen und klinische Bedeutung – Der Balsam war beim Management der idiopathischen unkomplizierten nasalen Hyperkeratose des Hundes sicher und hilfreich.

要約

背景 – 鼻角化亢進症は、亀裂や二次感染症の素因となり、犬に不快感を引き起こす可能性がある。逸話的な治療の報告はあるが、その有効性は未だ証明されていない。

仮説/目的 – 特発性鼻角化亢進症の犬に対するエッセンシャルオイルと必須脂肪酸を含む香油の有効性を評価すること。

供与動物 – 複雑化していない鼻角化亢進症の飼い犬。

方法 – この研究は、並行群間比較試験デザインを用いた無作為化二重盲検プラセボ対照臨床試験であり、2ヵ月の追跡期間を設けた。犬は、市販の香油製品(DBB群)またはプラセボ(防腐剤及び保存剤を含む水性ゲル化剤、PB群)を毎日塗布された。主要結果変数は、苔癬化、乾燥、しなやかさ、および病変の広がりとした。オーナーの主観的満足度指数スコアを二次結果変数とした。評価は、0日目(D)、30日目および60日目に実施した。治療に対する反応は、各項目についてのベースラインと比較した各試験日における変化として評価した。

結果 – 48頭の犬が参加し{主にフレンチブルドッグ(48頭中26頭)とイングリッシュブルドッグ(48頭中7頭)}、39頭が治験を完遂した。重大な有害事象は報告されなかった。D60において、DBB群(23頭)の苔癬化、病変の広がり、しなやかさおよび総スコアのベースラインからの変化は、それぞれ31.2%、18.3%、72.8%および36.8%であった。PB群(16頭)におけるそれらは、11.9%、2.3%、42.1%および14%であった。総スコアはPB群と比較して、DBB群のD60で有意に改善した(Wilcoxon-Mann-Whitney U検定、 $P = 0.0016$)。

結論および臨床的重要性 – 香油は、複雑化していない犬の特発性鼻角化亢進症を治療する上で安全かつ有用であることが証明された。

摘要

背景 – 鼻面過度角化可导致裂口和继发感染,这会使犬感到不适。已经有关于治疗此病的个人经验分享报道;但其治疗效果尚未被证实。

假设/目的 – 调查含必需油脂和必需脂肪酸的软膏,对犬特发性鼻面过度角化的治疗效果。

动物 — 客户饲养犬,均为鼻面过度角化,且无其他并发症。

方法 — 本研究按照随机、双盲、安慰剂对照法进行临床试验,平行组设计,跟诊两个月。每天给犬局部涂抹商品化软膏(DBB组)或安慰剂(含防腐剂的水凝胶制剂,PB组)。主要结果变量包括病变的苔藓化程度、干燥度、柔软度和严重程度。主人主观满意指数评分为次要变量。在第0、30和60天进行评估。治疗效果评估基于每条标准的每日检查结果。

结果 — 研究中有四十八只犬,主要为法国(26/48只)和英国(7/48只)斗牛犬,39只完成了整个测试。没有发现明显的副作用。在第60天,基于苔藓化程度、病变程度、柔软度的变化值和总分被评出,DBB组(23只犬)分别为_31.2%, _18.3%, _72.8%和 _36.8%,PB组分别为_11.9%, 2.3%, _42.1%和 _14%。在第60天,DBB组的总分明显高于PB组(Wilcoxon–Mann–Whitney U-试验, $P = 0.0016$)。

结论和临床意义 — 在管理无并发症的犬特发性鼻面过度角化方面,证明软膏安全且有效。

Resumo

Contexto — A hiperqueratose nasal pode causar desconforto em cães devido à predisposição ao desenvolvimento de fissuras e infecções secundárias. Alguns protocolos de tratamento têm sido relatados; a eficácia destas terapias ainda permanece não comprovada.

Hipótese/Objetivos — Investigar a eficácia de um bálsamo contendo óleos essenciais e ácidos graxos essenciais em cães com hiperqueratose nasal.

Animais — Cães de proprietários com hiperqueratose nasal não complicada.

Métodos — O estudo foi conduzido em um ensaio clínico, duplo-cego, randomizado, placebo-controle delineado em grupos paralelos e dois meses de período de acompanhamento. Os cães receberam aplicação tópica diária de um bálsamo comercial (grupo DBB) ou placebo (gel aquoso com preservativos/conservantes, grupo PB). As principais variáveis de acompanhamento foram lignificação, ressecamento, flexibilidade e extensão das lesões. O índice subjetivo de satisfação dos proprietários foi uma variável secundária. Os animais foram avaliados nos dias (D)0, 30 e 60. A resposta ao tratamento foi avaliada a partir das alterações observadas em relação ao quadro inicial a cada dia de exame, para cada critério do estudo.

Resultados — Quarenta e oito cães, principalmente buldogues franceses (26 de 48) e ingleses (sete de 48), foram incluídos e 39 completaram o estudo. Não foram observadas reações adversas importantes. No D60, alterações em relação ao quadro inicial quanto à lignificação, extensão de lesão, flexibilidade e escore total foram _18.3%, _72.8% e _36.8% no grupo DBB (23 cães) e _11.9%, 2.3%, _42.1% e 14% no grupo PB (16 cães), respectivamente. O escore total foi melhorou significativamente no D60 no grupo DBB, comparado ao grupo PB (Wilcoxon–Mann–Whitney U-test, $P = 0.0016$).

Conclusões e importância clínica — O bálsamo demonstrou ser seguro e eficaz no manejo da hiperqueratose nasal idiopática canina não complicada.