



**HAL**  
open science

## Reduced toxicity of 3-epi-deoxynivalenol and de-epoxy-deoxynivalenol through deoxynivalenol bacterial biotransformation

Ana Paula F.L. Bracarense, Alix Pierron, Philippe Pinton, Juliana R Gerez, Gerd Schatzmayr, Wulf-Dieter Moll, Ting Zhou, Isabelle P. Oswald

► **To cite this version:**

Ana Paula F.L. Bracarense, Alix Pierron, Philippe Pinton, Juliana R Gerez, Gerd Schatzmayr, et al.. Reduced toxicity of 3-epi-deoxynivalenol and de-epoxy-deoxynivalenol through deoxynivalenol bacterial biotransformation. *Food and Chemical Toxicology*, 2020, 140, pp.111241. 10.1016/j.fct.2020.111241 . hal-03331256

**HAL Id: hal-03331256**

**<https://ut3-toulouseinp.hal.science/hal-03331256v1>**

Submitted on 1 Sep 2021

**HAL** is a multi-disciplinary open access archive for the deposit and dissemination of scientific research documents, whether they are published or not. The documents may come from teaching and research institutions in France or abroad, or from public or private research centers.

L'archive ouverte pluridisciplinaire **HAL**, est destinée au dépôt et à la diffusion de documents scientifiques de niveau recherche, publiés ou non, émanant des établissements d'enseignement et de recherche français ou étrangers, des laboratoires publics ou privés.

1        **Reduced toxicity of 3-epi-deoxynivalenol and de-epoxy-deoxynivalenol through**  
2        **deoxynivalenol bacterial biotransformation: *in vivo* analysis in piglets**

3

4        Ana Paula F. L. Bracarense<sup>1</sup>, Alix Pierron<sup>2</sup>, Philippe Pinton<sup>2</sup>, Juliana R. Gerez<sup>1</sup>,  
5        Gerd Schatzmayr<sup>3</sup>, Wulf-Dieter Moll<sup>3</sup>, Ting Zhou<sup>4</sup>, Isabelle P. Oswald<sup>2</sup>

6

7        <sup>1</sup> Laboratory of Animal Pathology, Universidade Estadual de Londrina, Rodovia Celso  
8        Garcia Cid, km 380, 86057-970, Londrina, PR, Brazil.

9        <sup>2</sup> Toxalim (Research Center in Food Toxicology), Université de Toulouse, INRAE,  
10        ENVT, INP-Purpan, UPS, Toulouse, France

11        <sup>3</sup> BIOMIN Research Center, Tulln, Austria

12        <sup>4</sup> Guelph Food Research Center Agriculture & Agri-Food Canada, Guelph, Ontario N1G  
13        5C, Canada

14        Corresponding author: Ana Paula F. L. Bracarense, anapaula@uel.br

15

16        **Abstract**

17        Ingestion of deoxynivalenol (DON), one of the most common mycotoxin contaminants  
18        of cereals, leads to adverse effects for animal and human health. Bacterial  
19        biotransformation is a strategy to mitigate the toxicity of this mycotoxin. The present  
20        study aims to evaluate the toxicity of two bacterial biotransformation products of DON:  
21        3-epi-deoxynivalenol (3-epi-DON) and de-epoxy-deoxynivalenol (DOM-1) through  
22        zootechnical, hematological, histological and immunological assays. Twenty-four 4-  
23        weeks-old piglets received a control diet or a diet contaminated with 3 mg kg<sup>-1</sup> DON,  
24        DOM-1, or 3-epi-DON for 7 days. Sample tissues were collected for  
25        histomorphometrical analysis, expression of cytokines and cell protein junctions. The  
26        zootechnical and hematological parameters were not modulated by any treatment.  
27        Ingestion of DON induced histological alterations in the intestine, liver and lymphoid  
28        organs, as well as an overexpression of pro-inflammatory cytokines, E-cadherin and  
29        occludin. These changes were not observed in piglets receiving the DOM-1 and 3-epi-  
30        DON contaminated diets. Pigs fed 3-epi-DON contaminated diet showed an increase in  
31        IgM levels in comparison with other diets, while no change was observed in IgA and  
32        IgG levels among the diets. Our results indicate that DOM-1 and 3-epi-DON are not  
33        toxic for piglets; thus bacterial biotransformation seems to be a sustainable alternative  
34        to reduce mycotoxin toxicity.

35

36

37        **Keywords:** detoxification, histopathology, immunomodulation, mycotoxins,  
38        trichothecenes.

1

## 2 INTRODUCTION

3 Mycotoxins are fungal secondary metabolites that naturally contaminate food  
4 and feed, representing a health risk factor for both human and animals. These toxins  
5 also induce negative economic impacts in the livestock production (CAST 2003;  
6 Karlovsky et al., 2016). Deoxynivalenol (DON) is a trichothecene produced by  
7 *Fusarium* species frequently found worldwide contaminating cereals crops as wheat,  
8 barley and maize (Knutsen et al., 2017). Food and feed are naturally contaminated with  
9 DON and its derivate modified forms (Payros et al., 2016). The derivate forms of DON  
10 can be the result of fungi acetylation [3-acetyl-deoxynivalenol (3ADON), 15 acetyl-  
11 deoxynivalenol (15ADON)], plant production [deoxynivalenol-3- $\beta$ -D-glucopyranoside  
12 (DON3G)] or bacterial transformation [de-epoxy-deoxynivalenol (DOM-1), 3-epi-  
13 deoxynivalenol (3-epi-DON) and 3-keto-deoxynivalenol (3-keto-DON)] (Alizadeh et  
14 al., 2016; Payros et al., 2016; Pierron et al., 2016).

15 The toxic effect of DON has been widely investigated and is associated with its  
16 ability to bind to the ribosome, inhibits protein and nuclei acid synthesis, induces  
17 ribotoxic stress and activation of *mitogen activated kinases* (MAPKs) (Pestka, 2010;  
18 Pinton et al., 2010). In pigs, DON induces changes in the intestinal barrier function, the  
19 absorption of nutrients and the immune response (Bracarense et al., 2012; Silva et al.,  
20 2014; Pinton et al., 2015). In addition, histological changes in the liver and the kidney  
21 (Mikami et al., 2004; Grenier et al., 2011), apoptosis of lymphocytes (Mikami et al.,  
22 2010) and immunotoxic effects on the expression of immunoglobulin and  
23 proinflammatory cytokines were also described (Pinton et al., 2008; Grenier et al.,  
24 2011; Bracarense et al., 2012).

1 Data concerning DON derived forms after bacterial transformations are scarce  
2 and the effects of these modified mycotoxins are not well established, especially *in vivo*.  
3 Indeed most of the experiments were performed using *in vitro* and *ex vivo* approaches  
4 (Danicke et al., 2010; Broekaert et al., 2016; Pierron et al., 2016; Springler et al., 2017).  
5 They demonstrated in different cell lines that DOM-1 and 3-epi-DON induces no  
6 alteration in cell viability, proliferation and membrane integrity, while in intestinal  
7 explants no morphological changes or activation of MAPKs were detected. *In vivo*  
8 experiments investigating the toxicity of DOM-1 and 3 epi-DOM are limited and none  
9 of them were performed using contaminated diet. In mice, purified 3-epi-DON  
10 administrated by gavage did not alter body and organ weights, hematology and organ  
11 histopathology (He et al., 2015). Similarly, gavage experiment performed in pigs  
12 demonstrated the reduced toxicity of purified DOM-1 in pigs (Pierron et al., 2018).

13 A better understanding of the local and systemic effects of 3-epi-DON and  
14 DOM-1 using an *in vivo* model with contaminated diet is important to the development  
15 of decontamination strategies including bacterial/enzymatic transformation of DON in  
16 metabolites with reduced toxicity. The purpose of the present study was to evaluate  
17 zootechnical and hematological parameters, as well as histological and immunological  
18 aspects in pigs fed DON-, DOM-1 and 3-epi-DON-contaminated diets.

19

## 20 MATERIAL AND METHODS

### 21 *Animals*

22 All animal studies were carried out in accordance with the European Guidelines  
23 for the Care and Use of Animals for Research Purposes (Directive 2010/63/EU) and  
24 validated by Ethics Committee for Animal Experiments Toxcomethique n° 86  
25 (TOXCOM/0018/PPIO). Twenty-four 4-weeks-old weaned castrated male piglets

1 (Pietrain/Duroc/Large-white) were used in the present study. The effect of sex has been  
2 largely overlooked in mycotoxicological research (for review see Soler and Oswald,  
3 2018). Nevertheless, some studies have shown the higher sensitivity of male pigs to  
4 mycotoxin including DON (Andretta et al., 2012; Marin et al., 2006). Thus, for this  
5 reason and in order to avoid the influence of hormonal cycle, the experiment was  
6 performed on castrated male piglets. Pigs were acclimatized for 1 week in the animal  
7 facility of the INRA ToxAlim Laboratory (Toulouse, France) prior to being used in  
8 experimental protocols. Six pigs were allocated to each treatment on the basis of body  
9 weight and were observed daily. During the experimental period each treatment group  
10 was given free access to water and the assigned diet. Piglets were weighed at day 0, 3  
11 and 6 and body weight gain was calculated for the total period. After euthanasia, the  
12 weight of intestine, liver and spleen was measured.

13

#### 14 *Mycotoxins and experimental diets*

15 Purified DON was purchased from Sigma-Aldrich (St Louis, MO, USA). Crystalline  
16 DON (Romer Labs, Tulln, Austria) was transformed to obtain DOM-1, as previously  
17 described (Pierron et al., 2016). 3-epi-DON was obtained by microbial transformation  
18 of DON as already described (He et al., 2015).

19 Four different batches were prepared, one control batch and three batches artificially  
20 contaminated with the mycotoxins. Each purified mycotoxin was dissolved in water at  
21 the concentration of 1 mg/mL and directly sprayed on a monolayer thin of a second age  
22 piglet finished feed (Stimiouti, EVIALIS France), done in a similar way as previously  
23 described for an enzyme (Grenier et al., 2013). Animals were exposed to the  
24 contaminated feed containing 3 mg kg<sup>-1</sup> of DON, DOM-1 or 3-epi-DON. The dose of  
25 3mg kg<sup>-1</sup> was chosen as it can be observed in contaminated crops (SCOOP 2003,

1 Knutsen et al., 2017) and it induces significant intestinal and systemic alterations in  
2 piglets (Bracarense et al., 2012; Grenier et al., 2013; Alassane–Kpembé et al., 2020).  
3 After six days of exposure to the mycotoxins, pigs were submitted to electrical stunning  
4 and euthanized by exsanguination.

5

#### 6 *Hematological and immunological parameters*

7 At day 0, 3 and 6 blood samples were aseptically collected from the left jugular  
8 vein. Hematological analysis was carried out at day 6, using the impedance coulter  
9 LH500 (Beckman Coulter, Villepinte, France). Subpopulations of white blood cells  
10 (lymphocytes, monocytes, neutrophils, eosinophils and basophils) were also analyzed  
11 and made manually on 100 leukocytes on May-Grunwald Giemsa stained smears.

12 The total concentration of the immunoglobulin subsets was measured by ELISA  
13 as previously described (Marin et al., 2006). Briefly, the different isotypes were  
14 detected with the appropriate peroxidase anti-pig IgA, IgM or IgG (Bethyl, Interchim,  
15 Montluçon, France) and were quantified by reference to standard curves constructed  
16 with known amounts of pig immunoglobulin classes. Absorbance was read at 450nm  
17 using an ELISA plate reader (Spectra thermo, Tecan, NC, USA) and the Biolise 2.0 data  
18 management software.

19

#### 20 *Histological assessment*

21 After euthanasia, samples of jejunum, jejunum with Peyer's patches (PP), ileum,  
22 ileum Peyer's patches, colon, liver, spleen and lymph nodes were collected from all  
23 treatments and fixed in 10% buffered formalin for histopathological evaluation. Tissue  
24 samples were routinely processed and embedded in paraffin wax. Sections of 5 µm were  
25 stained with hematoxylin-eosin (HE) and periodic acid-Schiff (PAS) for

1 histopathological and goblet cells evaluation respectively. A lesion score was performed  
2 as already described (Terciolo et al., 2019). Villi height was measured randomly on 10  
3 villi using an image analysis system (Motic Image Plus, Motic Instruments, Richmond,  
4 Canada) at 20x magnification. The evaluation of goblet cells was performed by  
5 counting PAS stained cells in the villi and crypt region in five fields randomly at 40x  
6 magnification.

7

#### 8 *Determination of the expression of mRNA encoding for cytokines by real-time PCR*

9 Tissue RNA from jejunum, jejunum with Peyer's patches, liver and spleen was  
10 extracted following the procedures previously described (Grenier et al., 2011).  
11 Concentrations, integrity and quality of RNA were determined using Nanodrop ND1000  
12 (Labtech International, Paris, France) and Bioanalyser (Agilent RNA 6000 Nano Kit  
13 Quick Start Guide). The reverse transcription and real-time qPCR steps were performed  
14 as already described by Maruo et al. (2018). Specificity of PCR products was checked  
15 out at the end of the reaction by analyzing the curve of dissociation. The sequences of  
16 the primers (Invitrogen, Life Technologies Corporation, Paisley, UK) used are detailed  
17 in Table 1. After verification of the similarity of efficacy between genes, the more stable  
18 housekeeping genes was used as a reference for normalization. The fluorescence was  
19 expressed by  $\Delta C_t$  method then the values were represented via the  $2^{-\Delta\Delta C_t}$  analysis  
20 method (Livak and schmittgen 2001). The mRNA expression levels were expressed  
21 relative to the mean of the control group as already described by Caceres et al. (2018).

22

#### 23 *Statistical analysis*

24 Data were presented as the means with their standard errors and were analyzed  
25 using the free software Action 2.3 (Campinas, SP, Brazil). One-way analysis of

1 variance (ANOVA) followed by a multiple comparison procedure (Tukey or Duncan  
2 test) was used for statistical analysis. P values  $\leq 0.05$  were considered significant.

3

## 4 **RESULTS**

5 *Effects on weight gain, organs weight, hematological parameters and immunoglobulin*  
6 *levels*

7 Pigs fed the DON diet showed no significant difference, but a trend of decrease  
8 in weight gain at day 6 compared to other treatments was observed. The mean weight  
9 gain was 1.85, 1.41, 1.71 and 1.68 kg at day 6 for the control, DON, DOM-1 and 3-epi-  
10 DON groups, respectively. There was no difference among the treatments concerning  
11 the organs' weight (data not shown).

12 The hematological parameters remained similar in the different groups (Table 2).  
13 The ingestion of DON, DOM-1 and 3-epi-DON diets induced no changes in IgA and  
14 IgG levels when compared to control diet. On the other hand, pigs fed 3-epi-DON diet  
15 showed an increase in IgM levels in the 3<sup>rd</sup> and 6<sup>th</sup> days in comparison to the other diets  
16 ( $P \leq 0.05$ ) (Figure 1).

17

18 *Histological assessment*

19 Piglets fed DON-contaminated diet showed significant histological changes in  
20 all evaluated tissues (intestines, liver and lymphoid organs) when compared to piglets  
21 fed DOM-1 or 3-epi-DON contaminated diets. In the intestine five segments were  
22 evaluated (jejunum, jejunum with Peyer's patches, ileum, ileum with Peyer's patches  
23 and colon). A significant increase in the lesion score was observed in all regions of the  
24 small intestine ( $P \leq 0.05$ ) of animals receiving DON-contaminated diet when compared  
25 to other diets (Figure 2A). Flattening of enterocytes, villi fusion, apical necrosis, edema



1 of lamina propria were the most frequent histological changes observed in the jejunum  
2 and jejunum with Peyer's patches (Figure 2C). In ileum and ileum with Peyer's patches  
3 the main changes were flattening of enterocytes, cytoplasmic vacuolation, edema of  
4 lamina propria and dilatation of lymphatic vessels. In colon no significant alteration in  
5 the morphological score ( $P>0.05$ ) was observed among the treatments (data not shown).  
6 On the other hand, the intestine of piglets receiving DOM-1 and 3- epi-DON  
7 contaminated diets remained similar to the intestine of animals from the control group  
8 (Figure 2B, 2D, 2E).

9 Ingestion of contaminated diets induced no significant changes in villi height  
10 (data not shown) compared to control. The number of goblet cells increased  
11 significantly in the villi of all regions of the small intestine in pigs receiving the DON-  
12 contaminated diet ( $P\leq 0.05$ ) compared to the control (Figure 3). Conversely, DOM-1  
13 remained similar to the control, excepting in the jejunum with Peyer's patches where an  
14 increased number of goblet cells was observed. Ingestion of 3-epi-DON induced no  
15 change in villi goblet cells number (Figure 3). In the crypt region of jejunum with  
16 Peyer's patches and ileum a significant reduction of goblet cell was observed in animals  
17 fed the DON-diet in comparison with the control diet. No significant changes were  
18 observed among the other treatments ( $P>0.05$ ) (Figure 3). In the colon, the number of  
19 goblet cells remained similar in all treatments ( $P>0.05$ ) (data not shown).

20 Mild to moderate disorganization of hepatic cords, megalocytosis, cell  
21 vacuolation (cytoplasmic and nuclear) and mild necrosis were the main findings  
22 observed in the liver of piglets submitted to DON contaminated diet. These histological  
23 changes resulted in a significant increase in the lesion score in pigs fed DON diet  
24 compared to other groups ( $P\leq 0.05$ ). The liver of piglets receiving DOM-1 and 3-epi-  
25 DON contaminated diets remained histologically similar to the control group (Figure 4).

1 Lymphoid organs showed a significant increase in the lesion score in piglets  
2 receiving the DON-contaminated diet ( $P \leq 0.05$ ) when compared to other diets (Figure  
3 5A). Both spleen and mesenteric lymph nodes showed mild to moderate lymphocyte  
4 apoptosis, an increase in germinative centers of lymphoid follicles and  
5 lymphoplasmocytic hyperplasia into paracortical and medullary sinuses (lymph node)  
6 and red pulp (spleen) (Figure 5C). Pigs fed the DOM-1 and 3-epi-DON contaminated  
7 diets showed no significant histological changes (Figure 5 B, 5D, 5E) compared to the  
8 control ( $P > 0.05$ ).

#### 9 10 *Expression of cytokines*

11 The mRNA expression of 12 cytokines and chemokines was evaluated by real-  
12 time PCR in samples of jejunum, liver and spleen. In both regions of jejunum, DON  
13 induced a significant increase in the levels of IL-12p40 (2.2-fold,  $P < 0.05$ ), TNF- $\alpha$  (2.2-  
14 fold,  $P < 0.05$ ), and CCL20 (5-fold,  $P < 0.05$ ) compared to control. In addition, an increase  
15 in the expression of IL-8 (1.8-fold,  $P < 0.05$ ) and IL-17A (4.5-fold,  $P < 0.05$ ), and in IL-10  
16 was also observed in jejunum and in jejunum with Peyer's patches, respectively (Table  
17 3). On the other hand, an increased expression of IL-1 $\alpha$  and CX3CL-1 (DOM-1 group)  
18 and IL-10 (3-epi-DON group) was observed in one of the jejunum regions. The  
19 expression of two protein cell junctions was also investigated in the jejunum. The  
20 ingestion of DON induced a significant increase in E-cadherin (~ 2 fold) in both regions  
21 of the jejunum, while occludin expression increased ~ 2.4 fold in the jejunum with  
22 Peyer's patches in comparison to control. No change was observed in the other groups  
23 (Table 3). In the liver and spleen no significant change in the cytokines expression was  
24 observed whatever the treatments (data not shown).

25

## 1 **DISCUSSION**

2           Ingestion of DON-contaminated diets affects animal growth, nutrient absorption,  
3 intestinal barrier function, induces intestinal lesions, and modulates the intestinal  
4 immune response (Pinton and Oswald, 2014). Pigs were one of the most affected  
5 species of DON toxicity, therefore detoxification strategies are of increasing interest.  
6 The toxicity of DON metabolites obtained after bacterial biotransformation is poorly  
7 documented and no studies have been performed with pigs fed purified 3-epi-DON and  
8 DOM-1. In the present study, piglets were submitted to one-week intoxication with a  
9 realistic concentration of DON and their metabolites DOM-1 and 3-epi-DON. Our  
10 results indicate a reduced toxic effect of these metabolites on histological and  
11 immunological parameters in piglets when compared to DON.

12           Changes in weight gain and hematological parameters were not observed in the  
13 present study, similarly to a previous study using piglets fed a 2.8 mg kg<sup>-1</sup> DON diet for  
14 four weeks (Grenier et al., 2013). Considering the low dose used and the short period of  
15 exposure, these results are not surprising. In the same way, the modified forms of DON  
16 induced no significant alteration in these parameters, as already observed in other  
17 studies. Indeed, pigs receiving a diet containing DOM-1 (5 mg kg<sup>-1</sup>, 1 nmol kg<sup>-1</sup> body  
18 weight/day) for nine to 21 days showed no difference in daily feed consumption, daily  
19 weight gain and feed efficiency (Li et al., 2011; Pierron et al., 2018). Similarly, mice  
20 fed a 3-epi-DON diet (2 mg kg<sup>-1</sup>) for 28 days showed no toxic effects compared to DON  
21 in these parameters (Qu et al., 2019).

22           Histological and immunological changes have been previously reported  
23 affecting intestine, lymphoid organs and liver of pigs exposed to DON (Bracarense et  
24 al., 2012; Gerez et al., 2015). The toxic effects were mainly associated to ribotoxic  
25 stress and activation of MAPKs (Pestka, 2010; Pinton et al., 2010). In this study,

1 similarly to literature data, DON induced a significant increase (mean two fold-increase)  
2 in intestinal changes (enterocyte flattening, villi fusion and edema of lamina propria)  
3 compared to control treatment (Pinton et al., 2012; Bracarense et al., 2012; Silva et al.,  
4 2014). Analogous alterations were also described in pigs chronically exposed to a DON-  
5 contaminated diet (3 mg kg<sup>-1</sup> feed) (Bracarense et al., 2012). The jejunum is the main  
6 intestinal region affected by the toxic effects of DON and this was evident in our  
7 histopathological findings. Differing from previous studies (Bracarense et al., 2012,  
8 Basso et al., 2013), the expression of E-cadherin and occludin was increased in the  
9 jejunum in DON-exposed group. Our hypothesis to explain this difference in the  
10 expression of cell junction proteins is related to the shorter period of exposure (7 versus  
11 35 days). Apparently, the initial period of exposure induces an overexpression of these  
12 proteins; however the persistence of the exposure results in a breakdown of the  
13 expression. In addition, a complete renewal of pig intestinal epithelium occurs every  
14 two to three days (Verdile et al., 2019); this characteristic may also interfere with the  
15 protein expression. The mechanism of this acute overexpression remains to be  
16 investigated.

17 Interestingly, DOM-1 and 3-epi-DON treatments induced no significant changes  
18 in the morphology or cell junction protein expression in the intestine. The histological  
19 changes observed in these groups were mild edema of lamina propria and dilatation of  
20 lymphatic vessels. In a previous study, pigs fed a DOM-1 diet for a longer period (14 or  
21 21 days) also remained alike the control group (Pierron et al., 2018). Mild  
22 morphological changes were also observed in a recent *ex vivo* study with 3-epi-DON  
23 using intestinal explants from pigs (Pierron et al., 2016). Furthermore, mice receiving  
24 diets containing 25 and 100 mg kg<sup>-1</sup>/body weight or 2 mg kg<sup>-1</sup> of 3-epi-DON showed no  
25 gross or histological alterations (He et al., 2015, Qu et al., 2019).

1           No alteration in the villi height was observed in this experiment, probably due to  
2 the short duration of DON exposure since a longer exposure (35 days) with the same  
3 concentration (3 mg Kg<sup>-1</sup> feed) (Bracarense et al., 2012) decreased significantly the  
4 intestinal villi height in pigs. The number of goblet cells increased in the villi and  
5 decreased in the crypt region of piglets treated with DON compared to the DOM-1, epi-  
6 DON and the control. We believe that the acute exposure to DON induced a migration  
7 of goblet cells from crypt region to villi. This finding differs from chronic exposure to  
8 DON where a decrease in the number of goblet cells was reported (Bracarense et al.,  
9 2012; Basso et al., 2013; Gerez et al., 2015), probably due to an increase of apoptosis  
10 in the crypt region (Silva et al., 2014).

11           Modulation of the inflammatory response was described in animals receiving  
12 diets contaminated with DON. In the intestine an increased expression of inflammatory  
13 cytokines such as of IL-1 $\alpha$ , TNF $\alpha$ , IL-1 $\beta$ , IL-8, IL-12p40, IL-17A and IL-22 was  
14 reported in *ex vivo* (Cano et al., 2013; Garcia et al., 2019; Pierron et al., 2016) and *in*  
15 *vivo* trials (Grenier et al., 2011; Bracarense et al., 2012). In the present study, an  
16 inflammatory pattern was also observed in animals receiving DON in both regions of  
17 the jejunum. From the 12 cytokines analyzed, six were increased in this group; CCL20  
18 and IL-17A showed the greater levels of expression (5-fold and 4.5-fold, respectively).  
19 CCL20 is strongly chemotactic for lymphocytes (Hieshima et al., 1997) and IL17-A  
20 regulates the activities of MAPKs (Kolls and Khader, 2010), both activities strongly  
21 associated with DON ingestion. Our results indicate that DON induces a pro-  
22 inflammatory modulation even in shorter periods of exposure. Conversely, DOM-1 (~2-  
23 fold of IL-1 $\alpha$  and CX3CL1) and 3-epi-DON (1.42-fold of IL-10) induced mild increase  
24 in cytokines' expression, reinforcing the minimal toxicity of these derived forms.

1 Immunotoxic and hepatotoxic effects of DON were reported in pigs (Mikami et  
2 al., 2010). The toxic effects were related to impairment of protein synthesis (Van de  
3 Walle et al., 2010) leading to disturbances in mitochondria and cell apoptosis (Springler  
4 et al., 2017). Similarly to previous studies (Grenier et al., 2011; Gerez et al., 2015), in  
5 the present experiment, DON induced a significant increase in the lesion score in liver,  
6 spleen and mesenteric lymph nodes. Nevertheless, piglets submitted to DOM-1 and 3-  
7 epi-DON diets showed no significant histological changes in these organs. The  
8 production of immunoglobulins was also evaluated in the present study. Differently  
9 from previous studies, DON induced no change in immunoglobulin levels, probably as  
10 a result of a short period of exposure (Li et al., 2018; Lessard et al., 2015). The levels of  
11 all immunoglobulins remained similar to the control in piglets fed DOM-1 diet, while  
12 an increase in the IgM level was observed in 3-epi-DON group. Taken together, our  
13 results demonstrated that these derived forms showed no toxicity to the liver or  
14 lymphoid organs.

15 Toxicological aspects about 3-epi-DON are scarce and the available data have  
16 been reported *in vitro* (He et al. 2015) or in rodent models (He et al., 2015; Qu et al.,  
17 2019). Our results reinforce the reduced toxicity of this metabolite in pigs. Concerning  
18 DOM-1, a previous *in vivo* study in pigs also stated a reduced toxicity (Pierron et al.,  
19 2018). The differences in the chemical structure of DON and their metabolites are  
20 related to the differences in biological activities (He et al., 2015). DON induces a  
21 ribotoxic stress binding to peptidyl transferase at the 60S ribosomal subunit level  
22 resulting in MAPKs activation, whereas DOM-1 and 3-epi-DON induces no activation  
23 of these signaling pathways (Pierron et al., 2016).

24 In conclusion, in this study we have confirmed the absence of toxicity of DOM-  
25 1 and 3-epi-DON using pigs in an *in vivo* model. Previously we have demonstrated the

1 reduced toxicity of DON metabolites in pigs' intestinal explants. In the present study we  
2 have demonstrated that this favorable effect is systemic, since no toxic effect was  
3 observed on intestine, liver and lymphoid organs.

#### 4 **Acknowledgments**

5 This work was financially supported by the CAPES/ COFECUB (0389/19) international  
6 cooperation program, and CNPq grant (308136/2018-7)

#### 8 **Conflict of interest**

9 The authors state no conflict of interest.

10 Van der Geer, J., Hanraads, J.A.J., Lupton, R.A., 2010. The art of writing a scientific  
11 article. *J. Sci. Commun.* 163, 51–59. <https://doi.org/10.1016/j.Sc.2010.00372>.

12  
13 Reference to a journal publication with an article number:  
14 Van der Geer, J., Hanraads, J.A.J., Lupton, R.A., 2018. The art of writing a scientific  
15 article. *Heliyon.* 19, e00205. <https://doi.org/10.1016/j.heliyon.2018.e00205>.

#### 17 **REFERENCES**

18 Alassane-Kpembé, I., Canlet, C., Tremblay-Franco, M., Jourdan, F., Chalzaviel, M.,  
19 Pinton, P., Cossalter, A.M., Achard, C., Castex, M., Combes, S., Bracarense, A.P.L.,  
20 Oswald, I.P., 2020. H-NMR metabolomics response to a diet contaminated with the  
21 mycotoxin deoxynivalenol: Effect of a supplementation with probiotics. *Food Chem.*  
22 *Toxicol.* In press.

23  
24 Andretta, I., Kipper, M., Lehnen, C.R., Hauschild, L., Vale, M.M., Lovatto, P.A., 2012.  
25 Meta-analytical study of productive and nutritional interactions of mycotoxins in  
26 growing pigs. *Animal* 6, 1476-1482. <https://doi.org/10.1017/S1751731111002278>.

27  
28 Basso, K., Gomes, F., Bracarense, A.P.L., 2013. Deoxynivalenol and fumonisin, alone  
29 or in combination, induce change on intestinal junction complexes and in E-cadherin  
30 expression. *Toxins* 28, 2341-2352. <https://doi.org/10.3390/toxins5122341>.

31  
32 Bracarense, A.P.F.R.L., Luciola, J., Grenier, B., Pacheco, G.D., Molls, W.D.,  
33 Schtzmayer, G., Oswald, I.P., 2012. Chronic ingestion of deoxynivalenol and fumonisin,  
34 alone or in interaction, induces morphological and immunological changes in the  
35 intestine of piglets. *Br. J. Nutr.* 107, 1776–1786.  
36 <https://doi.org/10.1017/S0007114511004946>.

37

1 Broekaert, N., Devreese, M., Demeyere, K., Berthiller, F., Michlamyr, H., Varga, E.,  
2 Adam, G., Meyer, E., Croubles, S., 2016. Comparative in vitro cytotoxicity of modified  
3 deoxynivalenol on porcine intestinal epithelial cells. *Food Chem. Toxicol.* 95, 103-109.  
4 <https://doi.org/10.1016/j.fct.2016.06.012>.  
5  
6 Cano, P., Seeboth, J., Meurens, F., Cognie, J., Abrami, R., Oswald, I.P., Guzy-Lack-  
7 Piriou, L., 2013. Deoxynivalenol as a new factor in the persistence of intestinal  
8 inflammatory diseases: an emerging hypothesis through possible modulation of Th17-  
9 mediated response. *PLoS One* 8, e53647. <https://doi.org/10.1371/journal.pone.0053647>.  
10  
11 Caceres, I., El Khoury, R., Medina, A., Lippi, Y., Naylies, C., Atoui, A., El Khoury, A.,  
12 Oswald, I.P., Bailly, J.D., Puel, O., 2016. Deciphering the anti-aflatoxinogenic  
13 properties of eugenol using a large-scale q-PCR approach. *Toxins* 8, E123.  
14 <https://doi.org/10.3390/toxins8050123>.  
15  
16 CAST, 2003. Potential economic costs of mycotoxins in United States. In: *Mycotoxins:  
17 Risks in Plant, Animal and Human Systems*. Council for Agricultural Science and  
18 Technology, 136–142.  
19  
20 Danicke, S., Hegewald, A.K., Kahlert, S., Kluess, J., Rothkotter, H.J., Breves, G., Doll,  
21 S., 2010. Studies on the toxicity of deoxynivalenol (DON), sodiummetabisulfite DON-  
22 sulfonate (DONS) and de-epoxy-DON for porcine peripheral blood mononuclear cells  
23 and the intestinal porcine epithelial cell lines IPEC-1 and IPEC-J2 and on effects of  
24 DON and DONS on piglets. *Food Chem. Toxicol.* 48, 2145-2162. [https://doi.org/](https://doi.org/10.1016/j.fct.2010.05.022)  
25 [10.1016/j.fct.2010.05.022](https://doi.org/10.1016/j.fct.2010.05.022).  
26  
27 Garcia, G.R., Dogi, C.A., Poloni, V.L., Fochesato, A.S., De Moreno de Leblanc, A.,  
28 Cossalter, A.M., Payros, D., Oswald, I.P., Cavaglieri, L.R., 2019. Beneficial effects of  
29 *Saccharomyces cerevisiae* RC016 in weaned piglets: in vivo and ex vivo analysis.  
30 *Benef. Microbes* 10, 33-42. <https://doi.org/10.3920/BM2018.0023>.  
31  
32 Gerez, J.R., Pinton, P., Callu, P., Grosjean, F., Oswald, I.P., Bracarense, A.P.F.R.L.,  
33 2015. Deoxynivalenol alone or in combination with nivalenol and zearalenone induce  
34 systemic histological changes in pigs. *Exp. Toxicol. Pathol.* 67, 89-98. [https://doi.org/](https://doi.org/10.1016/j.etp.2014.10.001)  
35 [10.1016/j.etp.2014.10.001](https://doi.org/10.1016/j.etp.2014.10.001).  
36  
37 Grenier, B., Bracarense, A.P.L., Lucioli, J., Pacheco, G.D., Cossalter, A.M., Moll,  
38 W.D., Schatzmayr, G., Oswald, I.P., 2011. Ingestion and combined effects of  
39 subclinical doses of deoxynivalenol and fumonisin in piglets. *Mol. Nutr. Food Res.* 55,  
40 761-771. <https://doi.org/10.1002/mnfr.201000402>.  
41  
42 Grenier, B., Bracarense, A.P., Schwartz, H.E., Lucioli, J., Cossalter, A.M., Moll,  
43 W.D., Schatzmayr, G., Oswald, I.P., 2013. Biotransformation approaches to alleviate  
44 the effects induced by fusarium mycotoxins in swine. *J. Agric. Food Chem.* 61, 6711-  
45 6719. <https://doi.org/10.1021/jf400213q>.  
46  
47 He, J.W., Bondy, G.S., Zhou, T., Caldwell, D., Boland, G.J., Scott, P.M., 2015.  
48 Toxicology of 3-epi-deoxynivalenol, a deoxynivalenol-transformation product by  
49 *Devosia mutans* 17-e-E-8. *Food Chem. Toxicol.* 84, 250-259. [https://doi.org/](https://doi.org/10.1016/j.fct.2015.09.003)  
50 [10.1016/j.fct.2015.09.003](https://doi.org/10.1016/j.fct.2015.09.003).



- 1  
2 Hieshima, K., Imai, T., Opdenakker, G., Van Damme, J., Kusuda, J., Tei, H., Sakaki,  
3 Y., Takatsuki, K., Miura, R., Yoshie, O., Nomiyama, H., 1997. Molecular cloning of a  
4 novel human CC chemokine liver and activation-regulated chemokine (LARC)  
5 expressed in liver. Chemotactic activity for lymphocytes and gene localization on  
6 chromosome 2. *J. Biol. Chem.* 272, 5846–5853. <https://doi.org/10.1074/jbc.272.9.5846>.  
7
- 8 Karlovsky, P., Suman, M., Berthiller, F., Meester, J.D., Eisenbrand, G., Perrin, I.,  
9 Oswald, I.P., Speijers, G., Chiodini, A., Recker, T., Dussort, P., 2016. Impact of food  
10 processing and detoxification treatments on mycotoxin contamination. *Mycotoxin Res.*  
11 32, 179-205. <https://doi.org/10.1007/s12550-016-0257-7>.  
12
- 13 Knutsen, H.K., Alexander, J., Barreg, L., Ceccatelli, S., Cottrill, B., Dinovi, M., et al.,  
14 2017. Risks to human and animal health related to the presence of deoxynivalenol and  
15 its acetylated and modified forms in food and feed. *EFSA J.* 15, 4718. <https://doi.org/10.2903/j.efsa.2017.4718>.  
16
- 17  
18 Kolls, J.K., Khader, S.A., 2010. The role of the Th17 cytokines in primary mucosal  
19 immunity. *Cytok. Growth Factor Rev.* 21, 443–448. <https://doi.org/10.1016/j.cytogfr.2010.11.002>.  
20  
21
- 22 Lessard, M., Savard, C., Deschene, K., Lauzon, K., Pinilla, V.A., Gagnon, C.A.,  
23 Lapointe, J., Guay, F., Chorfi, Y., 2015. Impact of deoxynivalenol (DON) contaminated  
24 feed on intestinal integrity and immune response in swine. *Food Chem. Toxicol.* 80, 7-  
25 16. <https://doi.org/10.1016/j.fct.2015.02.013>.  
26
- 27 Li, X.Z., Zhu, C., de Lange, C.F., Zhou, T., He, J., Yu, H., Gong, J., Young, J.C., 2011.  
28 Efficacy of detoxification of deoxynivalenol-contaminated corn by *Bacillus* sp. LS100  
29 in reducing the adverse effects of the mycotoxin on swine growth performance. *Food*  
30 *Addit. Contam. Part A Chem. Anal. Control Expo. Risk Assess.* 28, 894-901.  
31 <https://doi.org/10.1080/19440049.2011.576402>.  
32
- 33 Li, X., Guo, Y., Zhao, L., Fan, Y., Ji, C., Zhang, J., Ma, Q., 2018. Protective effects of  
34 *Devosia* sp. ANSB714 on growth performance, immunity function, antioxidant capacity  
35 and tissue residues in growing-finishing pigs fed with deoxynivalenol contaminated  
36 diets. *Food Chem. Toxicol.* 121, 246-251. <https://doi.org/10.1016/j.fct.2018.09.007>.  
37
- 38 Livak, K.J., Schmittgen, T.D., 2001. Analysis of relative gene expression data using  
39 real-time quantitative PCR and the 2(-Delta Delta C(T)) Method. *Methods* 25, 402–408.  
40 <https://doi.org/10.1006/meth.2001.1262>.
- 41 Marin, D.E., Taranu, I., Pascale, F., Lionide, A., Burlacu, R., Bailly, J.D., Oswald, I.P.,  
42 2006. Sex-related differences in the immune response of weanling piglets exposed to  
43 low doses of fumonisin extract. *Br. J. Nutr.* 95, 1185-92. <https://doi.org/10.1079/BJN20061773>.  
44
- 45 Maruo, V.M., Bracarense, A.P., Metayer, J.P., Vilarino, M., Oswald, I.P., Pinton, P.,  
46 2018. Ergot Alkaloids at Doses Close to EU Regulatory Limits Induce Alterations of  
47 the Liver and Intestine. *Toxins* 10, E183. <https://doi.org/10.3390/toxins10050183>.

- 1 Mikami, O., Yamamoto, S., Yamanaka, N., Nakajima, Y., 2004. Porcine hepatocyte  
2 apoptosis and reduction of albumin secretion induced by deoxynivalenol. *Toxicol.* 204,  
3 241-249. <https://doi.org/10.1016/j.tox.2004.07.001>.  
4
- 5 Mikami, O., Yamaguchi, H., Murata, H., Nakajima, Y., Miyazaki, S., 2010. Induction  
6 of apoptotic lesions in liver and lymphoid tissues and modulation of cytokine mRNA  
7 expression by acute exposure to deoxynivalenol. *J. Vet. Sci.* 11, 107-113.  
8 <https://doi.org/10.4142/jvs.2010.11.2.107>.  
9
- 10 Payros, D., Alassane-Kpembé, I., Pierron, A., Loiseau, N., Pinton, P., Oswald, I.P.,  
11 2016. Toxicology of deoxynivalenol and its acetylated and modified forms. *Arch.*  
12 *Toxicol.* 90, 2931-2957. <https://doi.org/10.1007/s00204-016-1826-4>.  
13
- 14 Pestka, J.J., 2010. Deoxynivalenol-induced proinflammatory gene expression:  
15 mechanism and pathological sequelae. *Toxins* 2, 1300-1317. <https://doi.org/10.3390/toxins2061300>.  
16  
17
- 18 Pierron, A., Mimoun, S., Murate, L.S., Loiseau, N., Lippi, Y., Bracarense, A.P.F.R.L.,  
19 Schatzmayr, G., He, J.W., Zhou, T., Moll, W.D., Oswald, I., 2016. Microbial  
20 biotransformation of DON: molecular basis for reduced toxicity. *Sci. Rep.* 6, 29105.  
21 <https://doi.org/10.1038/srep29105>.  
22
- 23 Pierron, A., Bracarense, A.P.F.L., Cossalter, A.M., Laffitte, J., Schwartz-Zimmermann,  
24 H.E., Schatzmayr, G., Pinton, P., Moll, W.D., Oswald, I.P., 2018. Deepoxy-  
25 deoxynivalenol retains some immune-modulatory properties of the parent molecule  
26 deoxynivalenol in piglets. *Arch. Toxicol.* 92: 3381-3389. <https://doi.org/10.1007/s00204-018-2293-x>.  
27  
28
- 29 Pinton, P., Accensi, F., Beauchamp, E., Cossalter, A.M., Callu, P., Grosjean, F.,  
30 Oswald, I.P., 2008. Ingestion of deoxynivalenol (DON) contaminated feed alters the pig  
31 vaccinal immune responses. *Toxicol. Letters* 177, 215-222.  
32 <https://doi.org/10.1016/j.toxlet.2008.01.015>.  
33
- 34 Pinton, P., Braicu, C., Nougayrede, J.P., Laffitte, J., Taranu, I., Oswald, I.P., 2010.  
35 Deoxynivalenol impairs porcine intestinal barrier functional and decrease the protein  
36 expression of claudin-4 through a mitogen-activated protein kinase-dependent  
37 mechanism. *J. Nutr.* 140, 1956-1962. <https://doi.org/10.3945/jn.110.123919>.  
38
- 39 Pinton, P., Graziani, F., Pujol, A., Nicoletti, C., Paris, O., Ernouf, P., Di Pasquale, E.,  
40 Perrier, J., Oswald, I.P., Maresca, M., 2015. Deoxynivalenol inhibits the expression. By  
41 goblet cells of intestinal mucins through a PKR and MAP kinase dependent repression  
42 of the resistin-like molecule. *Mol. Nutr. Food Res.* 59, 1076-1087. <https://doi.org/10.1002/mnfr.201500005>.  
43  
44
- 45 Pinton, P., Oswald, I.P., 2014. Effect of deoxynivalenol and other Type B  
46 trichothecenes on the intestine: a review. *Toxins* 6, 1615-1643.  
47 <https://doi.org/10.3390/toxins6051615>.  
48
- 49 Pinton, P., Tsybulskyy, D., Luciola, J., Laffitte, J., Callu, P., Lyazhri, F., Grosjean, F.,  
50 Bracarense, A.P., Kolf-Clauw, M., Oswald, I.P., 2012. Toxicity of deoxynivalenol and

1 its acetylated derivatives on the intestine: differential effects on morphology, barrier  
2 function, tight junction proteins, and mitogen-activated protein kinases. *Toxicol. Sci.*  
3 130, 180-190. <https://doi.org/10.1093/toxsci/kfs239>.

4  
5 Qu, R., Jiang, C., Wu, W., Pang, B., Lei, S., Lian, Z., Shao, D., Jin, M., Shi, J.,  
6 2019. Conversion of DON to 3-epi-DON in vitro and toxicity reduction of DON *in vivo*  
7 by *Lactobacillus rhamnosus*. *Food Funct.* 10, 2785-2796. [https://doi.org/](https://doi.org/10.1039/c9fo00234k)  
8 10.1039/c9fo00234k.

9  
10 SCOOP task 3.2.10. Collection of occurrence data of Fusarium toxins in food and  
11 assessment of dietary intake by the population of EU member states. 2003. Available in  
12 <http://europa.eu.int/comm/food/fs/scoop/task3210.pdf>

13  
14  
15 Silva, E.O., Gerez, J.R., Drape, T.C., Bracarense, A.P.F.R.L., 2014. Phytic acid  
16 decreases deoxynivalenol and fumonisin B1-induced changes on swine jejunal explants.  
17 *Toxicol. Rep.* 1, 284-292. <https://doi.org/10.1016/j.toxrep.2014.05.001>.

18  
19 Soler, L., Oswald, I.P., 2018. The importance of accounting for sex in the search of  
20 proteomic signatures of mycotoxin exposure. *J. Proteomics* 178, 114-122. In review

21  
22 Springler, A., Hessenberger, S., Reisinger, N., Kern, C., Nagl, V., Schatzmayr, G.,  
23 Mayer, E., 2017. Deoxynivalenol and its metabolite deepoxy-deoxynivalenol: multi-  
24 parameter analysis for the evaluation of cytotoxicity and cellular effects. *Mycotoxin*  
25 *Res.* 33, 25-37. <https://doi.org/10.1007/s12550-016-0260-z>.

26  
27 Terciolo, C., Bracarense, A.P., Souto, P.C.M.C., Cossalter, A.M., Dopavogui, L.,  
28 Loiseau, N., Oliveira, C.A.F., Pinton, P., Oswald, I.P., 2019. Fumonisin at Doses  
29 below EU Regulatory Limits Induce Histological Alterations in Piglets. *Toxins* 11,  
30 E548. <https://doi.org/10.3390/toxins11090548>.

31  
32 Van de Walle, J., Sergent, T., Piront, N., Toussaint, O., Schneider, Y.J., Larondelle, Y.,  
33 2010. Deoxynivalenol affects in vitro intestinal epithelial cell barrier integrity through  
34 inhibition of protein synthesis. *Toxicol. Appl. Pharmacol.* 245, 291-298.  
35 <https://doi.org/10.1016/j.taap.2010.03.012>.

36  
37 Verdile, N., Mirmahmoudi, R., Brevini, T.A.L, Gandolfi, F., 2019. Evolution of pig  
38 intestinal stem cells from birth to weaning. *Animal* 13, 2830-2839.  
39 <https://doi.org/10.1017/S1751731119001319>.

40  
41  
42  
43

## 1 **Figure legends**

2 Figure 1 – Comparative effects of DON, DOM-1 and 3-epi-DON on immunoglobulin  
3 levels. Different letters mean a significant difference ( $P \leq 0.05$ ). □ control, ■ DON  
4 diet, ■ DOM-1 diet and □□ 3-epi-DON diet.

5  
6 Figure 2 – Small intestine of piglets receiving different diets. □ control, ■ DON  
7 diet,  
8 ■ DOM-1 diet and □□ 3-epi-DON diet. A. Intestinal lesion score. Different letters  
9 mean a significant difference ( $P \leq 0.05$ ). B. Control group showing villi with normal  
10 height. C. DON group showing diffuse edema of the lamina propria and villi atrophy.  
11 D. DOM-1 group showing mild lymphatic dilatation in the lamina propria. E. 3-epi-  
12 DON group showing a villi normal morphology. B to E – Jejunum, Hematoxylin Eosin  
13 staining, bar 100  $\mu\text{m}$ . A.U. – arbitrary units. PP – Peyer's patches.

14  
15 Figure 3 - Comparative effect of DON, DOM-1 and 3-epi-DON on the number of goblet  
16 cells in the jejunum and ileum of piglets receiving different diets. Different letters mean  
17 a significant difference ( $P \leq 0.05$ ).

18  
19 Figure 4 – Liver of piglets receiving different diets. □ control, ■ DON diet, ■ DOM-  
20 1 diet and □□ 3-epi-DON diet. A. Liver lesion score. Different letters mean a  
21 significant difference ( $P \leq 0.05$ ). B. Control group showing normal hepatocytes. C. DON  
22 group showing diffuse hepatocyte vacuolation. D. DOM-1 group showing mild  
23 trabecular disorganization. E. 3-epi-DON group showing normal morphology of  
24 hepatocytes. B to E – Liver, Hematoxylin Eosin staining, bar 20  $\mu\text{m}$ . A.U. – arbitrary  
25 units.

26  
27 Figure 5 – Lymph nodes of piglets receiving different diets. □ control, ■ DON diet,  
28 ■ DOM-1 diet and □□ 3-epi-DON diet. A. Spleen and lymph nodes lesion score.  
29 Different letters mean a significant difference ( $P \leq 0.05$ ). B. Control group showing  
30 lymphoid follicles containing a regular number of lymphoid cells C. DON group  
31 showing depletion of lymphoid follicles (arrows). D. DOM-1 group showing  
32 lymphocyte proliferation (mitosis figures, arrows). E. 3-epi-DON group showing  
33 lymphoid cell hyperplasia in paracortical region . B to E – Lymph nodes, Hematoxylin  
34 Eosin staining, B,C, E bar 50  $\mu\text{m}$ , D 20  $\mu\text{m}$ . A.U. – arbitrary units.

## 35 36 **Table legends**

37 Table 1- Nucleotide sequences of primers for real-time PCR.

38  
39 Table 2. Effects of DON, DOM-1 and 3-epi-DON on hematological parameters.

40 Results are expressed as mean  $\pm$  SEM for six animals. Means in rows followed by the same  
41 letters do not differ significantly by Tukey's test ( $P \leq 0.05$ ).

1

2 Table 3 – Expression of genes in the jejunum and jejunum with Peyers’s patches of  
3 piglets submitted to different treatments.

4 Results are expressed as mean  $\pm$  SEM for six animals. Means in rows followed by different  
5 letters indicate statistical significance by Duncan’s test ( $P \leq 0.05$ ).

6

Table 1 – Nucleotide sequences of primers for real-time PCR.

Gene symbol	Gene name	Primer sequence	References
CycloA	Cyclophilin A	F: CCCACCGTCTTTCGACAT R: TCTGCTGTCTTTGGAACCTTGTCT	NM_214353 Pinton et al 2015
IL-1 $\alpha$	Interleukin 1 alpha	F: TCAGCCGCCCATCCA R: AGCCCCGGTGCCATGT	NM_214029,1 Cano et al. 2013
IL-1 $\beta$	Interleukin 1 beta	F: ATGCTGAAGGCTCTCCACCTC R: TTGTTGCTATCATCTCCTTGAC	NM_214055 Von der Hardt et al.2004
IL-6	Interleukin 6	F: TTCACCTCTCCGGACAAAAGT R: TCTGCCAGTACCTCCTTGCTGT	NM_214399 Grenier et al. 2011
IL-8	Interleukin 8	F: GCTCTCTGTGAGGCTGCAGTTC R: AAGGTGTGGAATGCGTATTTATGC	NM_213867 Cano et al. 2013
IL-10	Interleukin 10	F: GGCCAGTGAAGAGTTCTTTTC R: CAACAAGTCGCCATCTGGT	NM_214041 Cano et al. 2013
IL-12p40	Interleukin 12 subunit p40	F: GGTTCAGACCCGACGAAGTCT R: CATATGGCCACAATGGGAGATG	NM_214013 Cano et al. 2013
IFN- $\gamma$	Interferon gamma	F: TGGTAGCTCTGGGAACTGAATG R: GGCTTTGCGCTGGATCTG	NM_213948 Cano et al. 2013
TNF- $\alpha$	Tumor necrosis factor alpha	F: ACTGCACTTCGAGTTATCGG R: GCGACGGGCTTATCTGA	NM_214022 Cano et al. 2013
CCL20	Chemokine (C-C motif) ligand 20	F: GCTCCTGGCTGCTTTGATGTC R: CATTGGCGAGCTGCTGTGTG	NM_001024589 Cano et al. 2013
CX3CL1	Chemokine (C-X3-C motif) ligand 1	F: GCAGCTCCTAGTCCATTAC R: CACCAT TCTGACCCAGAAG	EST CK464144 Meurens et al., 2009
TGF- $\beta$	Transforming growth factor beta	F: GAAGCGCATCGAGGCCATTC R: GGCTCCGGTTCGACACTTTC	NM_214015 Meurens et al., 2009
IL-17A	Interleukin 17A	F: CCAGACGGCCCTCAGATTAC R: CACTTGGCCTCCAGATCAC	AB102693 Cano et al. 2013
E-cadherin	Epithelial cadherin (Cadherin 1)	F: ACCACCGCCATCAGGACTC R: TGGGAGCTGGGAAACGTG	NM_001163060.1 Present study
Occludin	Occludin	F: AGCTGGAGGAAGACTGGATCAG R: TGCAGGCCACTGTCAAATT	U79554 Yamagata et al., 2004

Table 2. Effects of DON, DOM-1 and 3-epi-DON on hematological parameters.

Hematological parameters	Animal treatment							
	Control		DON		DOM-1		3-epi-DON	
	Mean	SEM	Mean	SEM	Mean	SEM	Mean	SEM
White blood cells (1000/ $\mu$ L)	29.10	1.0 <sup>a</sup>	27.80	2.4 <sup>a</sup>	28.60	3.2 <sup>a</sup>	27.30	2.4 <sup>a</sup>
Lymphocytes (1000/ $\mu$ L)	21.03	0.8 <sup>a</sup>	19.30	2.2 <sup>a</sup>	18.53	1.8 <sup>a</sup>	18.93	2.8 <sup>a</sup>
Neutrophils (1000/ $\mu$ L)	5.64	0.5 <sup>a</sup>	6.76	1.4 <sup>a</sup>	5.95	1.7 <sup>a</sup>	6.35	0.7 <sup>a</sup>
Red blood cells (1000/ $\mu$ L)	6.69	0.3 <sup>a</sup>	6.81	0.2 <sup>a</sup>	7.01	0.3 <sup>a</sup>	7.15	0.2 <sup>a</sup>
Mean corpuscular volume (fL)	55.17	1.3 <sup>a</sup>	55.83	1.4 <sup>a</sup>	53.00	1.7 <sup>a</sup>	55.33	1.4 <sup>a</sup>
Hematocrit (%)	36.58	1.3 <sup>a</sup>	37.90	0.9 <sup>a</sup>	37.22	2.1 <sup>a</sup>	39.58	1.3 <sup>a</sup>
Hemoglobin (g/dL)	10.75	0.4 <sup>a</sup>	11.11	0.3 <sup>a</sup>	10.81	0.7 <sup>a</sup>	11.38	0.4 <sup>a</sup>
Mean corpuscular hemoglobin (pg)	16.10	0.3 <sup>a</sup>	16.35	0.3 <sup>a</sup>	15.38	0.7 <sup>a</sup>	15.87	0.4 <sup>a</sup>
Mean corpuscular hemoglobin concentration (%)	29.42	0.4 <sup>a</sup>	29.32	0.4 <sup>a</sup>	28.95	0.4 <sup>a</sup>	28.70	0.3 <sup>a</sup>

Results are expressed as mean  $\pm$  SEM for six animals. Means in rows followed by the same letters do not differ significantly by Tukey's test ( $P \leq 0.05$ ).

Table 3 – Expression of genes of the jejunum and jejunum with Peyer's patches of piglets submitted to different treatments.

Genes	Jejunum				Jejunum PP			
	control	DON	DOM-1	3-epi-DON	control	DON	DOM-1	3-epi-DON
<b>IL-1<math>\alpha</math></b>	1.00±0.48 <sup>b</sup>	1.71±0.31 <sup>ab</sup>	2.11±0.48 <sup>a</sup>	1.03±0.16 <sup>b</sup>	1.00±0.18 <sup>a</sup>	1.40±0.18 <sup>a</sup>	1.34±0.23 <sup>a</sup>	1.32±0.57 <sup>a</sup>
<b>IL-1<math>\beta</math></b>	1.00±0.29 <sup>a</sup>	1.37±0.34 <sup>a</sup>	1.27±0.24 <sup>a</sup>	1.29±0.25 <sup>a</sup>	1.00±0.15 <sup>a</sup>	1.41±0.19 <sup>a</sup>	1.46±0.18 <sup>a</sup>	1.40±0.59 <sup>a</sup>
<b>IL-6</b>	1.00±0.27 <sup>ab</sup>	1.41±0.75 <sup>ab</sup>	1.43±0.30 <sup>a</sup>	0.57±0.12 <sup>b</sup>	1.00±0.19 <sup>a</sup>	1.48±0.19 <sup>a</sup>	1.04±0.10 <sup>a</sup>	1.58±0.50 <sup>a</sup>
<b>IL-8</b>	1.00±0.15 <sup>b</sup>	1.78±0.37 <sup>a</sup>	1.28±0.30 <sup>ab</sup>	1.02±0.14 <sup>ab</sup>	1.00±0.05 <sup>a</sup>	1.28±0.12 <sup>a</sup>	1.29±0.33 <sup>a</sup>	1.11±0.42 <sup>a</sup>
<b>IL-10</b>	1.00±0.22 <sup>a</sup>	1.51±0.36 <sup>a</sup>	1.45±0.26 <sup>a</sup>	1.42±0.42 <sup>b</sup>	1.00±0.13 <sup>b</sup>	1.82±0.30 <sup>a</sup>	1.47±0.24 <sup>ab</sup>	1.18±0.37 <sup>ab</sup>
<b>IL-12p40</b>	1.00±0.26 <sup>b</sup>	2.05±0.34 <sup>a</sup>	1.52±0.24 <sup>ab</sup>	0.90±0.32 <sup>b</sup>	1.00±0.29 <sup>b</sup>	2.35±0.72 <sup>a</sup>	1.41±0.26 <sup>ab</sup>	1.25±0.40 <sup>ab</sup>
<b>IFN-<math>\gamma</math></b>	1.00±0.25 <sup>a</sup>	1.30±0.33 <sup>a</sup>	1.37±0.33 <sup>a</sup>	0.71±0.39 <sup>a</sup>	1.00±0.27 <sup>a</sup>	0.97±0.18 <sup>a</sup>	1.11±0.14 <sup>a</sup>	0.93±0.25 <sup>a</sup>
<b>TNF-<math>\alpha</math></b>	1.00±0.19 <sup>b</sup>	1.91±0.51 <sup>a</sup>	1.73±0.43 <sup>ab</sup>	1.13±0.20 <sup>ab</sup>	1.00±0.24 <sup>b</sup>	2.50±0.41 <sup>a</sup>	1.27±0.33 <sup>ab</sup>	1.86±0.65 <sup>ab</sup>
<b>CCL20</b>	1.00±0.34 <sup>b</sup>	4.68±2.12 <sup>a</sup>	2.63±0.67 <sup>ab</sup>	1.50±0.53 <sup>ab</sup>	1.00±0.23 <sup>b</sup>	5.05±1.49 <sup>a</sup>	2.09±0.73 <sup>b</sup>	1.24±0.34 <sup>b</sup>
<b>CX3CL1</b>	1.00±0.08 <sup>b</sup>	1.73±0.30 <sup>ab</sup>	1.89±0.29 <sup>a</sup>	1.44±0.33 <sup>ab</sup>	1.00±0.55 <sup>a</sup>	1.35±0.26 <sup>a</sup>	1.24±0.09 <sup>a</sup>	1.47±0.54 <sup>a</sup>
<b>TGF-<math>\beta</math></b>	1.00±0.16 <sup>a</sup>	1.54±0.25 <sup>a</sup>	1.65±0.32 <sup>a</sup>	1.22±0.18 <sup>a</sup>	1.00±0.17 <sup>a</sup>	1.60±0.26 <sup>a</sup>	1.33±0.20 <sup>a</sup>	2.15±0.80 <sup>a</sup>
<b>IL-17A</b>	1.00±0.18 <sup>a</sup>	4.49±1.68 <sup>b</sup>	0.96±0.26 <sup>a</sup>	0.87±0.23 <sup>a</sup>	1.00±0.27 <sup>b</sup>	1.90±0.76 <sup>ab</sup>	2.53±0.33 <sup>a</sup>	1.65±0.99 <sup>a</sup>



---

<b>E-cadherin</b>	1.00±0.11 <sup>b</sup>	1.80±0.48 <sup>a</sup>	1.69±0.50 <sup>ab</sup>	1.15±0.16 <sup>ab</sup>	1.00±0.18 <sup>b</sup>	2.40±0.23 <sup>a</sup>	1.29±0.31 <sup>ab</sup>	1.43±0.55 <sup>ab</sup>
<b>Occludin</b>	1.00±0.14 <sup>a</sup>	1.30±0.22 <sup>a</sup>	1.71±0.56 <sup>a</sup>	1.38±0.22 <sup>a</sup>	1.00±0.24 <sup>b</sup>	2.38±0.31 <sup>a</sup>	1.32±0.35 <sup>ab</sup>	1.63±0.71 <sup>ab</sup>

---

Results are expressed as mean ± SEM for six animals. Means in rows followed by different letters indicate statistical significance by Duncan's test ( $P \leq 0.05$ ).

Figure 1

[Click here to download high resolution image](#)

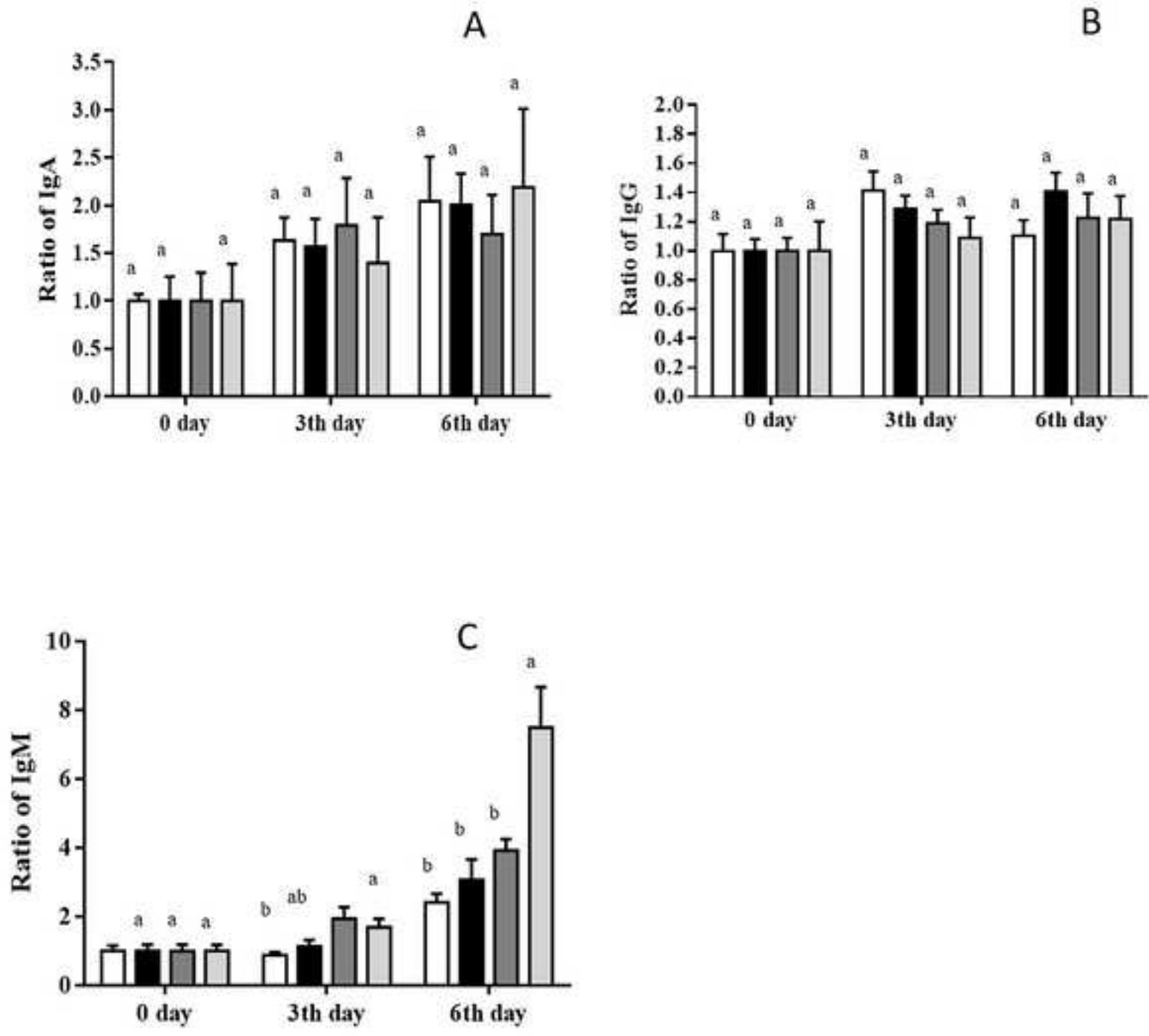


Figure 2

[Click here to download high resolution image](#)

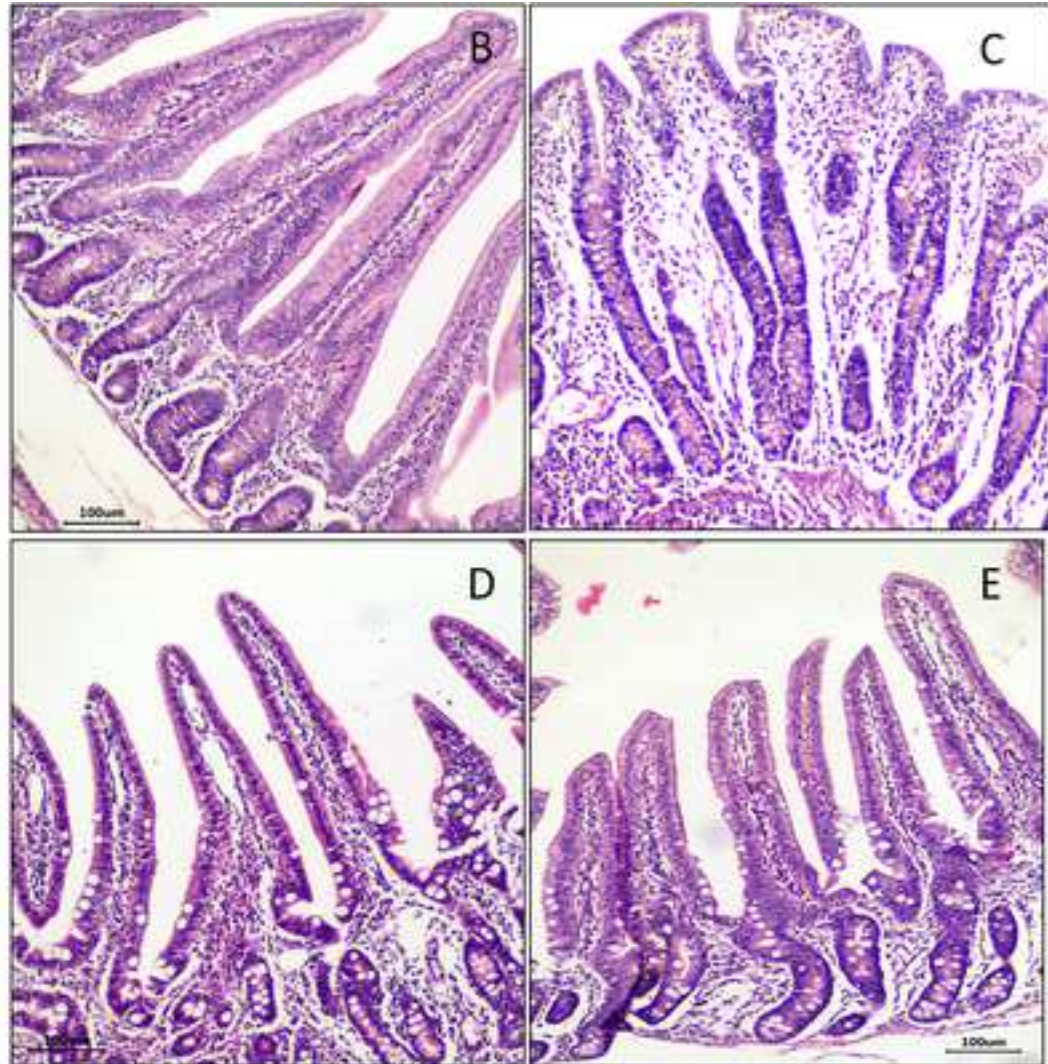
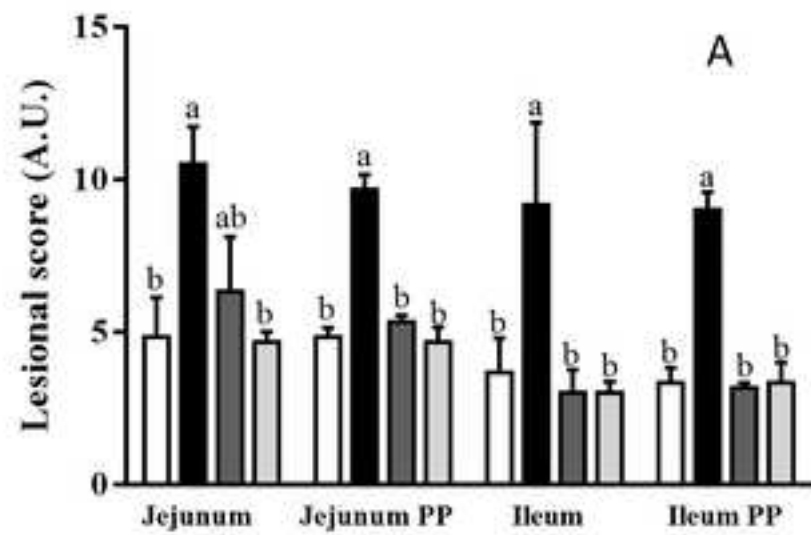


Figure 3  
[Click here to download high resolution image](#)

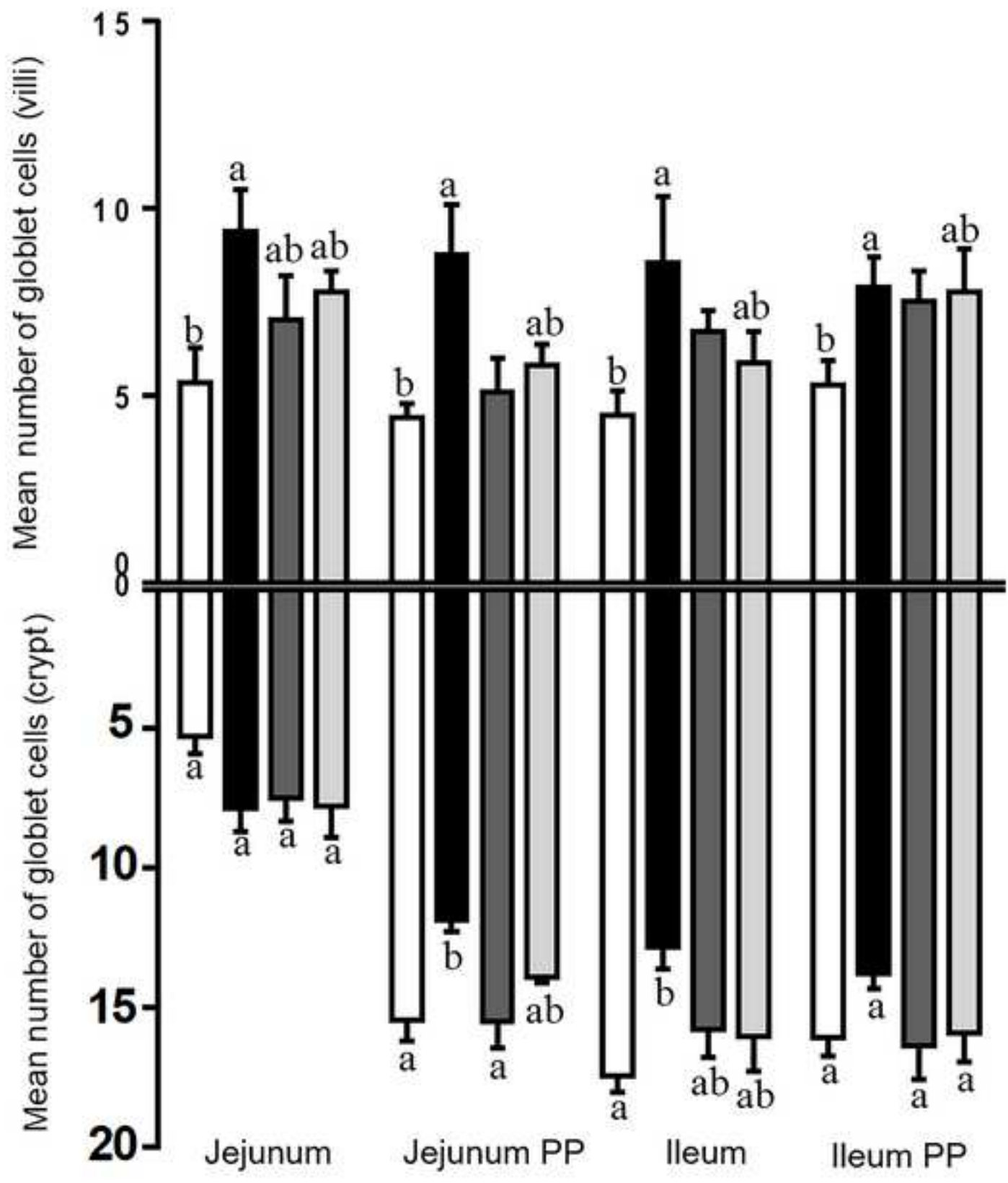




Figure 4

[Click here to download high resolution image](#)

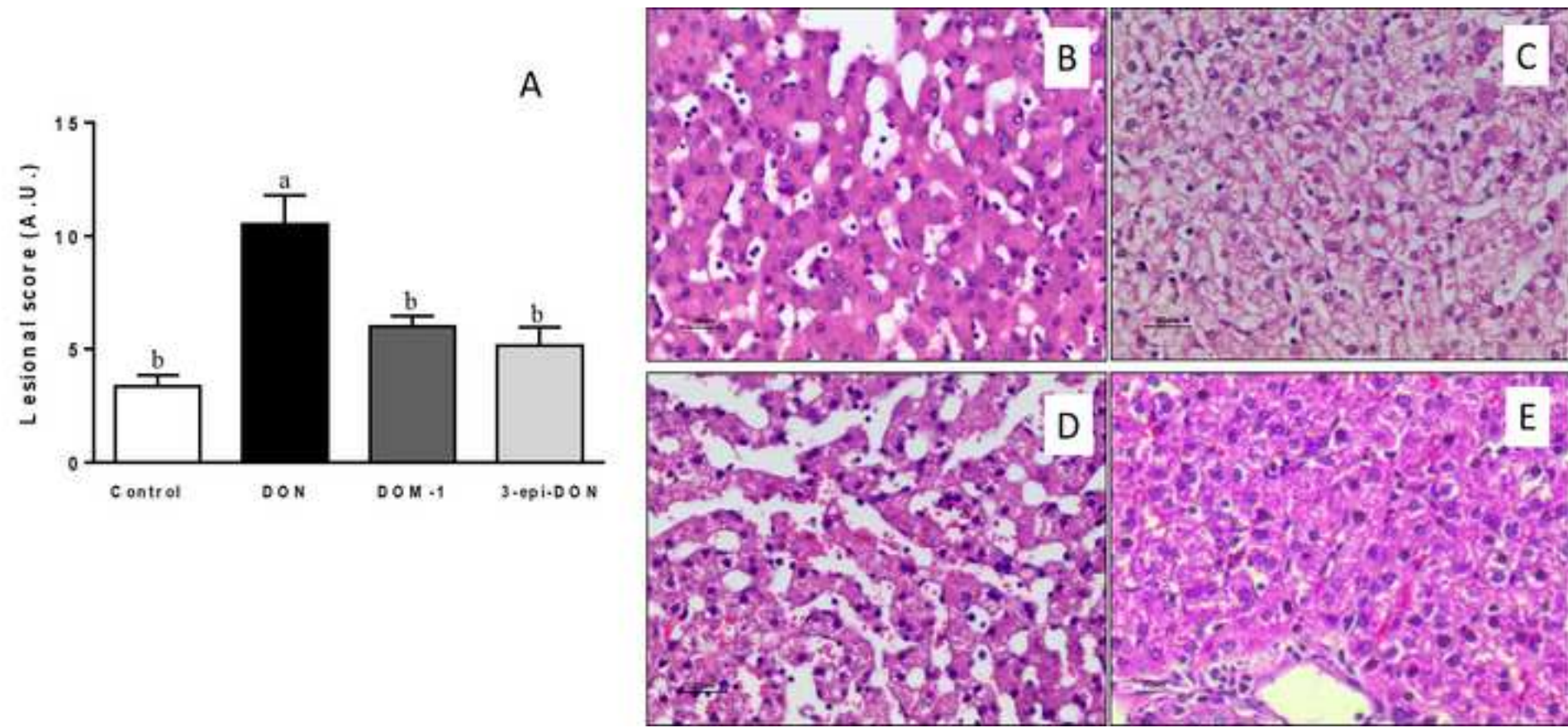


Figure 5

[Click here to download high resolution image](#)

