



**HAL**  
open science

# Increased Expression of Caspase-1 and Interleukin-18 in Peeling Skin Disease, and a Novel Mutation of Corneodesmosin

Frederic Valentin, Vinzenz Oji, Ingrid Hausser, Eva Liebau, Tatjana Tarinski, Dieter Metze, Dirk Breitzkreutz, Heiko Traupe, Nathalie Jonca, Patrick Terheyden

► **To cite this version:**

Frederic Valentin, Vinzenz Oji, Ingrid Hausser, Eva Liebau, Tatjana Tarinski, et al.. Increased Expression of Caspase-1 and Interleukin-18 in Peeling Skin Disease, and a Novel Mutation of Corneodesmosin. *Acta Dermato-Venereologica*, 2015, 95 (8), pp.1019-1021. 10.2340/00015555-2142 . hal-03263243

**HAL Id: hal-03263243**

**<https://ut3-toulouseinp.hal.science/hal-03263243>**

Submitted on 1 Jul 2021

**HAL** is a multi-disciplinary open access archive for the deposit and dissemination of scientific research documents, whether they are published or not. The documents may come from teaching and research institutions in France or abroad, or from public or private research centers.

L'archive ouverte pluridisciplinaire **HAL**, est destinée au dépôt et à la diffusion de documents scientifiques de niveau recherche, publiés ou non, émanant des établissements d'enseignement et de recherche français ou étrangers, des laboratoires publics ou privés.

## SHORT COMMUNICATION

## Increased Expression of Caspase-1 and Interleukin-18 in Peeling Skin Disease, and a Novel Mutation of Corneodesmosin

Frederic Valentin<sup>1#</sup>, Vinzenz Oji<sup>1#</sup>, Ingrid Hausser<sup>2</sup>, Eva Liebau<sup>3</sup>, Tatjana Tarinski<sup>1</sup>, Dieter Metzke<sup>1</sup>, Dirk Breitkreutz<sup>4</sup>, Heiko Traupe<sup>1</sup>, Nathalie Jonca<sup>5</sup> and Patrick Terheyden<sup>6</sup><sup>1</sup>Department of Dermatology, Von-Esmarch-Str. 58, DE-48149 Münster, <sup>2</sup>Institute of Pathology, University Hospital Heidelberg, Heidelberg, <sup>3</sup>Institute of Animal Physiology – Department of Molecular Physiology, University of Münster, Münster, <sup>4</sup>Department of Genetics of Skin Carcinogenesis, German Cancer Research Center, Heidelberg, Germany, <sup>5</sup>UMR5165/U1056 CNRS-INSERM-CNRS-Université Toulouse III, Différenciation Epidermique et Autoimmunité Rhumatoïde, Hôpital Purpan, Toulouse, France, and <sup>6</sup>Department of Dermatology, University Hospital Schleswig-Holstein, Lübeck, Germany. E-mail: Frederic.Valentin@ukmuenster.de<sup>#</sup>These authors contributed equally to this paper and should be considered as first authors.

Accepted May 11, 2015; Epub ahead of print May 27, 2015

Peeling skin syndromes (PSS) refer to a heterogeneous group of generalized and/or palmoplantar disorders. Inflammatory peeling skin disease (PSD) refers to PSS type B [MIM 270300] (1) and is an ichthyosiform erythroderma characterized by recurrent patchy peeling of the skin with accompanying pruritus. The disease persists throughout life, is accompanied by significant atopic manifestations, and can be reminiscent of Netherton syndrome (NTS) (1, 2). PSD is due to autosomal recessive loss-of-function mutations in the *CDSN* gene encoding corneodesmosin (CDSN) (3), as independently confirmed by several groups (4–7). Moreover, large deletions encompassing the *CDSN* gene have been identified as the molecular cause (8, 9).

CDSN is a basic phosphoprotein expressed in cornified epithelia and hair follicles (10). It is localized in the lamellar granules of the stratum granulosum and found in the corneodesmosomes of the stratum corneum. The protein has a high level of serine and glycine, with specific structure motifs rich in these amino acids at the N-terminal (aa 60–171) and C-terminal end (aa 375–450), designated as glycine loops. These structure motifs are suggested to mediate cell-cell cohesion. Progressive proteolytic degradation of CDSN by serine proteases (kallikrein 5 and 7) plays a key role in desquamation (11). Hence, PSD represents an impressive clinical example for the primary loss of function of CDSN.

This study investigated a new patient with a novel mutation of the *CDSN* gene and performed expression analysis to reveal information about the inflammatory component of the disorder.

METHODS AND RESULTS (for full details see Appendix S1<sup>1</sup>)

The male patient had been treated for atopic dermatitis up to the age of 10 years until a clinical and histological diagnosis of PSD was first suggested. His parents were non-consanguine and healthy. Since the third week of life the patient suffered from

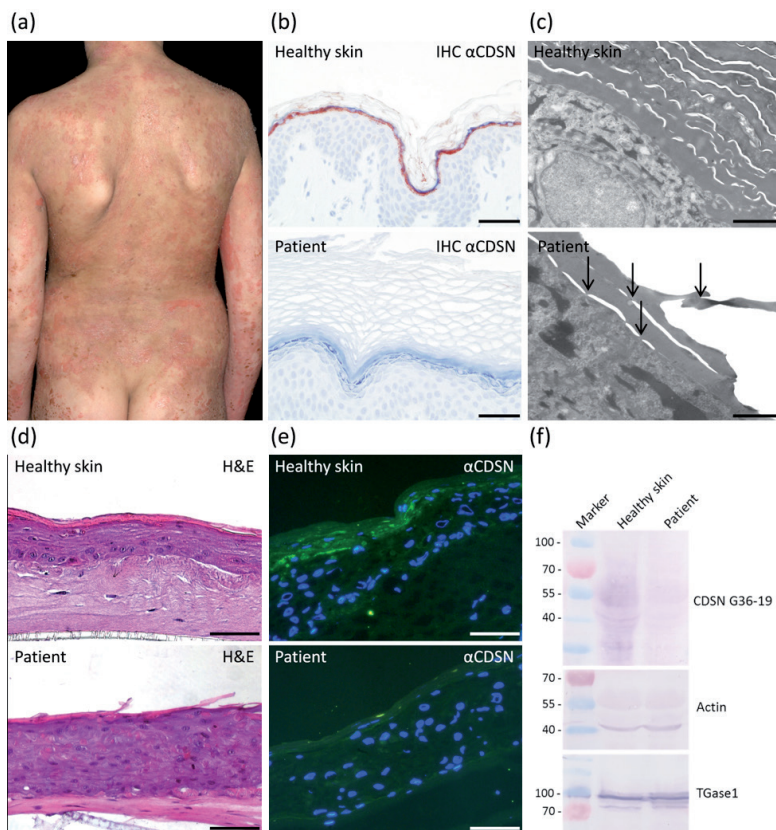
peeling, scaling and eczema of the entire skin (Fig. 1a). The patient's history showed sensitization and clinically relevant allergic reactions through contact with fish, peanut, house-dust mites or grass pollen. Moreover, he had palmoplantar hyperhidrosis. Routine laboratory parameters were normal, except for a highly elevated IgE level (3,204.0 kU/l, normal value <26.3). Treatment was based on lipophilic ointment, antiseptics and antihistamines.

Direct sequencing of the *CDSN* gene revealed the heterozygous mutation c.175A>T (p.Lys59\*) (3) and the novel heterozygous mutation c.1031delC, which predicts a frameshift with premature stop codon (p.Ile345Serfs\*121) (method see (3)). The study was approved by the institutional review board of the University Hospital of Münster (2013-573-f-S). Skin biopsies of the affected patient analysed with the CDSN specific antibody G36-19 (10) revealed an absence of CDSN protein expression (Fig. 1b). Ultrastructural examination revealed an acanthotic epidermis, covered by a hyperkeratotic, loosely packed horny layer, exfoliating in variable levels, mostly after few layers of scales, but only rarely immediately after the last living cell layer. There was a continuous granular layer with normal amounts of keratohyalin granules. Corneodesmosomes were present in variable numbers, while the quality could not be evaluated (Fig. 1c). The subepidermal region showed a diffuse lymphocytic infiltrate with perivascular distribution including some eosinophilic granulocytes (not shown).

To generate three-dimensional (3D) skin equivalents, primary keratinocytes and fibroblasts were taken. After 24 h, skin models were raised to the air-liquid interface and grown for 9 days (methods adapted from (3)). Similar to the patient's biopsy 3D skin equivalents revealed mild acanthosis and signs of increased desquamation. Moreover, a higher number of dyskeratosis can be observed in skin equivalents of PSD (Fig. 1d). In contrast to healthy skin equivalents immunofluorescence analysis of skin equivalents of the patient showed a loss of CDSN expression (Fig. 1e). This lack of CDSN was further confirmed by Western blot analysis (Fig. 1f).

Quantitative real-time PCR (qRT-PCR) with keratinocytes obtained from the patient was performed with an iCycler iQ<sup>TM</sup> Real-Time PCR Detection System (BioRad) using gene-specific primers. Keratinocytes of 4 different healthy persons served as controls. Analysis revealed a decreased expression level of CDSN mRNA (fold change (FC) 2-log –2.49). In addition, the expression levels of caspase 1 (CASP1), an inflammatory caspase, and interleukin 18 (IL18), a proinflammatory cytokine, were analysed. For both, increased expression levels (CASP1 (FC 2-log 1.31) and IL18 (FC 2-log 1.65)) were detected. Their expression levels were compared with that of keratin 1, which did not show a significant difference in expression (FC 2-log –0.81) (Fig. S1<sup>1</sup>).

<sup>1</sup><http://www.medicaljournals.se/acta/content/?doi=10.2340/00015555-2142>



**Fig. 1.** Clinical presentation, immunohistochemistry, ultrastructure, three-dimensional (3D) skin equivalents and corneodesmosin (CDSN) protein expression. (a) Clinical presentation. (b) Immunohistochemistry revealed absence of CDSN in the skin of the patient. (c) Ultrastructure indicates an exfoliating horny layer with corneodesmosomes as punctual contact between scales (*arrows*). (d) Similar to the patient's biopsy 3D skin equivalents revealed mild acanthosis and signs of increased desquamation (haematoxylin and eosin (H&E) staining). (e) Immunofluorescence of corneodesmosin (*green*) (DAPI nuclear staining blue) and (d) Western blot analysis of 3D skin equivalents confirmed the immunohistological results of an absent CDSN protein expression. (Scale bars: 50  $\mu$ m (b, d, e), 1000 nm (c)).

## DISCUSSION

Loss of corneodesmosin as a molecular cause of PSD was identified in 2010 by Oji et al. (3). Since then 6 different *CDSN* mutations, including large deletions of the *CDSN* locus on chromosome 6p21.3, have been published for PSD (4–9). The novel loss of function mutation c.1031delC investigated in this study is located directly before the C-terminal glycine loop of CDSN. The mutation predicts a protein with a long nonsense sequence (p.Ile345Sers\*121) (Fig. S2<sup>1</sup>). Quantitative RT-PCR experiments with primary keratinocytes of the patient showed decreased expression of CDSN mRNA (Fig. S1<sup>1</sup>), suggesting nonsense-mediated mRNA decay as a possible reason. This is in contrast to the previously described stop codon mutation p.Gly142\* residing within the first glycine loop, which showed an elevated (2-fold more) expression level of CDSN mRNA and a residual presence of the truncated protein (7).

Our immunohistological findings in skin biopsies and 3D skin equivalents revealed absent protein expression

of CDSN, as confirmed by Western blot analysis (Fig. 1). The ultrastructural findings of this study confirm the pathological impact of CDSN deficiency on corneodesmosomal adherens, as shown previously (3, 9).

PSD and NTS, as well as the recently described SAM (severe dermatitis, multiple allergies and metabolic wasting) syndrome (12) share some characteristic clinical features, i. e. patients with these diseases often have pruritus and atopic manifestations (1, 2). Caspase-1 (CASP1) is activated by the inflammasome, a multiprotein complex, and promotes the secretion and processing of the proinflammatory cytokines like IL1 $\beta$  and IL18 (13). Dysregulation of epidermal CASP1 activity and elevated serum levels of IL18 have been observed in NTS (14); elevated IL18 levels have been shown in atopic dermatitis (15). To investigate whether the balance of CASP1 and IL18 is altered in PSD, we studied their relative expression levels. Interestingly, both CASP1 and IL18 expression levels were found to be up-regulated in the keratinocytes of the patient. These molecular findings correspond well with the clinical symptoms of PSD. Hence, this study supports the idea that peeling skin disease represents a novel monogenetic skin disease model for inflammatory and atopic skin diseases in general.

## ACKNOWLEDGEMENTS

The authors would like to thank the patient for his cooperation. The expert clinical assistance of Christa Post, Andrea Wissel and Kira Süßmuth is gratefully acknowledged.

**Funding resources.** This work was supported by the Selbsthilfe Ichthyose e. V. ([www.ichthyose.de](http://www.ichthyose.de)) and the Medical Faculty (OJ111409). Use of EM900 was courtesy of the Electron Microscopy Core Facility (EMCF), University Heidelberg.

## REFERENCES

1. Traupe H. Peeling-skin syndrome: clinical and morphological evidence for two types. In: Traupe H, editor. The ichthyoses: a guide to clinical diagnosis, genetic counseling, and therapy. Berlin: Springer; 1989, p. 207–210.
2. Hovnanian A. Netherton syndrome: skin inflammation and allergy by loss of protease inhibition. *Cell Tissue Res* 2013; 351: 289–300.
3. Oji V, Eckl KM, Aufenvenne K, Natebus M, Tarinski T, Ackermann K, et al. Loss of corneodesmosin leads to severe skin barrier defect, pruritus, and atopy: unraveling the peeling skin disease. *Am J Hum Genet* 2010; 87: 274–281.
4. Israeli S, Zamir H, Sarig O, Bergman R, Sprecher E. Inflammatory peeling skin syndrome caused by a mutation in *CDSN* encoding corneodesmosin. *J Invest Dermatol*

- 2011; 131: 779–781.
5. Mazereeuw-Hautier J, Leclerc EA, Simon M, Serre G, Jonca N. A novel mutation in CDSN causes peeling skin disease in a patient from Morocco. *Br J Dermatol* 2011; 165: 1152–1155.
  6. Telem DF, Israeli S, Sarig O, Sprecher E. Inflammatory peeling skin syndrome caused a novel mutation in CDSN. *Arch Dermatol Res* 2012; 304: 251–255.
  7. Mallet A, Kypriotou M, George K, Leclerc E, Rivero D, Mazereeuw-Hautier J, et al. Identification of the first non-sense CDSN mutation with expression of a truncated protein causing peeling skin syndrome type B. *Br J Dermatol* 2013; 169: 1322–1325.
  8. Wada T, Matsuda Y, Muraoka M, Toma T, Takehara K, Fujimoto M, et al. Alu-mediated large deletion of the CDSN gene as a cause of peeling skin disease. *Clin Genet* 2014; 86: 383–386.
  9. Ishida-Yamamoto A, Furio L, Igawa S, Honma M, Tron E, Malan V, et al. Inflammatory peeling skin syndrome caused by homozygous genomic deletion in the PSORS1 region encompassing the CDSN gene. *Exp Dermatol* 2014; 23: 60–63.
  10. Serre G, Mils V, Haftek M, Vincent C, Croute F, Reano A, et al. Identification of late differentiation antigens of human cornified epithelia, expressed in re-organized desmosomes and bound to cross-linked envelope. *J Invest Dermatol* 1991; 97: 1061–1072.
  11. Jonca N, Leclerc EA, Caubet C, Simon M, Guerrin M, Serre G. Corneodesmosomes and corneodesmosin: from the stratum corneum cohesion to the pathophysiology of genodermatoses. *Eur J Dermatol* 2011; 21 Suppl 2: 35–42.
  12. Samuelov L, Sarig O, Harmon RM, Rapaport D, Ishida-Yamamoto A, Isakov O, et al. Desmoglein 1 deficiency results in severe dermatitis, multiple allergies and metabolic wasting. *Nat Genet* 2013; 45: 1244–1248.
  13. Franchi L, Eigenbrod T, Munoz-Planillo R, Nunez G. The inflammasome: a caspase-1-activation platform that regulates immune responses and disease pathogenesis. *Nat Immunol* 2009; 10: 241–247.
  14. Hosomi N, Fukai K, Nakanishi T, Funaki S, Ishii M. Caspase-1 activity of stratum corneum and serum interleukin-18 level are increased in patients with Netherton syndrome. *Br J Dermatol* 2008; 159: 744–746.
  15. Kou K, Aihara M, Matsunaga T, Chen H, Taguri M, Morita S, et al. Association of serum interleukin-18 and other biomarkers with disease severity in adults with atopic dermatitis. *Arch Dermatol Res* 2012; 304: 305–312.